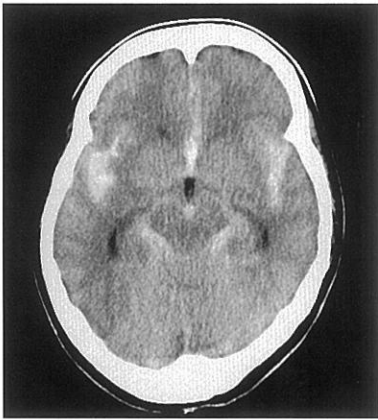

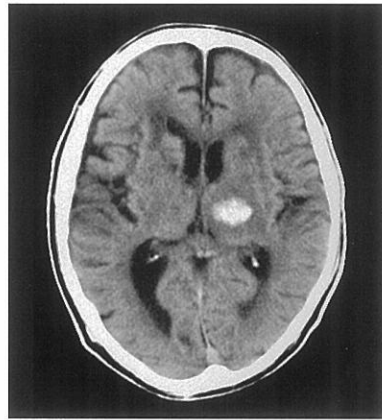
41

○ 午 前

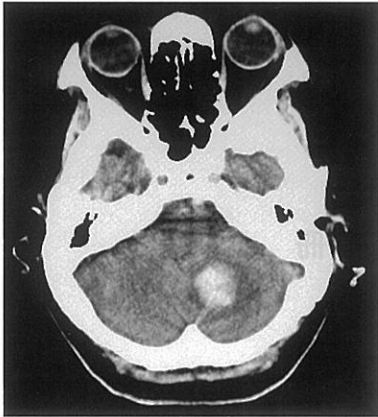別 冊



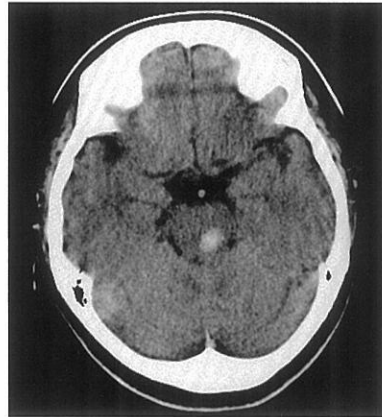
1. くも膜下出血



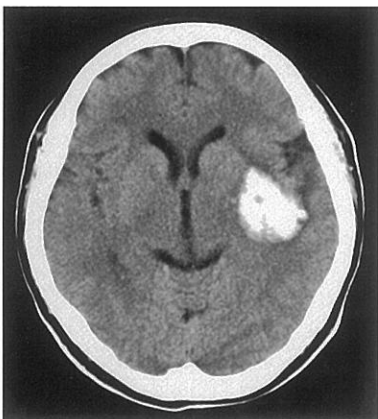
2. 尾状核出血



3. 小脳出血



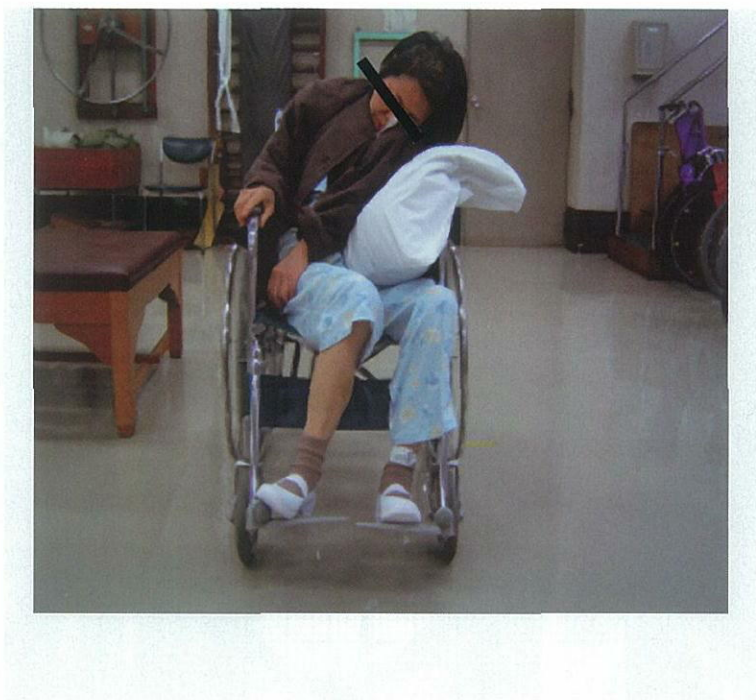4. 脳幹出血



5. 被殻出血


別冊 No. 2 写真

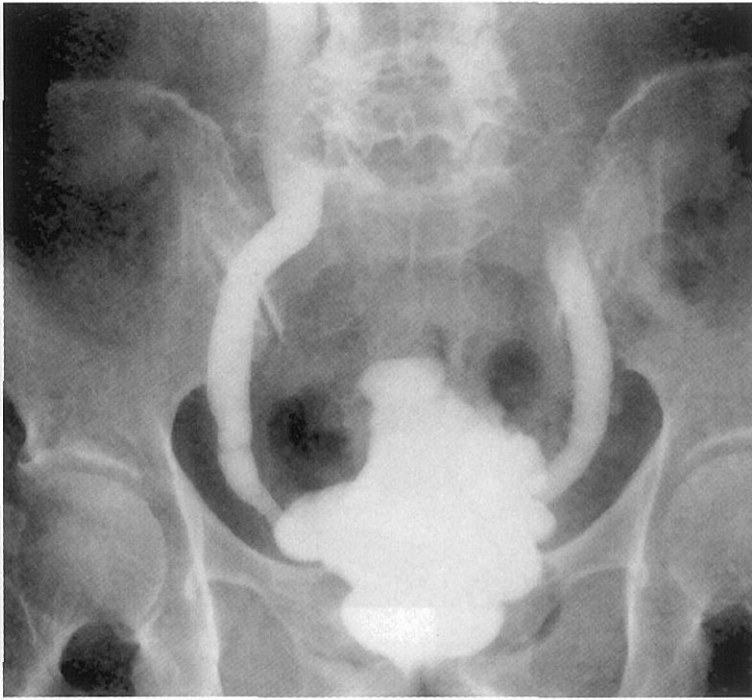
(O 問題11)

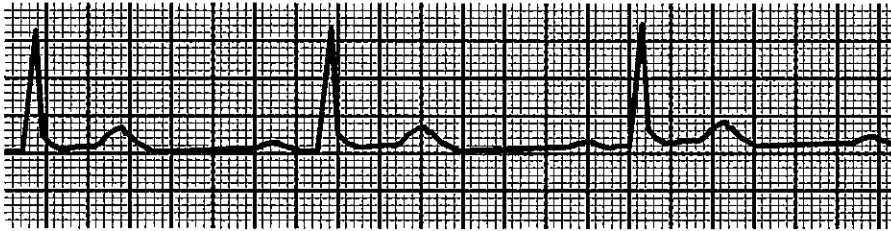


別冊 No. 3 写真

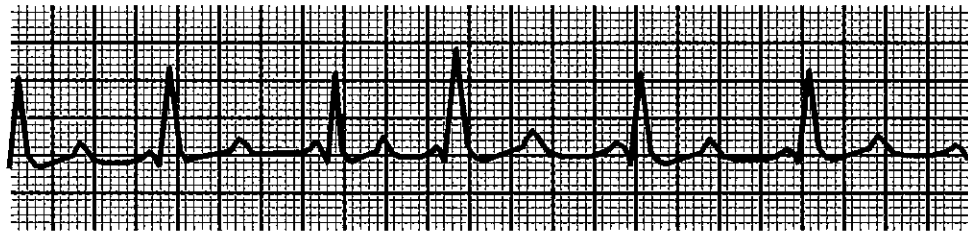
(O 問題16)



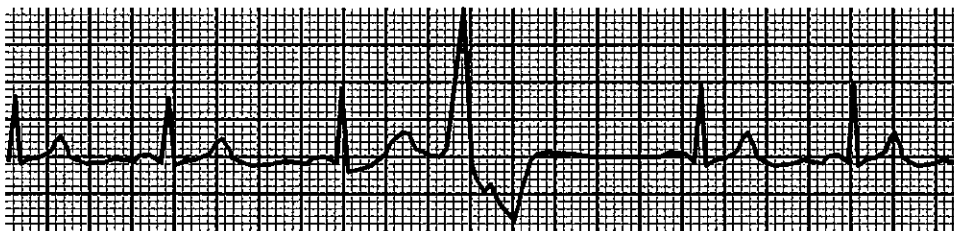




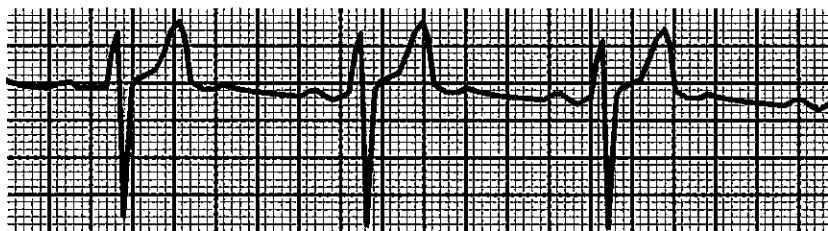
1. 洞性徐脈



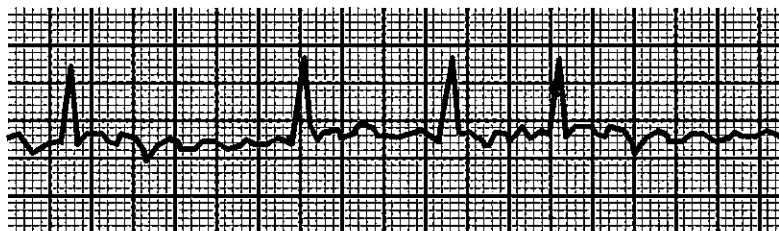
2. 上室性期外収縮



3. 心室性期外収縮



4. I度房室ブロック



5. 心室細動