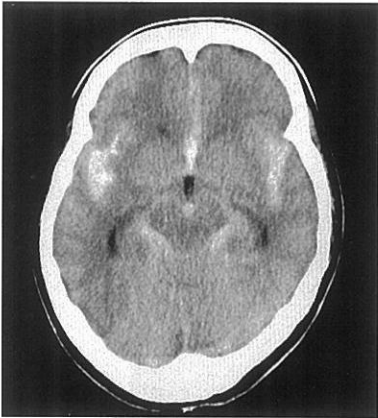


41

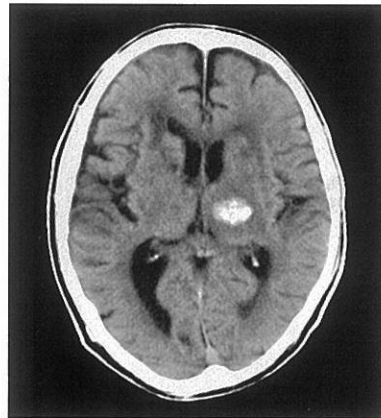
P 午 前

別 冊

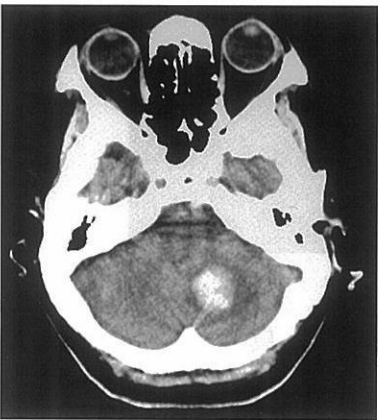




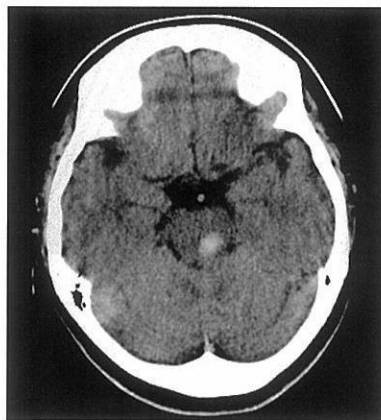
1. くも膜下出血



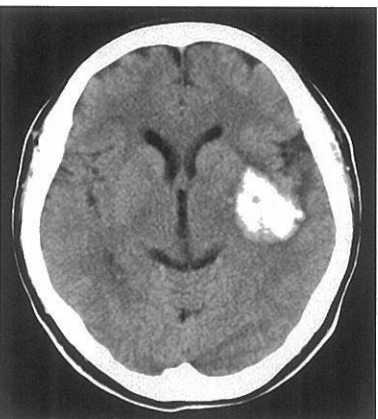2. 尾状核出血



3. 小脳出血



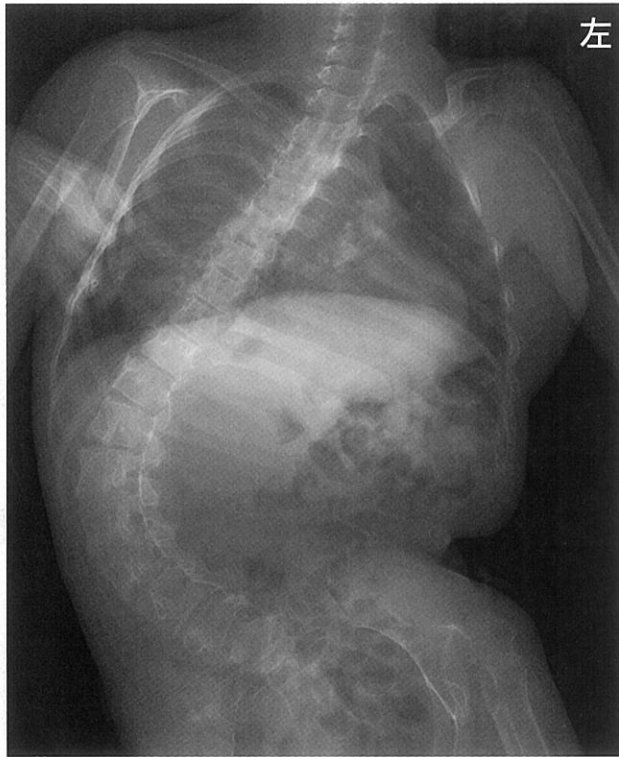
4. 脳幹出血



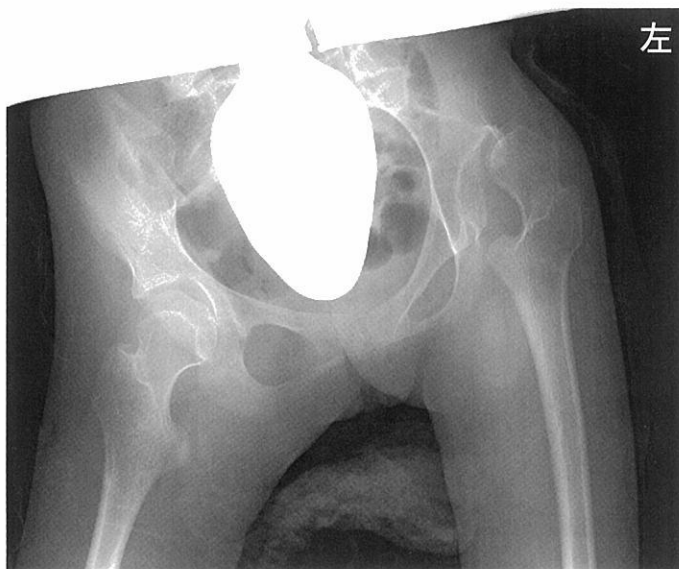5. 被殻出血

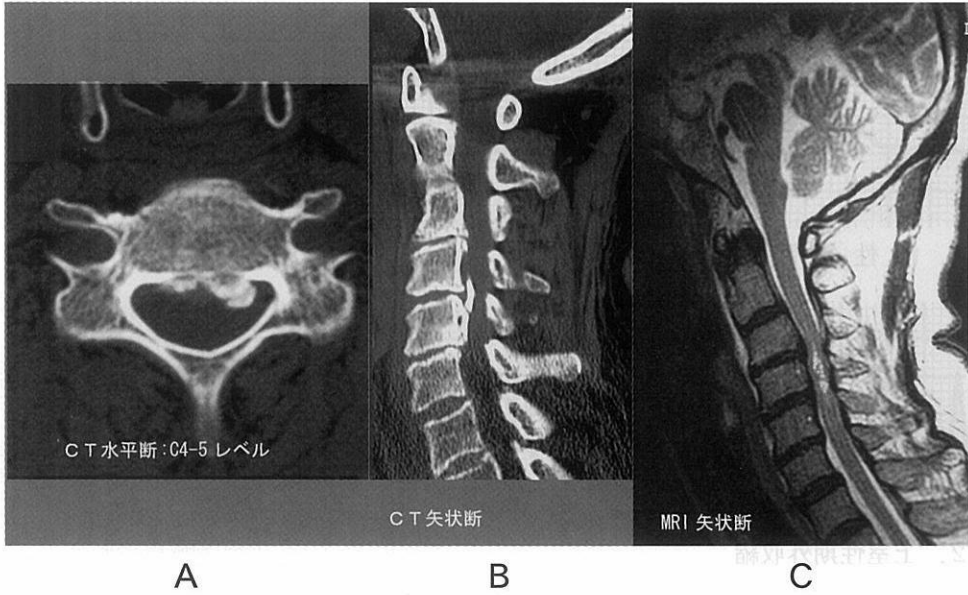
別冊 No. 3A 写真

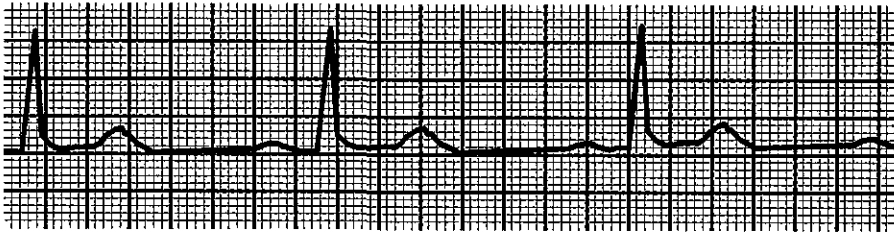
(P 問題13)



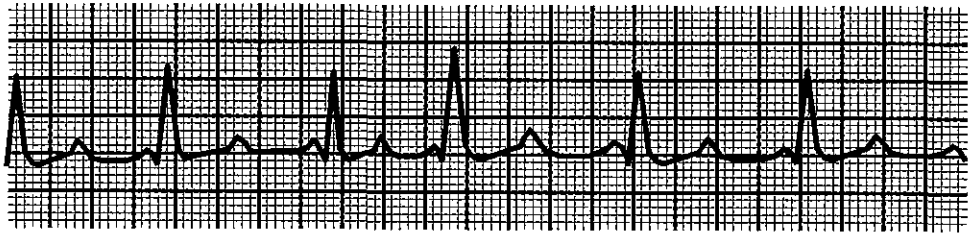
別冊 No. 3B 写真



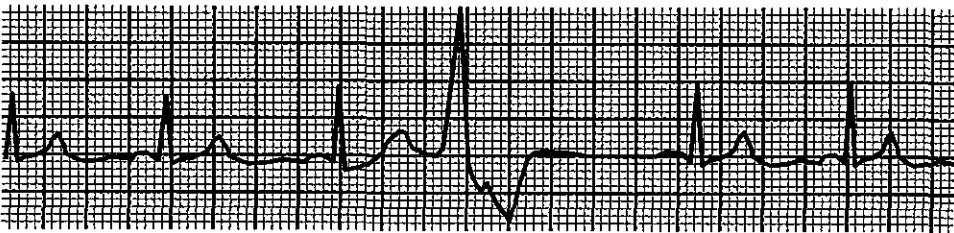




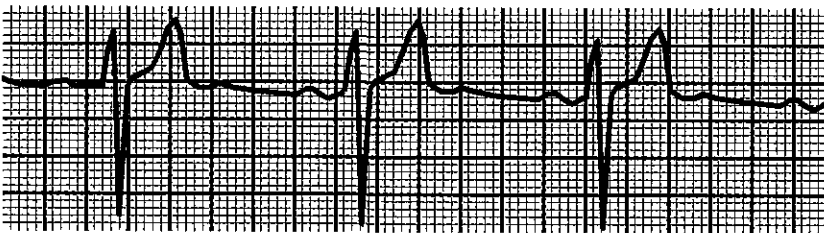
1. 洞性徐脈



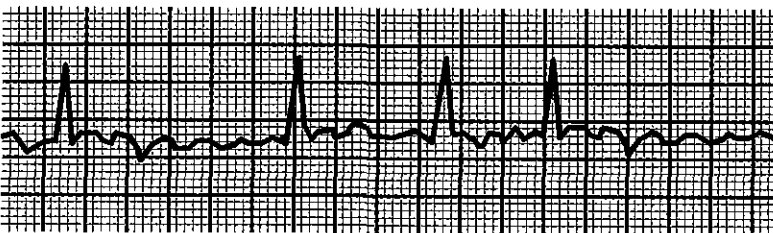
2. 上室性期外収縮



3. 心室性期外収縮



4. I度房室ブロック



5. 心室細動