

subsequently developed vCJD totals 66 individuals, of whom 42 have died (including both cases described above and the patient reported here) and 24 are alive. Since December, 2003, the surviving recipients and their doctors have been notified of their exposure to a vCJD-implicated transfusion. We report the development of vCJD in an individual from this cohort and discuss the clinical, neuroradiological, and pathological findings and their implications.

## Methods

### Research ethics and consent

The Medical Research Council (MRC) PRION-1 trial was established at the request of the UK Chief Medical Officer, and a national referral protocol was agreed by the MRC, Department of Health, the National Prion Clinic, and the National CJD Surveillance Unit so that all UK patients would have the opportunity to participate. The Chief Medical Officer wrote to all UK neurologists in 2004, requesting joint referral of all suspect cases to both the National CJD Surveillance Unit and the National Prion Clinic for possible participation in therapeutic trials and related research. The PRION-1 trial received ethics approval from the Eastern multi-centre research ethics committee. Tissues were removed at autopsy with consent for both diagnosis and research. Research studies on human tissue were approved by the Institute of Neurology/National Hospital for Neurology and Neurosurgery local research ethics committee.

### Immunoblotting

All procedures were done in a microbiological containment level-3 facility with strict adherence to safety protocols. Brain frontal cortex and tonsil lymphoid tissue were prepared as 10% weight per volume homogenates in Dulbecco's sterile phosphate buffered saline without calcium or magnesium using Duall tissue grinders (Anachem, Luton, UK).<sup>3</sup> Brain homogenates were analysed before or after proteinase K digestion (50 µg/mL final protease concentration, 1 h, 37°C) by immunoblotting with anti-PrP monoclonal antibody 3F4,<sup>8</sup> using high sensitivity enhanced chemiluminescence or standard enhanced chemifluorescence as described previously.<sup>3</sup> Tonsil homogenate was analysed by sodium phosphotungstic acid precipitation of PrP<sup>Sc</sup>, proteinase K digestion, and immunoblotting with anti-PrP monoclonal antibody 3F4 using high sensitivity enhanced chemiluminescence as described previously.<sup>3</sup> This method facilitates highly efficient recovery and detection of PrP<sup>Sc</sup> from vCJD tissue homogenate when present at concentrations 10<sup>4</sup>–10<sup>5</sup> times lower than those found in vCJD brain.<sup>3,9</sup>

### Immunohistochemistry

Brain and tonsil were assessed with anti-PrP monoclonal antibody ICSM 35 (D-Gen, London, UK), using a Ventana automated immunohistochemical staining machine

(Ventana Medical Systems, Tucson, AZ, USA) as described previously.<sup>9</sup> Tissue was fixed in 10% buffered formal saline followed by incubation in 98% formic acid for 1 h. Following further washing for 24 h in 10% buffered formal saline, tissue samples were processed and embedded in paraffin wax. Sections were cut at a nominal thickness of 4 µm, treated with 98% formic acid for 5 min and then boiled in a low ionic strength buffer (2.1 mM Tris, 1.3 mM EDTA, 1.1 mM sodium citrate, pH 7.8) for 20 min. Abnormal PrP accumulation was examined using anti-PrP monoclonal antibody ICSM 35 followed by a biotinylated-anti-mouse IgG secondary antibody (iView Biotinylated Ig, Ventana Medical Systems) and an avidin-biotin horseradish peroxidase conjugate (iView SA-HRP, Ventana Medical Systems) before development with 3,3'-diaminobenzidine tetrahydrochloride as the chromogen (iView DAB, Ventana Medical Systems). Haematoxylin was used as the counterstain. Haematoxylin and eosin staining of serial sections was done with conventional methods. Appropriate controls were used throughout.

### Role of the funding source

The sponsor of the study had no role in study design, data collection, data analysis, data interpretation, or writing of the report. The corresponding author had full access to all the data in the study and had final responsibility for the decision to submit for publication.

## Results

A 31-year-old male patient presented to the National Prion Clinic in 2005, with a 6-month history of progressive balance difficulties and impaired concentration. He had incapacitating leg pains and increasing difficulty walking. The patient had suffered from ulcerative colitis since his teenage years. A severe relapse of symptoms at a 22 years had led to surgical intervention with a colectomy and ileostomy. In 1997 (age 23 years), the ileostomy had been converted to an ileoanal J-pouch. Complications in the immediate postoperative period included pelvic bleeding; the patient was transfused with 22 units of red cells, 15 units of fresh frozen plasma, and three platelet doses, and required a further laparotomy and intensive care management. He then made a good recovery. One of the donors of the non-leucodepleted red cells received by the patient developed vCJD 20 months after donating this blood. This donor was homozygous (MM) at PRNP codon 129 and died after an 11-month illness, with neuropathological confirmation of vCJD.

6 years after the vCJD-implicated transfusion (age 29 years), the patient had presented to his family doctor with a short history of fluctuating exertional fatigue and impaired concentration. This problem was presumed to have followed a viral upper respiratory tract infection. Symptoms fluctuated, and around this time the patient and his doctor were notified of his exposure to a vCJD-implicated transfusion in 1997, and that he was

considered to be at risk of vCJD. Neurological examination, including clinical cognitive assessment, was normal and no biological symptoms of depressive illness were noted. Routine electroencephalogram and MR neuroimaging were normal (figure 1A and 1B). Some symptomatic improvement occurred, sufficient for the patient to return to work. At neurological review after a further year, persistent symptoms of fatigue and impaired concentration were noted with no abnormal examination findings.

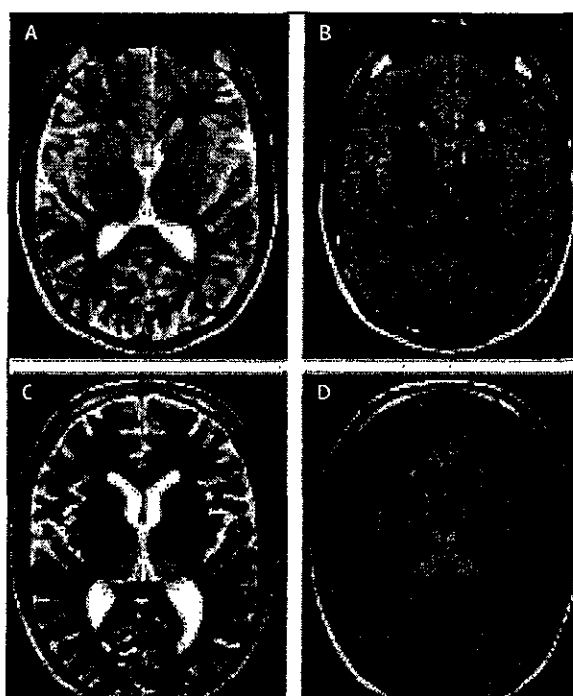
6 months later (age 31 years), 7.5 years after the vCJD-implicated transfusion, progressive neurological symptoms led to referral to the National Prion Clinic. The patient reported a sense of imbalance on turning with a tendency to stagger. Memory problems were becoming more prominent and he reported difficulties in recalling details of events in the preceding few days. He described a sense of tremor in his hands with reduced manual dexterity. Within a few weeks he reported severely incapacitating leg pains as an unvarying "searing pain" worsened by activity and eased by rest. Although most prominent in the anterior thighs, this pain affected the whole of both legs with hypersensitivity and paraesthesiae on touching the feet but no numbness or sensory loss. Examination 6 months after the onset of progressive neurological symptoms showed a mini mental state examination (MMSE) score of 30/30, digit recall of 6 forward and 5 backwards, with no evidence of dyspraxia or visuospatial dysfunction. The patient could walk unaided but preferred to use a stick to ease his leg pains. Other than minimal first-degree gaze-evoked nystagmus, cranial nerve and other neurological examination was normal.

Neurological decline continued with more prominent cognitive impairment. 6 weeks later, the patient's MMSE scored 22/30 (with errors in orientation for time, delayed recall, and serial subtraction). He was increasingly unsteady. Caregivers reported several falls, and the patient indicated that limb pains were less severe. Results of routine haematological and biochemical investigations, infection screen, and nerve conduction studies were normal. At this stage, MR neuroimaging showed symmetrical abnormal increased T2 and fluid attenuation inversion recovery (FLAIR) high signal within the posteromedial thalamus, consistent with the pulvinar sign (figure 1, C and D). Non-specific changes were evident on electroencephalogram. PRNP genotyping excluded genetic mutations associated with inherited prion disease and showed codon 129 methionine homozygosity. Tonsil biopsy was declined. The patient elected to join the quinacrine arm of the MRC PRION-1 trial<sup>10</sup> and began treatment with quinacrine at 300 mg daily.

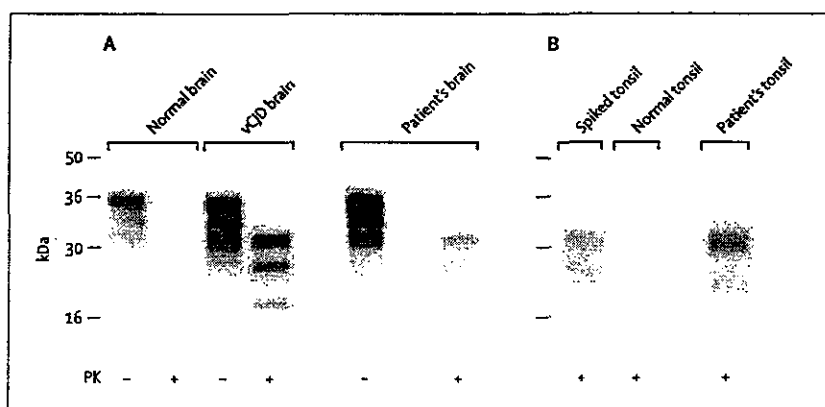
Subsequently the patient continued to decline with progressive cognitive impairment, ataxia, and dysarthria. He became bed-bound and poorly responsive before admission for hospice care. In line with the expressed

wishes of the patient and his family, medical intervention was kept to a minimum and neither gastrostomy nor nasogastric feeding were instituted. The patient died 8 years and 8 months after the vCJD implicated transfusion (age 32 years) and an autopsy was done.

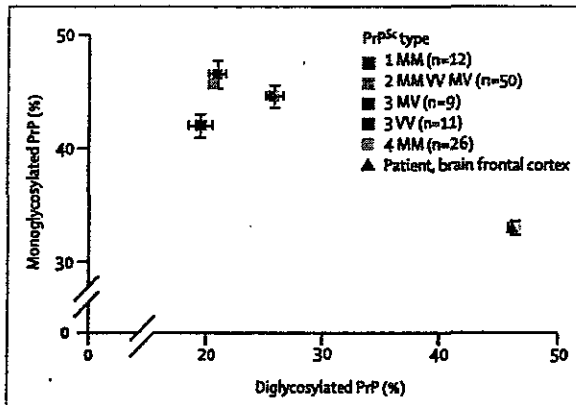
Brain and tonsil tissue were collected at autopsy and assessed for the presence of disease-related PrP by immunoblotting and immunohistochemistry. Immuno-



**Figure 1: MRI changes shown late in clinical course**  
MR neuroimaging 6 years after vCJD-implicated transfusion showing normal appearances on T2 and FLAIR sequences (A, B), with abnormal increased T2 and FLAIR high signal within the posteromedial thalamus evident 18 months later (C, D).

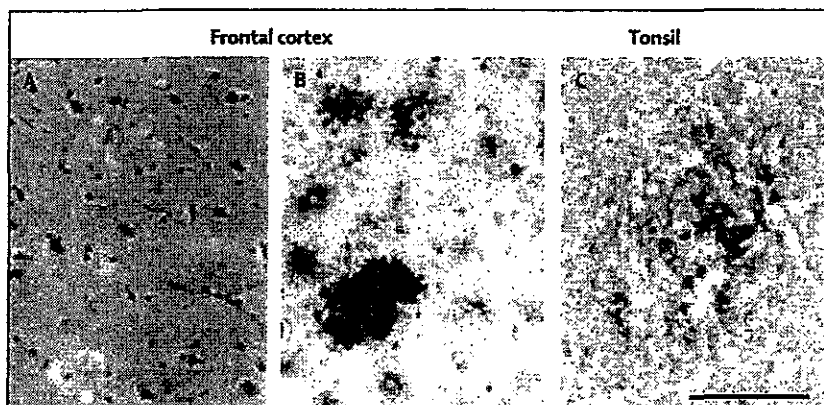


**Figure 2: Immunoblot detection of PrP<sup>Sc</sup> in brain and tonsil**  
(A) 5- $\mu$ l samples of 10% brain homogenate (frontal cortex) from normal human control, vCJD case, or the patient were analysed before (-) or after (+) proteinase K (PK) digestion. (B) PK-digested sodium phosphotungstic acid pellets from 0.5 mL 10% normal human tonsil homogenate or 0.5 mL 10% normal human tonsil homogenate spiked with 1  $\mu$ l 10% brain homogenate from patient are compared with PK-digested sodium phosphotungstic acid pellet from 0.25 mL 10% tonsil homogenate from patient. Immunoblots were analysed with anti-PrP monoclonal antibody 3F4 using high sensitivity chemiluminescence.



**Figure 3:** Analysis of PrP<sup>Sc</sup> glycoform ratios. Relative proportions of diglycosylated and monoglycosylated PrP<sup>Sc</sup> glycoforms after part-digestion of brain homogenate with proteinase K and immunoblotting with monoclonal antibody 3F4 using enhanced chemifluorescence. Key shows control cases of known PrP<sup>Sc</sup> type and PRNP codon 129 genotype. PrP<sup>Sc</sup> types 1–3 are seen in the brain in classical CJD (either sporadic or iatrogenic). PrP<sup>Sc</sup> type 4 is uniquely seen in vCJD brain.<sup>11,12</sup> PrP<sup>Sc</sup> typing according to classification of Hill et al.<sup>13</sup> Error bars show SE and where not visible were smaller than symbols used to designate means.

blotting of frontal cortex showed the presence of type 4 PrP<sup>Sc</sup> (figure 2A, figure 3) pathognomonic of vCJD.<sup>11</sup> Immunohistochemical analysis of brain showed widespread deposition of abnormal PrP in all cortical areas and throughout the cerebellum, with occurrence of abundant florid PrP plaques (figure 4A and 4B) characteristic of vCJD.<sup>13</sup> Spongiform change, gliosis, and distribution of PrP<sup>Sc</sup> were indistinguishable from those found in previous cases of vCJD. Immunoblot analysis of lymphoid tissue from tonsil showed the presence of type 4 PrP<sup>Sc</sup> at a concentration of about 1% of the level of PrP<sup>Sc</sup> detected in brain (figure 2B). Immunohistochemical analysis of tonsil showed multiple lymphatic follicles containing an abnormal PrP immunostaining pattern typical of that seen in vCJD (figure 4C).<sup>14</sup> Spleen was also positive (data not shown).



**Figure 4:** PrP immunohistochemistry of patient's brain and tonsil. (A) Haematoxylin and eosin staining of frontal cortex tissue showing florid plaques. (B) Immunohistochemistry of frontal cortex tissue showing abnormal PrP immunoreactivity, including abundant PrP plaques (anti-PrP monoclonal antibody ICSM 35). (C) Abnormal PrP immunoreactivity in tonsil (ICSM 35). The immunostaining pattern is typical of that observed in vCJD tonsil.<sup>14</sup> Scale bar=100 µm.

## Discussion

This third reported case of prion infection after red-cell transfusion from an asymptomatic donor who later developed vCJD emphasises the substantial risk faced by other recipients of vCJD-implicated blood components, and indeed suggests that blood transfusion is an efficient route of transmission of vCJD prion infection. The probability of vCJD occurring in a single individual in this at-risk population in the absence of transfusion-transmitted infection has been estimated at between one in 15 000 and one in 30 000;<sup>5</sup> the probability of chance occurrence of three such cases in this small group is remote. Uncertainty surrounds the risk of vCJD transmission by blood transfusion, and by products made by plasma fractionation, which have not yet been associated with any vCJD cases. Because the clinical silent incubation period of prion infections in human beings is known to be long (it can exceed half a century<sup>15</sup>), and the prevalence of asymptomatic infection in the general population of the UK is therefore unknown,<sup>1</sup> the extent of transfusion-transmission of vCJD can not yet be estimated. In the present and previously reported clinical cases, symptoms developed 6 and 6.5 years after blood transfusion, respectively; both individuals were homozygous for methionine (MM) at PRNP codon 129. Transmission of prion diseases between species are generally associated with much longer mean incubation periods than within-species transmissions, because of the so-called species or transmission barrier effect.<sup>1</sup> Therefore, mean incubation periods of secondary vCJD (involving person-to-person transmission) would be expected to have considerably shorter mean incubation periods than in primary vCJD resulting from exposure to BSE prions. That the incubation periods seen in the first cases of secondary vCJD, by definition those with the shortest incubation periods, were 6–6.5 years suggests that the shortest incubation periods of primary vCJD are longer, especially as the oral route of transmission is also typically associated with longer incubation periods than parenteral routes. A preliminary estimate of the shortest incubation periods of primary vCJD, based on the youngest cases seen, is around 12 years, which would be consistent with such extrapolation from the shortest incubation periods in secondary vCJD.<sup>15</sup>

The patient whose case we report here had ulcerative colitis. Experimentally induced chronic inflammatory foci can act as sites for prion propagation.<sup>16</sup> Although ulcerative colitis is a relatively common condition and not infrequently necessitates blood transfusion, it will be of interest to see if future cases had co-existent chronic inflammatory conditions at the time of prion exposure, which might indicate a role in susceptibility or incubation periods.

Whether individuals with the other PRNP codon 129 genotypes, VV and MV, will also succumb but with longer mean incubation periods is unknown. The PRNP 129MV blood recipient had evidence of prion

infection of lymphoreticular tissues at autopsy but died from a ruptured abdominal aortic aneurysm with no reported evidence of a neurological disorder; the brain showed no pathological features of vCJD.<sup>6</sup> It is unclear whether this individual would have gone on to develop clinical prion disease had they lived longer, and if so whether they would have had the phenotype of vCJD. Subclinical or carrier states of prion infection are recognised in animal models,<sup>17,18</sup> including BSE or vCJD prion-inoculated transgenic mice expressing human prion proteins.<sup>19–21</sup> Evidence from these studies suggests that individuals with such genotypes will be susceptible, but might develop disease phenotypes distinct from that of vCJD because of selection and propagation of different prion strain types.<sup>20,21</sup> The absence of detectable strain PrP<sup>Sc</sup> in the MV patient precluded molecular strain typing of prions. Although Peden and colleagues showed that splenic PrP<sup>Sc</sup> from this case resembled that seen in vCJD,<sup>6</sup> this demonstration required use of phosphotungstic acid precipitation of PrP<sup>Sc</sup>, which interferes with molecular strain typing.<sup>3</sup> Additionally, type 5 PrP<sup>Sc</sup>, seen in vCJD-inoculated transgenic mice expressing human PrP 129V, but not yet documented in humans, has a similar glycoform profile.<sup>12,20,21</sup> This patient might have been propagating a prion strain distinct from that causing vCJD.

Importantly, Peden and colleagues noted that they were unable to detect PrP<sup>Sc</sup> in lymphoid follicles in tonsil, appendix, or large intestine from their patient, although abnormal PrP was detected in spleen and in a cervical lymph node. Although concentrations of PrP<sup>Sc</sup> seen in their case were low,<sup>6</sup> perhaps indicating an early stage of incubation, PrP<sup>Sc</sup> levels are generally higher in tonsil than elsewhere in the lymphoreticular system in vCJD.<sup>22</sup> Because tonsillar involvement has to date been invariably seen in clinically affected cases of vCJD, Peden and colleagues speculated that this case might represent a distinctive pathogenesis related to route of exposure (intravenous rather than the oral route of exposure to BSE prions presumed in primary vCJD), and that the absence of a species barrier in secondary (person-to-person) infection might also affect phenotype. The current findings argue against these interpretations, and suggest that absence of tonsillar PrP<sup>Sc</sup> in the MV blood recipient might have been due to the effect of PRNP genotype and perhaps selection of a distinctive prion strain.

The patient's clinical course was characterised by a prolonged prodromal illness with fluctuating fatigue and clouded thinking, preceding progressive neurological deficit by 2 years. This case illustrates a clinical course of human vCJD prion infection characterised by five stages. A preclinical incubation phase of about 6 years occurred after blood transfusion, followed by a prodromal phase with fluctuating exertional fatigue and impaired concentration lasting about 18 months, and during which routine clinical examination and MR neuroimaging

remained normal. Progressive neurological decline then consisted of an approximately 9-month initial phase of progressive ataxia, impaired manual dexterity, and dysaesthetic limb pain with substantial cognitive impairment but retained communication and comprehension of routine daily activities. A late neurological phase with severe cognitive decline and impaired verbal communication of about 4 months was followed by a shorter terminal phase in which the patient was bed-bound, mute, and only partly responsive.

Route of infection with prions is known to affect clinical phenotype<sup>7</sup> and, if directly related to prion infection, the lengthy fluctuating prodrome in this case might be a consequence of infection through blood transfusion. The early symptoms of vCJD are usually reported as non-specific, and detailed neurological examination in this patient at an unusually early stage in the clinical disease course was normal. The subsequent neurological decline characterised by progressive ataxia, cognitive impairment, and painful limb symptoms, was typical of vCJD.

vCJD has an insidious clinical onset, and its early features—such as depression, anxiety, personality change, and sensory disturbances—are highly non-specific. Early diagnosis is therefore difficult in the absence of another reason to suspect prion infection. This case illustrates the importance of diagnosis as early as possible in the clinical course. The patient was able to consider the option of joining a therapeutic clinical trial, to fully discuss the implications of his diagnosis, and to communicate his wishes to the clinical team and his family, making decisions and arrangements about his future care and other affairs. Specialist monitoring and investigation of high-risk groups, such as recipients of blood transfusion from a donor who developed vCJD, should allow the condition to be recognised at an early stage.

Careful clinical assessment remains the most important element in the early detection of symptomatic disease. The most useful non-invasive investigation in advanced cases of vCJD has been MR neuroimaging, particularly the FLAIR sequence.<sup>24</sup> Early case reports noted bilateral increased signal in the posterior thalamus (pulvinar) on T2 weighted images.<sup>25</sup> A retrospective review of MR scans from 36 histologically confirmed cases of vCJD, with a control group composed mainly of patients with other forms of human prion disease, suggested that the pulvinar sign occurred frequently in advanced cases of vCJD.<sup>26</sup> These investigators reported a sensitivity of up to 86% and specificity of up to 96% in this series, but suggested that this sign might be a late feature of the disease process. Histologically confirmed cases of vCJD with minimal or absent pulvinar changes on MR neuroimaging at a mean 10.5 months during an illness of mean 15 months duration were identified in this series. Values of 81% sensitivity and 94% specificity have also been reported in a series including 27 cases of vCJD

diagnosed by tonsil biopsy.<sup>27</sup> As these studies suggest, the pulvinar sign is not specific for vCJD. These MRI appearances are described in sporadic CJD<sup>28</sup> and paraneoplastic limbic encephalitis,<sup>29</sup> both of which are important considerations in the differential diagnosis of patients with suspected vCJD. Pulvinar signal change on MRI is also reported in several rare conditions that might otherwise be distinguished from vCJD on clinical grounds, such as benign intracranial hypertension,<sup>30</sup> status epilepticus associated with cat scratch disease,<sup>31</sup> Alpers' disease,<sup>32</sup> and post infectious encephalitis.<sup>33</sup> As this present case further exemplifies, the absence of characteristic MR findings does not exclude a diagnosis of vCJD. In fact, this case provides important insights into the relation of the pulvinar sign to clinical progression of the disease, suggesting that it could be a late feature. Quantitative MR spectroscopy studies in a small series of patients raises the possibility that more sensitive techniques might be helpful earlier in the clinical course.<sup>34</sup>

Tonsillar biopsy remains the most sensitive and specific diagnostic procedure for vCJD.<sup>22,34,35,33</sup> Tonsillar PrP<sup>Sc</sup> is uniformly present in clinically affected cases of vCJD but not in other forms of human prion disease, including iatrogenic CJD associated with use of human cadaveric derived pituitary hormones, arguing that this distinctive pathogenesis relates to effect of prion strain rather than to a peripheral route of infection.<sup>22,35</sup> As infection of lymphoreticular tissues is thought to precede neuro-invasion, and indeed has been detected in archived surgical samples removed before development of vCJD,<sup>36,37</sup> it is likely to allow firm diagnosis at the early clinical stage or indeed pre-clinically.<sup>7</sup> The case described here confirms that tonsillar infection occurs in secondary vCJD prion infection, at least in PRNP 129MM individuals. This finding is also of relevance to interpretation of results in due course from analysis of the National Anonymous Tonsil Archive, which aims to screen 100 000 tonsils for disease-associated PrP to estimate prevalence of vCJD prion infection in the UK population.<sup>38</sup> Given the advent of experimental therapeutics for prion disease, including the MRC PRION-1 trial<sup>7,39</sup> tissue diagnosis might be considered for asymptomatic individuals from high-risk groups so that early access to therapeutic trials can be offered, ideally before neuroinvasion, at a stage when infection may be more accessible or responsive to therapeutic intervention. Until further data are obtained on lymphoreticular pathogenesis in patients with the PRNP 129 VV and MV genotypes it would be prudent to consider biopsy of lymph nodes as well as tonsil in such patients. Since the successful interruption of disease progression in peripherally infected laboratory mice with monoclonal antibodies against prion protein, the future use of humanised versions of these antibodies in secondary prophylaxis might also be possible in individuals known to be at high risk of developing clinical forms of human prion disease.<sup>39</sup> All individuals found to

have received potentially infected blood are now notified of their risk status, inevitably causing distress and uncertainty. Counselling in this situation, including discussion of public-health risks and management options, has parallels with counselling for people at risk of inherited forms of prion disease. Individuals will differ in their wishes for further investigation and early diagnosis, but all should be given the opportunity of immediate access to specialist advice, assessment, and long-term support.

#### Contributors

S J Wroe, S Pal, D Siddique, H Hyare, and R Macfarlane were responsible for the clinical case report and MRI findings, P Hewitt collected and provided blood transfusion data. J D F Wadsworth and S Joiner did biochemical analyses. S Brandner and J Linehan did neuropathological analyses. All authors contributed to drafting the manuscript and approved the final version. J Collinge directed the study, had full access to all the data, and had final responsibility for the decision to submit for publication.

#### Conflict of interest statement

JC is a director and JC and JDFW are shareholders and consultants of D-Gen Limited, an academic spin-out company working in prion disease diagnosis, decontamination, and therapeutics. D-Gen markets one of the routine antibodies (ICSM 35) used in this study. The other authors declare that they have no conflict of interest.

#### Acknowledgments

We thank Kate Soldan and Noel Gill at the Health Protection Agency for advice on the patient's notification dates and helpful comments on the case report; C O'Malley, M Hainsworth, and C Powell for technical assistance with immunohistochemistry, and R Young for preparation of the figures. We especially thank the patient and his family for generously consenting to publication of the case report and for use of human tissues in research. This work was funded by the UK Medical Research Council.

#### References

- Collinge J. Variant Creutzfeldt-Jakob disease. *Lancet* 1999; 354: 317-23.
- Hill AF, Butterworth RJ, Joiner S, et al. Investigation of variant Creutzfeldt-Jakob disease and other human prion diseases with tonsil biopsy samples. *Lancet* 1999; 353: 183-89.
- Wadsworth JDF, Joiner S, Hill AF, et al. Tissue distribution of protease resistant prion protein in variant Creutzfeldt-Jakob disease using a highly sensitive immuno-blotting assay. *Lancet* 2001; 358: 171-80.
- Hunter N, Foster J, Chong A, et al. Transmission of prion diseases by blood transfusion. *J Gen Virol* 2002; 83: 2897-905.
- Llewelyn CA, Hewitt PE, Knight RSG, et al. Possible transmission of variant Creutzfeldt-Jakob disease by blood transfusion. *Lancet* 2004; 363: 417-21.
- Peden AH, Head MW, Ritchie DL, Bell JE, Ironside JW. Preclinical vCJD after blood transfusion in a PRNP codon 129 heterozygous patient. *Lancet* 2004; 364: 527-29.
- Collinge J. Molecular neurology of prion disease. *J Neurol Neurosurg Psychiatry* 2005; 76: 906-19.
- Kascsak RJ, Rubenstein R, Merz PA, et al. Mouse polyclonal and monoclonal antibody to scrapie-associated fibril proteins. *J Virol* 1987; 61: 3688-93.
- Frosh A, Smith LC, Jackson CJ, et al. Analysis of 2000 consecutive UK tonsillectomy specimens for disease-related prion protein. *Lancet* 2004; 364: 1260-62.
- MRC Clinical Trials Unit. PRION-1: Randomised trial of quinacrine in human prion disease. <http://www.ctu.mrc.ac.uk/studies/cjd.asp> (accessed Sept 8, 2006).
- Collinge J, Sidle KCL, Meads J, Ironside J, Hill AF. Molecular analysis of prion strain variation and the aetiology of 'new variant' CJD. *Nature* 1996; 383: 685-90.
- Hill AF, Joiner S, Wadsworth JDF, et al. Molecular classification of sporadic Creutzfeldt-Jakob disease. *Brain* 2003; 126: 1333-46.

- 13 Will RG, Ironside JW, Zeidler M, et al. A new variant of Creutzfeldt-Jakob disease in the UK. *Lancet* 1996; 347: 921-25.
- 14 Hill AF, Zeidler M, Ironside J, Collinge J. Diagnosis of new variant Creutzfeldt-Jakob disease by tonsil biopsy. *Lancet* 1997; 349: 99-100.
- 15 Collinge J, Whitfield J, McKintosh E, et al. Kuru in the 21st century—an acquired human prion disease with very long incubation periods. *Lancet* 2006; 367: 2068-74.
- 16 Heikenwalder M, Zeller N, Seeger H, et al. Chronic lymphocytic inflammation specifies the organ tropism of prions. *Science* 2005; 307: 1107-10.
- 17 Hill AF, Joiner S, Linehan J, Desbruslais M, Lantos PL, Collinge J. Species barrier independent prion replication in apparently resistant species. *Proc Natl Acad Sci USA* 2000; 97: 10248-53.
- 18 Hill AF, Collinge J. Subclinical prion infection. *Trends Microbiol* 2003; 11: 578-84.
- 19 Asante EA, Linehan JM, Desbruslais M, et al. BSE prions propagate as either variant CJD-like or sporadic CJD-like prion strains in transgenic mice expressing human prion protein. *EMBO J* 2002; 21: 6358-66.
- 20 Wadsworth JDF, Asante EA, Desbruslais M, et al. Human prion protein with valine 129 prevents expression of variant CJD phenotype. *Science* 2004; 306: 1793-96.
- 21 Bishop MT, Hart P, Aitchison L, et al. Predicting susceptibility and incubation time of human-to-human transmission of vCJD. *Lancet Neurol* 2006; 5: 393-98.
- 22 Asante EA, Linehan JM, Gowland I, et al. Dissociation of pathological and molecular phenotype of variant Creutzfeldt-Jakob disease in transgenic human prion protein 129 heterozygous mice. *Proc Natl Acad Sci USA* 2006; 103: 10759-64.
- 23 Hill AF, Desbruslais M, Joiner S, et al. The same prion strain causes vCJD and BSE. *Nature* 1997; 389: 448-50.
- 24 Collie DA, Summers DM, Sellar RJ, et al. Diagnosing variant Creutzfeldt-Jakob disease with the pulvinar sign: MR imaging findings in 86 neuropathologically confirmed cases. *AJNR Am J Neuroradiol* 2003; 24: 1560-69.
- 25 Chazot G, Broussole E, Lapras CI, Blattler T, Aguzzi A, Kopp N. New variant of Creutzfeldt-Jakob disease in a 26-year-old French man. *Lancet* 1996; 347: 1181.
- 26 Zeidler M, Sellar RJ, Collie DA, et al. The pulvinar sign on magnetic resonance imaging in variant Creutzfeldt-Jakob disease. *Lancet* 2000; 355: 1412-18.
- 27 Siddique D, Kennedy A, Thomas D, et al. Tonsil biopsy in the investigation of suspected variant Creutzfeldt-Jakob disease—a cohort study of 50 patients. *J Neurol Sci* 2005; 238: S1-S570.
- 28 Rossetti AO, Bogousslavsky J, Glatzel M, Aguzzi A. Mimicry of variant Creutzfeldt-Jakob disease by sporadic Creutzfeldt-Jakob disease: importance of the pulvinar sign. *Arch Neurol* 2004; 61: 445-46.
- 29 Mihara M, Sugase S, Konaka K, et al. The "pulvinar sign" in a case of paraneoplastic limbic encephalitis associated with non-Hodgkin's lymphoma. *J Neurol Neurosurg Psychiatry* 2005; 76: 882-84.
- 30 Yoshimura N, Soma Y. A case of benign intracranial hypertension with bilateral reversible thalamic lesions on magnetic resonance imaging. *Rinsho Shinkeigaku* 1992; 32: 327-29.
- 31 Hahn JS, Sum JM, Lee KP. Unusual MRI findings after status epilepticus due to cat-scratch disease. *Pediatr Neurol* 1994; 10: 255-58.
- 32 Harding BN, Alsanjari N, Smith SJ, et al. Progressive neuronal degeneration of childhood with liver disease (Alpers' disease) presenting in young adults. *J Neurol Neurosurg Psychiatry* 1995; 58: 320-25.
- 33 Cusmai R, Bertini E, Di Capua M, et al. Bilateral, reversible, selective thalamic involvement demonstrated by brain MR and acute severe neurological dysfunction with favorable outcome. *Neuropediatrics* 1994; 25: 44-47.
- 34 Cordery RJ, Macmanus D, Godbolt A, Rossor MN, Waldman AD. Short TE quantitative proton magnetic resonance spectroscopy in variant Creutzfeldt-Jakob disease. *Eur Radiol* 2006; 16: 1692-98.
- 35 Hilton DA, Sutak J, Smith ME, et al. Specificity of lymphoreticular accumulation of prion protein for variant Creutzfeldt-Jakob disease. *J Clin Pathol* 2004; 57: 300-02.
- 36 Hilton DA, Fathers E, Edwards P, Ironside JW, Zajicek J. Prion immunoreactivity in appendix before clinical onset of variant Creutzfeldt-Jakob disease. *Lancet* 1998; 352: 703-04.
- 37 Hilton DA, Ghani AC, Conyers L, et al. Prevalence of lymphoreticular prion protein accumulation in UK tissue samples. *J Pathol* 2004; 203: 733-39.
- 38 Health Protection Agency. The National Anonymous Tonsil Archive (NATA). [http://www.hpa.org.uk/infections/topics\\_az/cjd/tonsil\\_archive.htm](http://www.hpa.org.uk/infections/topics_az/cjd/tonsil_archive.htm) (accessed Sept 8, 2006).
- 39 Mallucci G, Collinge J. Rational targeting for prion therapeutics. *Nat Rev Neurosci* 2005; 6: 23-34.



医薬品  
医薬部外品 研究報告 調査報告書  
化粧品

識別番号・報告回数		報告日		第一報入手日 2006年12月25日	新医薬品等の区分	厚生労働省処理欄
一般的名称	①②③人血清アルブミン ④乾燥濃縮人血液凝固第Ⅷ因子 ⑤乾燥濃縮人血液凝固第Ⅸ因子	研究報告の 公表状況	LANCET 2006; 368: 2226-2230	公表国 アメリカ		
販売名 (企業名)	①献血アルブミン-Wf (ベネシス) ②献血アルブミン(5%)-Wf (ベネシス) ③アルブミン-Wf (ベネシス) ④コンコエイト-HT (ベネシス) ⑤クリスマシン-M (ベネシス)					
研究報告の概要	<p>TSEは輸血によって感染する。献血血液からの原因病原体を選択的に吸着するのが、このリスクを処理する最も良い方法の1つであるかもしれない。我々が行った研究では、ヒト赤血球製剤にスパイクした脳由来の感染性物質を約 4 log ID50 減らすことのできるアフィニティ樹脂 L13 と製造スケールで製造された同等能力の L13A とについて、血液中に存在する内因性 TSE 感染性物質の除去能力を評価した。スクレイパーに感染させたハムスターの全血 500mL を使用し、白血球除去によって感染性の 72% が除去された。白血球除去した全血をそれぞれのアフィニティ樹脂 1mL 当り 50mL を処理した。白血球除去した全血を接種した 99 匹の内、15 匹が感染したが、各々の樹脂を通過して得られた最終産物を接種された 96 匹又は 100 匹はいずれも、540 日後に発症しなかった。このバイオアッセイの検出限界は 0.2 感染用量/ml であった。白血球除去した方の感染性の減少は全体で 1.22 log ID 以上であった。</p> <p>この結果は白血球除去した全血から、アフィニティ樹脂によって内因性 TSE 感染性物質が除去されることを示していた。この同じ樹脂は血液成分の存在下で、変異型、孤発型及び家族性の CJD からの正常及び異常プリオン蛋白を吸着する。</p>					<p>使用上の注意記載状況・ その他参考事項等</p> <p>代表として献血アルブミン-Wf の記載を示す。 2. 重要な基本的注意 (1) 略 1) 略 2) 現在までに本剤の投与により変異型クロイツフェルト・ヤコブ病 (vCJD) 等が伝播したとの報告はない。しかしながら、製造工程において異常プリオンを低減し得るとの報告があるものの、理論的な vCJD 等の伝播のリスクを完全には排除できないので、投与の際には患者への説明を十分行い、治療上の必要性を十分検討の上投与すること。</p>
	報告企業の意見				今後の対応	
<p>スクレイパーに感染させたハムスターの白血球除去後の全血をアフィニティ樹脂で処理することにより、その感染性を除去したとの報告である。</p> <p>これまで血漿分画製剤によって vCJD、スクレイパー及び CWD を含むプリオン病が伝播したとの報告はない。しかしながら、万一 vCJD 感染者の血漿が本剤の原料に混入した場合には、製造工程においてプリオンを低減し得るとの報告があるものの、製剤から伝播する可能性を完全には否定し得ない。そのため、弊社の血漿分画製剤の製造工程における TSE 感染性低減に関する検証実験を加速し、自社データを早期に取得し、工程評価を行い、必要に応じて工程改善を実施する予定である。</p>				<p>本報告は本剤の安全性に影響を与えないと考えるので、特段の措置はとらない。</p>		



