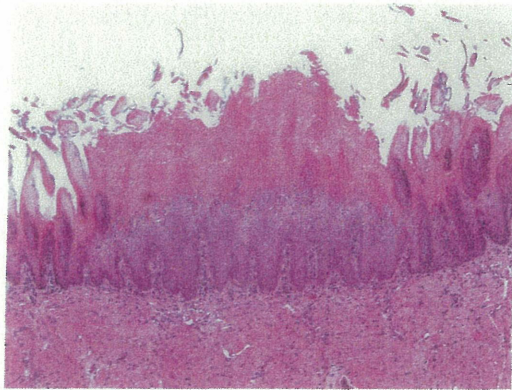


舌：上皮過形成  
(Hyperplasia)



舌：乳頭腫  
(Papilloma)

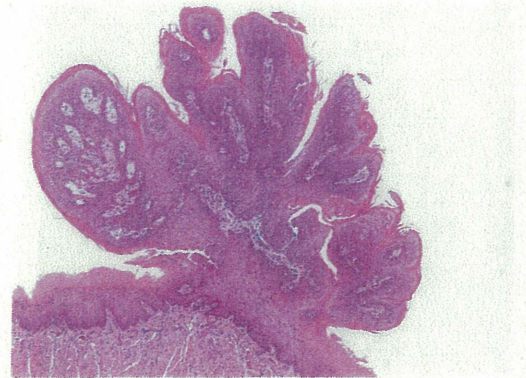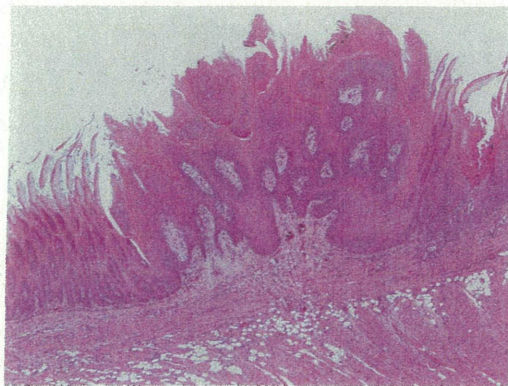


図2. 4NQO+5.5%“DAG”投与群 (Tgラット雄)