

労災疾病臨床研究事業費補助金

革新的高次能機能治療法の樹立 (14050101)

平成26年度 総括・分担研究報告書

研究代表者 石内 勝吾

平成27(2015)年 5月

目 次

I. 総括研究報告		
革新的高次脳機能治療法の樹立 (14050101) 研究	-----	1
研究代表者氏名 石内勝吾		
(資料) 海馬機能評価法 (特願2014-074112)		
II. 分担研究報告		
1. ニューロリハビリテーション治療の樹立に関する研究	-----	6
分担研究者1氏名 渡邊 孝		
分担研究者2氏名 菅原健一		
(資料) tDCS資料		
2. 高次脳機能解析に関する研究	-----	8
分担研究者3氏名 外間洋平		
(資料) 高次脳機能解析に関する資料		
3. 機能的画像解析に関する研究	-----	11
分担研究者4氏名 西村正彦		
(資料) 機能的画像解析に関する資料		
III. 研究成果の刊行に関する一覧表	-----	13
IV. 研究成果の刊行物・別刷	-----	15

I. 労災疾病臨床研究事業費補助金
(総括) 研究報告書

革新的高次脳機能治療法の樹立に関する研究

研究代表者 石内 勝吾

研究要旨 革新的な高次脳機能障害の診断法と治療の労災補償行政の施策等への活用
の可能性を目的に抜本的な高次脳機能障害に対する治療法の樹立に向けて、
大脳・小脳を含む神経回路網の機能的ネットワークの再生と同時に海馬機能
の回復が重要とする我々の仮説に基づき、脳機能イメージングの手法を駆使
して大規模ネットワーク内での相互作用の解析と同時によりスケールダウ
ンした海馬体に焦点を絞った研究を行った。

その結果、海馬神経新生能が低下した5症例のうち中等度以上の障害が示
唆された3症例を対象に左側 DLPFC(dorsolateral prefrontal cortex)を陽極
にて transcranial direct cortical stimulation (tDCS) 1mA.30分間1日1回、
1クール5回で計画し(通常1~2クール)直流刺激治療を施行した。その
結果、海馬歯状回パターン分離機能の改善に伴い記憶および注意機能等の高
次脳機能の改善を全例で認めた。少数例の探索結果であるがヒトにおいて海
馬歯状回部のシナプス機能の回復が高次脳機能障害の回復に本質的な役割を担
う手がかりを掴むことが出来た。今後、最適刺激部位の同定および海馬を含む
大脳、小脳の可塑性を高め機能障害に陥った神経回路網の機能的再構成に
関する最新の知見に基づく新しいニューロリハビリテーションの手法の確
立につなげたい。

研究分担者氏名・所属研究機関名及
び所属研究機関における職名

渡邊孝・琉球大学医学部・講師
菅原健一・琉球大学医学部・講師
外間洋平・琉球大学医学部・助教
西村正彦・琉球大学医学部・助教

や脳卒中による低酸素脳症 3) 炭塵爆発
事故による遷延化した一酸化中毒を対象
に疾患により引き起こされた高次脳機能
障害の革新的な治療法の確立を目的にす
る。

B. 研究方法

本研究では高次脳機能障害を小脳と海馬
および前頭前野を含む神経回路網のネット
ワーク障害として捉える仮説を提示します
(*Cerebellum submission*) (添付資料参

A. 研究目的

本研究の目的は労災による1) 交通事
故、転倒・転落事故等によるびまん性軸
索損傷、2) 過労により発症した心筋梗塞

照)。高性能3T MRIを用いて安静時脳活動を評価した神経回路網の形態を拡散テンソル画像を用いて視覚化した。これらの基盤情報に基づいて経頭蓋直流電流刺激法と薬物療法を組み合わせる最新のニューロリハビリを施行する事で海馬の神経新生を促進し、同時に小脳・大脳・脳幹の神経回路網を修復し脳の可塑性を高めることで高次機能の革新的な回復をもたらすことを目的とした。さらに治療効果は独自に開発した海馬機能評価法（特願2014-074112）（添付資料参照）を応用して機能的な磁気共鳴画像（fMRI）を用いてリアルタイムにモニタリングした。

海馬機能評価法にて海馬新性能低下判明した場合は脳の可塑性を高める方法として安全性が高く汎用性、効果も高いtDCS(transcranial Direct current stimulation) (DC-STIMULATOR Plus;neuroConn) を用い安全性が確立している1日1回1mA, 30分間まで左側DLPFC(dorsolateral prefrontal cortex)を陽極刺激し右側側DLPFCに陰極電極を留置し1クール5回とし最大2クールまで施行した。

尚、海馬機能は機能的磁気共鳴画像（3T Discovery,GE社）による独自に開発したLure taskを用いて海馬パターン分離及びパターン補完を評価する事で神経新生能力を4段階で評価した。最も重症なのは神経新生能が途絶したGrade IIIで経頭蓋的電気刺激法や薬物による賦活治療の適応となる。これにより神経新生の促進が期待できる。Grade IIは神経新生能は途絶はしていないが機能低下が1ヶ月以上継続している患者で内服薬や経頭蓋的電

気刺激法の適応である。Grade Iは1ヶ月以内の最近の新生機能低下が示唆されライフスタイル等の改善で根本原因を除去するだけで回復が期待できる。Grade0は新生機能が正常範囲にあるタイプである。

本研究は患者の脳機能解析・神経心理解析に対して倫理を重んじ患者利益を損ない事の無いよう配慮を行なうとともに琉球大学倫理委員会の承認を受け、患者本人、およびその家族に対して十分な説明を行い書面にて同意を得ている。

C. 研究結果

本年度紹介された高次脳機能障害患者は28例です。その内訳は頭部外傷8例(42, 1%), 脳血管障害7例(36. 8%), 低酸素脳症2例(10. 5%), 蘇生後脳症2例(10. 5%)。神経心理学的検査の各domainの成績低下比率はpsychomotrspeed 28%, executive function 22%, memory 17%, working memory 14%, attention 11%, global cognitive function 8%でした。fMRI lure taskにて海馬歯状回機能を精査し5例において海馬新生機能が4症例で低下し新生能の完全途絶が推定されるgradeIII(重度障害)が1例, 1カ月以上の機能低下が示唆されるgradeII(中等度障害)が2例, 1カ月以内の機能低下が示唆されるgradeI(軽度障害)が1例であった。中等度以上の障害が示唆された3例にtDCSを施行し全例で海馬機能の改善が誘導でき海馬新生能を反映するlure正答率が正常域となった。GradeIIIの症例では神経心理検査の各domainの改善を認め特に言語性記憶の低下が重度であったがtDCS後に大幅な改善を認めた。またGrade II例で注意が逸れるとパフォーマンスが低下する注意のエアーパー

ケットが、治療後集中して課題に取り組み注意制御の改善が認められた。尚、治療に伴う有害事象は認めなかった。

D. 考察

利根川らは遺伝子改変動物を用いて嗅内野から海馬歯状回を通過する回路がパターン分離に、CA1への直接の入力およびCA3の反回神経回路がパターン補完に関与する事を報告している (Cell 2012) が、我々の研究はヒトにおいてパターン分離を促進することで高次脳機能の活性を高める手法（治療法）を探索しようとする試みである。パターン分離は歯状回新生ニューロン数が増えると改善する事が動物モデルでは確認されている。今回少数例の探索であるがヒトにおいて海馬歯状回部のシナプス機能の回復が高次脳機能障害の回復に本質的な役割を果たす可能性が示唆された。

E. 結論

海馬神経新生機能が低下した高次機能障害患者3名にtDCSにて左側DLPFCを陽極刺激で治療すると全例で海馬神経新生能の回復と高次脳機能の回復が得られた。

F. 健康危険情報

研究代表者、研究分担者等本研究事業に参画したものは特に研究環境の安全衛生面での問題はなかった。研究対象者に対しては検査時間の短縮に努め(概ね全検査時間は20分で5-7分の3回で途中適宜休憩を入れる)と同時にマイクロホンによる検査施行中の意思疎通に努め、予め承諾を得た上でのテレビカメラによるモニターを行い患者が安全に検査が受けられる環境の形成に努める配慮を行い有害事象の発生はない。

G. 研究発表

1. 論文発表

①Effect of caffeine contained in a cup of coffee on microvascular function in healthy subjects.

Noguchi K, Matsuzaki T, Sakanashi M, Hamadate N, Uchida T, Kina-Tanada M, Kubota H, Nakasone J, Sakanashi M, Ueda S, Masuzaki H, Ishiuchi S, Ohya Y, Tsutsui M.

J Pharmacol Sci. 2015 Feb;127(2):217-22.

②Progression of cerebellar chronic encapsulated expanding hematoma during late pregnancy after gamma knife radiosurgery for arteriovenous malformation.

Watanabe T, Nagamine H, Ishiuchi S. Surg Neurol Int. 2014 Dec 30;5(Suppl 16):S575-9.

③Identification of a novel cell-penetrating peptide targeting human glioblastoma cell lines as a cancer-homing transporter.

Higa M, Katagiri C, Shimizu-Okabe C, Tsumuraya T, Sunagawa M, Nakamura M, Ishiuchi S, Takayama C, Kondo E, Matsushita M.

Biochem Biophys Res Commun. 2015 Feb 6;457(2):206-12.

④Development of an experimentally useful model of acute myocardial infarction: 2/3 nephrectomized triple nitric oxide synthases-deficient mouse.

Uchida T, Furuno Y, Tanimoto A, Toyohira Y, Arakaki K, Kina-Tanada M, Kubota H, Sakanashi M, Matsuzaki T, Noguchi K, Nakasone J, Igarashi T, Ueno S, Matsushita M, Ishiuchi S, Masuzaki H,

Ohya Y, Yanagihara N, Shimokawa H,
Otsuji Y, Tamura M, Tsutsui M.

J Mol Cell Cardiol. 2014 Dec;77:29-41.

⑤ Usefulness of the apparent diffusion coefficient (ADC) for predicting the consistency of intracranial meningiomas.

Yogi A, Koga T, Azama K, Higa D, Ogawa K, Watanabe T, Ishiuchi S, Murayama S.

Clin Imaging. 2014 38:802-7.

⑥ Enhanced expression of proapoptotic and autophagic proteins involved in the cell death of glioblastoma induced by synthetic glycans.

Faried A, Arifin MZ, Ishiuchi S, Kuwano H, Yazawa S.

J Neurosurg. 2014 120:1298-308.

⑦ 神経膠芽腫に対するAktを標的とした分子標的療法 渡邊孝, 菅原健一, 長嶺英樹, 石内勝吾, 琉球医学会雑誌 33 (1~3) 1~8, 2014

2. 学会発表

① 石内勝吾、特別講演第16回、ブレインサイエンス研究会「分子を基盤とした神経機能と病態」、「神経幹細胞とグリオーマ遺伝子から疾患までの垂直的統合研究」、2014年6月28日、沖縄かりゆしアーバンリゾート・ナハ

② 石内勝吾、記念講演、脳科学に基づいた脳神経外科学の発展をめざして、Development of neurological surgery based on brain science一、群馬大学医学部脳神経外科同門会講演、2014年6月21日、マーキュリーホテル前橋

③ 石内勝吾、特別講演、脳科学に基づいた脳神経外科学の発展をめざして、第8回奈良脳腫瘍研究会、2014年10月3日、スイス南海大阪

④ 石内勝吾、シンポジウム「放射線神経生物学の夜明け」、「中枢神経系への放射線照射によって生じる高次機能障害の評価及びその予防

法」、第36回日本生物学的精神医学会第57回日本神経化学会合同年会、2014年9月30日、奈良県新公会堂

⑤ 石内勝吾、シンポジウム中枢神経系への放射線照射によって生じる高次機能障害の評価及び予防法、第73回日本脳神経外科学会学術総会、2014年10月10日、グランドプリンスホテル高輪

⑥ 菅原健一、金城雄生、小林繁貴、長嶺英樹、外間洋平、宮城智央、田村貴光、渡邊孝、石内勝吾、「先天性第XI因子欠損症を合併した中心前回膠芽腫の一例」、第32回日本脳腫瘍学会学術集会、2014年11月30日、シェラトン・グランデ・トーキョーベイ・ホテル（舞浜）

⑦ 宮城智央、小林繁貴、金城雄生、長嶺英樹、外間洋平、西村正彦、田村貴光、菅原健一、渡邊孝、石内勝吾、「3次元CG支援による脳神経外科」、第73回日本脳神経外科学会学術総会、2014年10月10日、グランドプリンスホテル高輪

⑧ Katagiri C, Matsushita M, Ishiuchi S. Hyperbaric oxygenation treatment improves radioresponse in glioblastoma xenograft mouse model. The 5th International Society of Radiation Neurobiology Conference, 2015

⑨ 田村貴光、神経線維腫症1型に合併した椎骨動静脈瘻の治療1例～再発なく長期経過良好な治療例～、第30回日本脳神経血管内治療学会学術総会、2014年12月、パシフィコ横浜

⑩ 田村貴光、Balloon occlusion test in carotid body tumors、第73回日本脳神経外科学会学術総会、2014年10月、グランドプリンスホテル高輪

⑪ 石内勝吾、公開シンポジウム-倫理が育む健康・福祉に貢献する研究-招待講演、Neurolog

ical surgery based on brain science 2014
年3月8日、OIST

Title Page

Cerebellar Contribution to Pattern Separation of Human Hippocampal Memory Circuits

Running title: Analysis of Cognitive Impairment and Benign Cerebellar Tumors

Authors: Ayano Shiroma,^{1#} Masahiko Nishimura,^{1#} Hideki Nagamine¹, Tomohisa Miyagi¹,
Yohei Hokama¹, Takashi Watanabe¹, Sadayuki Murayama², Masato Tsutsui,³ Daisuke
Tominaga,⁴ and Shogo Ishiuchi^{1#}

[#]equally contributed to this study.

Affiliations:

¹Department of Neurosurgery, Graduate School of Medicine, University of The Ryukyus,
Nakagami-gun, Okinawa 903-0215, Japan, ²Department of Radiology, Graduate School of
Medicine, University of The Ryukyus, Nakagami-gun, Okinawa 903-0215, Japan, ³Department
of Pharmacology, Graduate School of Medicine, University of The Ryukyus, Nakagami-gun,
Okinawa 903-0215, Japan, ⁴Okinawa Study Center, The Open university of Japan, 1 Senbru
Nishihara, Okinawa 903-0219, Japan.

Correspondence should be addressed to: Shogo Ishiuchi, MD, PhD

Department of Neurosurgery, Graduate School of Medicine, University of The Ryukyus, 207
Uehara, Nishihara-machi, Nakagami-gun, Okinawa 903-0215, Japan.

(Tel) Int+81-98-895-1171, (Fax) Int+81-98-895-1423

(E-mail) ishogo@med.u-ryukyu.ac.jp

Number of pages: 55

Number of figures: 8

Number of tables: 6

Number of words for Abstract: 174

Number of words for Introduction: 679

Number of words for Discussion: 2,021

Abstract

The cerebellum is a crucial structure for cognitive function as well as motor control. Benign brain tumors such as schwannomas, meningiomas, and epidermoids tend to occur in the cerebellopontine angle cisterns and may cause compression of the posterior lateral cerebellum near the superior posterior fissure, where the eloquent area for cognitive function was recently identified. The present study examined cognitive impairment in patients with benign cerebellar tumors before and after surgical intervention in order to clarify the functional implications of this region in humans. Patients with cerebellar tumors showed deficits in psychomotor speed and working memory compared with healthy controls. Moreover, these impairments were more pronounced in patients with right cerebellar tumors. Functional magnetic resonance imaging during performance of a lure task also demonstrated that cerebellar tumors affected pattern separation or the ability to distinguish similar experiences of episodic memory or events with discrete, non-overlapping representations, which is one of the important cognitive functions related to the hippocampus. The present findings indicate that compression of the human posterior lateral cerebellum affects hippocampal memory function.

Keywords: posterior lateral cerebellum, cognitive function, brain tumor, memory, hippocampus, fMRI

Introduction

Recent research has shown that the cerebellum plays an important role in cognitive and emotional functions as well as motor control [1-4]. Studies using functional magnetic resonance imaging (fMRI) have shown that the actual use of a tool (e.g., scissors) primarily activates the anterior cerebellum, whereas imaginary use of a tool activates the lateral posterior lobe of the cerebellum [5]. Skilled use of the tool after learning activates a specific area near the superior posterior fissure, indicating that the posterior cerebellum is essential for information processing, space representation, and some procedural memory [6, 7] and is dependent upon the sequential relationship between discrete elements, just as in the serial reaction task. However, the acquisition of other skills does not require the learning of sequences like prism adaptation, which can be acquired during short-term motor learning. Human studies have identified the important contribution of the cerebellum to higher cognitive functions, especially to episodic memory, working memory, and procedural memory [8-13]. Nonetheless, the relationship between the cerebellum and hippocampal circuits in memory systems has not been fully evaluated.

Benign cerebellar tumors are isolated focal lesions that are frequently localized in the cerebellopontine angle or around the superior posterior fissure and do not invade or destroy neural networks, unlike gliomas or vascular strokes. These tumors are essentially regional, thereby allowing a more discrete estimation of the functionality of a specific region through examination of whether the function lost before operation recovers after surgical treatment. However, although preservation of VIIth and VIIIth cranial nerve function is prioritized during neurosurgical treatment, the cognitive function of these patients has not been evaluated. We therefore analyzed the cognitive impairment of patients before and after surgical intervention in order to evaluate the functional involvement of the posterior lateral cerebellum near the superior

posterior fissure. We found that patients with right cerebellar tumors exhibited disturbances in psychomotor speed as examined by the Digit Symbol Test (DST), and working memory as examined by the Digit Span Test (DS) when compared with healthy controls. Nonetheless, the classical neuropsychological domain does not really have a distinct functional anatomy.

In the current study, we analyzed the distinct human cerebellar contribution to memory systems under whole brain network organization using the method of Global Brain Connectivity (GBC). Several past studies have indicated that cognition involves large-scale human brain systems with multiple interacting regions. We therefore tried to identify a prominent feature of this hub of human cognition using lure task-related and resting state functional MRI (rs-fMRI) data. We focused on the pattern separation ability that discriminates between similar experiences of episodic memory, a crucial component of the hippocampal memory circuit, and used functional MRI (fMRI) to investigate subjects performing an established lure task [14]. Interestingly, patients with cerebellar tumors selectively showed a decreased ability for pattern separation in the lure task. We first identified 9 regions related to pattern separation ability by imposing stringency criteria based on an activation map of lure task fMRI findings from normal volunteers. Blood-oxygen-level-dependent (BOLD) signals, which are one of the indices of hemodynamic responses to neural activity, were correlated to correct response rates in the lure task associated with the activity of the following four distinct regions: right and left cerebellar hemisphere (lobule VI/Crus I), left anterior mid-cingulate cortex (aMMC), and right hippocampal dentate gyrus (DG). We then tested whether these regions showed high GBC in the rest of the brain using rs- fMRI data. We found that GBC correlated to a correct response rate in the lure task was limited to three of these regions, excluding the left cerebellar lobule VI/Crus I. Finally, we ascertained that this correlation was altered in patients with right and left cerebellar

tumors as compared with normal healthy volunteers. We therefore hypothesized that the cerebellar contribution to pattern separation ability is dependent upon integration of the right cerebellar hemisphere (lobule VI/Crus I) associated with the left aMMC and right hippocampal DG. The pattern changes in the functional connectivity of patients with cerebellar tumors may indicate an important contribution of the human cerebellum to higher cognitive functions associated with hippocampal memory systems.

Materials and Methods

Subjects

Neuropsychological assessments were carried out on 28 patients with benign cerebellar tumors (mean age 50.9 ± 12.1 years; 11 males, 17 females), 17 with right cerebellar lesions (mean age 49.4 ± 13.6 years; 8 schwannomas, 8 meningiomas, and 1 epidermoid) and 11 with left cerebellar lesions (mean age 53.5 ± 8.3 years; 6 schwannomas, 2 meningiomas, 2 epidermoid, and 1 lipoma) (Table 1), as well as on a control group consisting of 23 healthy controls matched for age, sex, and years of education (mean age 53.4 ± 14.1 , range 21-72 years; 9 males, 14 females). Regarding clinical histories, one patient (R19) had previously undergone gamma knife radiosurgery, and two patients (L10 and L17) had recurrent tumors. Patients were excluded for the following reasons: age under 20 or over 78 years; lesions involving non-cerebellar cortical or subcortical regions; history of alcohol or drug abuse; or pre-existing psychiatric disease.

Neurological examinations of gait, kinetic function-arm, kinetic function-leg, speech, and eye movements were conducted based on the Brief Ataxia Rating Scale [15]. All patients showed normal performance except for two cases (R2 and R7) who walked almost naturally, but were unable to walk with their feet in the tandem position. The locations of the cerebellar tumors are

shown in Figure 1 and Table 2. Notably, the tumor compressed the posterior lateral cerebellum in all patients, especially lobule VI and Crus I (Figure 1 and Table 2). Lesion size was measured in milliliters on preoperative MRI, according to the formula; $a \times b \times c / 2$, where a and b indicate the longest crossed dimension of the horizontal plane, and c indicates the greatest length of the tumor in the coronal plane.

Informed consent and approval

All patients and control subjects provided written informed consent for this investigation. The study was approved by the ethical committee of the University of the Ryukyus.

Experimental design

In the preoperative stage, 28 patients with cerebellar lesions underwent neuropsychological assessments and 19 patients participated in the fMRI examination. The fMRI study was conducted once before surgical treatment. In the postoperative stage, 12 patients with right cerebellar tumors (mean age 45.0 ± 11.5 years, range 21–64 years; 3 males, 9 females) underwent follow-up neuropsychological assessments in order to examine whether surgical intervention had an effect on functional recovery. Detailed individual profiles are shown in Table 1.

Neuropsychological assessment

The battery consisted of the following tests: (I) mini-mental state examination (MMSE) [16] and modified MMSE (3MS) [17] for global cognitive screening, (II) Trail Making Test (TMT) [18] and Stroop test (ST) [18] for executive function, (III) Wechsler Adult Intelligence Scale-Revised

(WAIS-R) digit span subtest (DS) [19] for working memory, (IV) WAIS-R digit symbol test (DST) [19] for psychomotor speed, (V) partial WAIS-R block design subtest (fifth and ninth items) [19] and the cube-copying test for visuospatial ability. For quantitative assessment of constructional ability in the cube-copying test, the points of connection and plane-orientation errors were evaluated. A point of connection was defined as a point at which three lines met to form a vertex, hence subjects could score up to eight points, since eight points of connection are present in a cube. Each plane with two pairs of parallel lines was evaluated in terms of the number of lines and the extent to which they were parallel. No plane-error points were scored if the cube was copied accurately [20]. We selected brief neuropsychological tests that could be performed within one hour in order to reduce the burden on patients in the preoperative or postoperative therapeutic stage.

Event related fMRI study

Subjects

Twelve patients with right cerebellar tumors (mean age 46.9 ± 13.3 years, range 17–66 years; 3 males, 9 females), 7 patients with left cerebellar tumors (mean age 53.3 ± 10.1 years, range 38–69 years; 2 males, 5 females), and 30 normal healthy volunteers (mean age 24.0 ± 5.2 years, range 22–35 years; 21 males, 9 females) were enrolled in this study (Table 1). The normal healthy volunteers that participated in the fMRI study were different from those included in the neuropsychological analysis. None of these patients had any signs or history of neurological or psychological diseases. This study was approved by the ethical committee of the University of the Ryukyus with written informed consent obtained from all participants. Subjects were all

right-handed according to the Edinburgh Handedness Laterality Index, with a median score of 100 (range 80–100).

Experimental paradigm

The fMRI behavioral paradigm used was a rapid event-related fMRI design [14, 21, 22] based on an explicit 3-alternative forced choice task including novel (new), repeated (same), and lure (similar) stimuli consisting of color photographs of common objects. A fully randomized functional run consisted of 108 total trials, 16 lure sets, 16 repeat sets, and 44 unrelated novel items (foils) (Figure 2). Forty-four foil trials, 16 trials first presented from repeat sets, and 16 trials first presented from lure sets were presented as the new stimuli. The same stimuli were 16 trials, which are second presented from repeat sets. The lure stimuli were 16 trials which are second presented from similar sets. Each stimulus was presented for 2500 ms with a 0–1000 ms interstimulus interval to prevent adaptive stimulus responses. The number of trials separating similar and identical pairs was randomly varied from 10 to 40 trials. Several photographs were displayed to participants on a goggles display during the session. If the photograph was first presented in the session, participants were required to press the *red* button indicating a new object. If the photograph had been displayed before in the session, examinees were instructed to press the *blue* button indicating a repeated object. Finally, if they thought that the photograph was similar to, but not the same as previous stimuli, they were required to press the *green* button, indicating a similar but not identical object. Responses and reaction times were recorded in a button box (Current Designs, Inc., Philadelphia, Pennsylvania). Visual stimuli were presented to the subjects using 800 x 600 resolution magnet-compatible goggles under computer control

(Resonance Technologies, Inc., Salem, Massachusetts) using Presentation® software (Neurobehavioral Systems, Inc., Austin, Texas).

MRI data acquisitions

Anatomical and functional images were obtained using a 3-T MRI scanner (Discovery MR750; GE Medical System, Waukesha, Wisconsin) with a 32-channel head coil, and high-order manual shimming to the temporal lobes. The array spatial sensitivity encoding technique (a parallel imaging technique) was used to acquire imaging data by reducing geometric distortion for echo planar imaging (EPI). The anatomical three-dimensional (3D) spoiled gradient recalled echo (SPGR) sequence was obtained with a high-resolution 1-mm slice thickness (matrix size 256×256 , field of view 256×256 mm, repetition time 6.9 ms, echo time 3 ms, flip angle 15°). T2*-weighted EPI sequence was used to measure blood oxygenation level dependence (BOLD) contrast (repetition time 1500 ms, echo time 25 ms, flip angle 70° , matrix size 128×128 , field of view 192×192 , in-plane resolution 1.5×1.5 mm², 23 slices, 3-mm thickness, 0-mm space). A total of 303 volumes were collected over one session during the experiment in a sequential ascending order. A high-resolution T2 fast spin echo (T2 FSE) sequence (repetition time 4300 ms, echo time 92 ms, matrix size 512×512 , field of view 192×192 , in-plane resolution 0.375×0.375 mm², 23 slices, 3-mm thickness, 0-mm space) was obtained for the co-registration of 3D SPGR and EPI functional images. EPI functional images and T2 FSE structural images were acquired in an oblique coronal plane perpendicular to the long axis of the hippocampus. Almost the entire hippocampus (head, body, and tail) was included in the 23 slices. Functional images were localized in the sagittal plane of the SPGR image to identify the long axis of the hippocampus. Oblique coronal slices were fitted to the principal longitudinal axis of the

hippocampus covering the entire bilateral medial temporal lobes. Firstly, distortions of fMRI signals were corrected by array spatial sensitivity encoding techniques, which were used to improve temporal and spatial resolution and reduce artifacts. Secondly, higher-order shims were employed to directly compensate for local field distortions. These methods guaranteed homogeneity of the magnetic field.

Preprocessing and estimations

Functional and structural MR images of the brain were preprocessed using the methods of realignment, temporal correlation, spatial normalization, and spatial smoothing. The data were analyzed using SPM8 software (Wellcome Trust Centre for Neuroimaging, University College London, London, UK). The first 5 volumes in each data set were removed to ensure that the signal reached a steady state. EPI functional images were corrected to account for the differences in slice acquisition times by interpolating the voxel time series using sinc interpolation and resampling the time series using the center slice as the reference point. The EPI functional images were then corrected for motion artifacts by realignment to the first volume. A mean EPI functional image was constructed during realignment. Co-registration was performed through two processes. Both the mean EPI functional image and the motion-corrected EPI functional images were co-registered to the T2 FSE structural image. The co-registered T2 FSE structural image was then co-registered to the structural SPGR image. Next, the registration points of the anterior and posterior horns of the lateral ventricle, top surface of the paracentral lobule, and bottom surface of the inferior temporal gyrus were checked in the T2 FSE structural, structural SPGR, and EPI functional images. Before spatial normalization, a parameter was produced by the segmentation process from the structural SPGR image. The structural SPGR image and EPI

functional images were spatially normalized (1 x 1 x 1 mm) using the Montreal Neurological Institute space. Finally, the images were spatially smoothed using a Gaussian kernel with a full width at a half maximum of 3 mm. To detect the brain activation associated with a specific task while simultaneously reducing noise, the size of the smoothing kernel was kept at a recommended 2 to 3 times the voxel size [23]. A high-pass filter regressor (200 s) was included in the design matrix to exclude low-frequency noise and artifacts. To identify the correct activation spots of the brain, movement effects were discounted in a number of rows (298) and columns (3 translations and 3 rotations). For each subject, the three (new, lure, and repeated) regressors were estimated by a general linear model calculated by applying a canonical hemodynamic response function combined with time and dispersion derivatives. To assess the main effect of the lure images, as characterized by both the hemodynamic response function and these derivatives, an F-contrast obtained by the F-test was required. Intra-individual activation maps were calculated by F-tests. We calculated second-level group contrasts using a one-sample *t*-test for each regressor (new, lure, and same) from the response of the canonical hemodynamic function. Differences in the intensities of the activation between task conditions were confirmed by a voxel-level threshold of $p < 0.001$ uncorrected, and a cluster-level threshold of FWE (family-wise error)-corrected $p < 0.05$. We extracted the average percent signal change values of the ROIs (regions of interest) from the anatomically defined AAL ROI atlas [24] and established 3D MRI atlases [25-27] for each subject and type of task stimuli using the MarsBar toolbox [28].

Global Brain Connectivity analysis

Subjects

Twelve patients with right cerebellar tumors (mean age 46.9 ± 13.3 years, range 17–66 years; 3 males, 9 females), 7 patients with left cerebellar tumors (mean age 53.3 ± 10.1 years, range 38–69 years; 2 males, 5 females) and 15 right-handed healthy volunteers (mean age 27.6 ± 6.5 years, range 20–44 years; 5 males, 10 females) were enrolled in this study. The normal healthy volunteers participating in the resting-states fMRI study were different from those included in the neuropsychological analysis and the event-related fMRI experiment. No participants had any signs or history of neurological or psychological diseases. This research was approved by the ethical committee of the University of the Ryukyus and written informed consent was obtained from all participants.

Acquisition of resting-state fMRI data

Functional and anatomical images were obtained using a GE Discovery MR750 3.0 Tesla MRI scanner (GE Medical System, Waukesha, Wisconsin, USA) with a 32-channel head coil. In order to minimize head movement, the heads of each of the participants were fixed using foam pads. In order to reduce geometric distortion in echo planar imaging (EPI), a parallel imaging technique known as the array spatial sensitivity encoding technique was used during imaging data acquisition. T2*-weighted EPI images were used to measure BOLD contrast (repetition time 2000 ms, echo time 30 ms, flip angle 70° , matrix size 64×64 , field of view 256×256 , in-plane resolution $4 \text{ mm} \times 4 \text{ mm}$, 42 slices, 4-mm thickness, 0-mm space). During EPI image scanning, participants were instructed to remain motionless, remain awake, relax with their eyes closed, and to try not to think about anything in particular. A total of 150 volumes were collected over one session in a sequential ascending manner (plus 5 initial discarded volumes). An anatomical three-dimensional spoiled gradient recalled echo (3D SPGR) sequence was obtained with high-resolution 1-mm slice thickness (matrix size 256×256 , field of view $256 \times 256 \text{ mm}$,

repetition time 6.9 ms, echo time 3 ms, flip angle 15°). A high-resolution T2 fast spin echo (T2 FSE) sequence (repetition time 4300 ms, echo time 92 ms, matrix size 256 x 256, field of view 192 x 192, in-plane resolution 1.33 x 1.33 mm, 42 slices, 4-mm thickness, 0-mm space) was obtained for the co-registration of 3D SPGR images and EPI functional images. EPI functional and T2 FSE structural images were acquired in an oblique axial transverse plane (tilted 30° anterior relative to the intercommissural plane).

Preprocessing and analysis of resting-state fMRI data

Following this step, fMRI preprocessing, analysis, and visualization methods were conducted as implemented in SPM (8 package, <http://www.fil.ion.ucl.ac.uk/spm8/>) and the “conn” toolbox (www.nitrc.org/projects/conn). Images were corrected for slice acquisition time within each volume, motion corrected with realignment to the first volume, spatially normalized to the standard MNI EPI template, and spatially smoothed using a Gaussian kernel with a full width at half maximum of 8 mm. 3D SPGR images were co-registered with each mean EPI and T2 FSE image, and averaged together to permit anatomical localization of the functional connectivity at the group level. The transformed structural images were segmented into gray matter (GM), white matter (WM), and cerebrospinal fluid (CSF) using a unified segmentation algorithm.

In addition to removing noise correlations present in WM and CSF, the addition of 6 motion regressors (6 realignment parameters and first derivatives) controlled for correlations due to movement. Data were filtered between 0.009 and 0.08 Hz.

Correlation analysis with global brain connectivity and the lure task

A map of global brain connectivity (GBC) was computed from resting-state fMRI data using the “conn” toolbox (www.nitrc.org/projects/conn) [29, 30]. In the “conn” toolbox, correlation maps were calculated on the basis of seed-based correlation analysis using the AAL ROI atlas [24]. When the population correlation coefficient is zero, the distribution of correlation coefficient is consistent with the normal distribution. However, normal distribution of the correlation coefficient is lost when the correlation coefficient approximates to 1 [31]. Each ROI’s correlation coefficient map was transformed by Fisher’s Z-transformation to Z-value maps in order to normalize the correlation coefficient.

These Z-value maps were averaged together across each subject in order to calculate GBC values. For correlation analysis of the GBC and score of the lure task, GBC values were extracted from the ROIs that were activated by the lure stimulus in the event-related fMRI experiment. The Pearson product-moment correlation coefficient was used to calculate correlations between GBC values and the correct response rates in the lure task. When the correlation coefficient was close to +1, the *r*-value indicated a proportional connection between GBC values and the scores in the lure task (positive correlation). Conversely, when the correlation coefficient was close to -1, the *r*-value showed an inverse proportion (negative correlation). We estimated the strength of the correlation in 5 categories: negligible correlation (0.00 to 0.30 or 0.00 to -0.30), low correlation (0.30 to 0.50 or -0.30 to -0.50), moderate correlation (0.50 to 0.70 or -0.50 to -0.70), high correlation (0.70 to 0.90 or -0.70 to -0.90), and very high correlation (0.90 to 1.00 or -0.90 to -1.00) [32].

Statistical analysis

The Kruskal-Wallis test for three independent samples or the Mann-Whitney U test for two independent samples was used to evaluate statistical significance in the neuropsychological assessments and fMRI behavioral tasks, since a normally distributed population could not be assumed. Preoperative and postoperative neuropsychological data were compared using the Wilcoxon signed rank test. Statistical significance was accepted at $p < 0.05$. The chi-square test was used to evaluate the performance in the block design subtest, since only 2 items of the block design subtest were evaluated as pass/fail.

Results

Preoperative neuropsychological profile of patients with benign cerebellar tumors

The results of the neuropsychological test of DST ($p < 0.05$), forward span of DS ($p < 0.05$), backward span of DS ($p < 0.01$), and total score of DS ($p < 0.05$) among patients with cerebellar tumors ($n = 27$) indicated a significant impairment as compared with the control group, which was further confirmed using the Mann-Whitney U test. To examine whether the profile of the impairments depended on the side of the lesion, patients with right and left tumors were compared to the control group. Performance on neuropsychological tests including MMSE, DST, forward span of DS, backward span of DS, total score of DS, and cube copying test significantly differed across groups. Patients with right cerebellar tumors performed significantly worse than the control group on DST ($p < 0.001$), forward span of DS ($p < 0.010$), backward of DS ($p < 0.001$), and total score of DS ($p < 0.05$), as indicated by a Post hoc Mann-Whitney U test with Bonferroni correction (Table 3). In contrast, there were no significant impairments in left sided tumors as compared to the control group (Table 3). A Mann-Whitney U test was used to confirm that patients with right side tumors showed significantly lower scores on the MMSE when

compared with patients with left side tumors ($p < 0.05$) (Table 3). No direct relationship was found between tumor size and scores on neuropsychological assessments, with the exception of the DST ($r = -0.48$, $p < 0.05$). None of subjects failed the fifth item of block design test. Chi-square analysis of the performance of the ninth item on the block design subtest revealed no significant difference between patients with right or left cerebellar tumors and the control group.

Postoperative neuropsychological profile of patients with benign cerebellar tumors

Since most neuropsychological tests showed a significant decline in patients with right-sided as compared with the control group at the preoperative stage, twelve patients with right cerebellar tumors were further tested 2 weeks to 18 months after resection of the tumor in order to investigate whether cognitive function became normalized after surgical decompression of the posterior lateral cerebellum. T1-weighted MRI confirmed that the decompressed cerebellum, especially lobule VI and Crus I had completely recovered after treatment (Table 2 and Figure 3). Comparison of preoperative and postoperative neuropsychological tests revealed improvements in the raw scores of DST from 8.33 ± 3.20 to 8.92 ± 3.23 , DS forward span from 6.08 ± 1.16 to 6.25 ± 1.60 , DS backward span from 4.08 ± 0.90 to 4.58 ± 1.73 , and DS total score from 9.92 ± 3.06 to 10.83 ± 4.59 . However, no significant difference was found between neuropsychological assessments because of the small sample size (Table 4).

Hippocampal function

Analysis of the reaction times for new, lure, and repeated task revealed no significant difference across groups (Figure 4A, B, and C). However, a significant decline was observed in the correct response rates during lure tasks in patients with right cerebellar tumors ($13 \pm 18\%$; $n = 12$, age

53.4 ± 13.4 years) ($P = 0.0003$) compared with those of normal healthy volunteers (46.3 ± 3.3%; $n = 30$, age 24.0 ± 5.2 years). Furthermore, no difference was found between patients with right and left cerebellar tumors (30 ± 18%; $n = 7$, age 53.3 ± 10.1 years) ($P = 0.25$) (Figure 4D, E, and F).

BOLD responses

We confirmed the BOLD signal activity in the right DG but not left ones correlated to correct response rate of the lure task rather than error one, nor other new and similar ones in normal healthy volunteers. These results indicate a crucial contribution of right DG for the performance of pattern separation ability (Figure 5A and B). We therefore analyzed BOLD response patterns in the right DG during lure tasks. In normal healthy volunteers, the initial-dip in the BOLD response occurred at 1.7 ± 1.3 s (seconds) (mean ± S.D.) in time course, followed by a fractional increase in blood flow within 3.9 ± 4.2 s. The subsequent signal decrease was delayed by 8.3 ± 5.1 s, and the % BOLD change from that of the resting state was -0.19 ± 0.27 , followed by a slope to a plateau or peak value for long pulses (>20 s) (Table 5 and Figure 5C). Signal fluctuation or alteration of the BOLD pattern was found in patients with cerebellar tumors. A delayed latency of the initial positive peak (5.3 ± 1.9 s) with a large amplitude of % BOLD change (0.190 ± 0.060) subsequently followed by an initial dip (2.1 ± 0.9 s) was found in patients with right cerebellar tumors (Table 5 and Figure 5D). For patients with left cerebellar tumors, we found a rapid initial peak (3.3 ± 1.4 s) without an initial dip, followed by a slope to a plateau value with a large S.D. value ranging from -0.18 to 0.28 , indicating signal fluctuations among examinees of this group (Table 5 and Figure 5E).

Correlation analysis with brain activation and lure task

We began by detecting important regions for memory systems on the basis of the activation maps gathered from 30 healthy participants during the performance of a lure task involving pattern separation, which is an important human memory function of hippocampal circuits (Table 6). Next, we evaluated whether neural activity measured by local BOLD signal changes correlated to accurate response rates in the lure task across examinees, indicating a functional role of the regions instead of individual differences between examinees (Figure 6A- I). The source ROIs were defined as the right DG, left anterior middle cingulate cortex (aMCC), and bilateral cerebellar lobule VI including Crus I, based on the correlation analysis of BOLD responses and percentage of correct responses in the lure task (Figure 7A, C, and E). Correct identification of source ROIs was confirmed by established 3D MRI atlases (Figure 7B, D, and F) [24-27]. Subdivisions of the rostral cingulate cortex, hippocampus, and cerebellum were painted on an individual structural SPGR image using FSLview in the FMRIB Software Library v5.0 (FMRIB Analysis Group, University of Oxford, Oxford, UK). The parameters of the GBC were extracted from the source ROIs above.

Correlation with global brain connectivity (GBC) and pattern separation

For the GBC measure, we assessed standard resting-state fMRI data, and tested whether these regions had high GBC with the rest of the brain. The range of GBC values was from -2.1 to 1.9 in the normal control group, while patients with left and right cerebellar tumors showed more narrow ranges, from -0.09 to 0.07, and -0.07 to 0.11, respectively. The Pearson product-moment correlation coefficient was used to assess correlations between the GBC parameters of the four source ROIs and the percentage of correct responses in the lure task. The control subjects ($n =$

15) showed moderate positive correlations with the GBC of the right cerebellar lobule VI, including Crus I ($r = 0.65, p < 0.01$), right hippocampal DG ($r = 0.62, p < 0.01$), and left aMCC ($r = 0.56, p < 0.05$) (Figure 8A), though no significant correlation was found in the left cerebellar lobule VI including Crus I ($r = 0.0001, p > 0.05$). We found that GBC connectivity correlated to correct response rates during lure tasks was limited to three regions including the right cerebellar hemisphere (lobule VI/Crus I), left anterior mid-cingulate cortex (aMMC), and right hippocampal dentate gyrus (DG). Herein, we raised the hypothesis that these three regions might play a crucial role in the human memory system, since rs- fMRI connectivity not only correlated to established structural connectivity, but also reflected well-known functional networks [33, 34]. Thus, GBCs in the right cerebellar hemisphere (lobule VI/Crus I), left anterior mid-cingulate cortex (aMMC), and right hippocampal dentate gyrus (DG) were considered as the essential intrinsic connectivity of human cognition, statistically. In patients with left cerebellar tumors ($n = 7$), high positive correlations were found in the right cerebellar lobule VI including Crus I ($r = 0.76, p < 0.05$), right DG ($r = 0.72, p < 0.05$), and left aMCC ($r = 0.81, p < 0.01$) (Figure 8B), while the left cerebellar lobule VI including Crus I showed an extremely negative correlation ($r = -0.96, p < 0.001$). In patients with right cerebellar tumors ($n = 12$), significant alteration of correlations were found in the right cerebellar lobule VI including Crus I (moderate negative correlation; $r = -0.64, p < 0.05$) and left cerebellar lobule VI including Crus I (high negative correlation; $r = -0.74, p < 0.01$), but no correlation was found in the right DG ($r = -0.04, p > 0.05$) or aMCC ($r = -0.11, p > 0.05$) (Figure 8C). These results might collectively indicate an important cerebellar contribution to pattern separation.

Discussion

We examined functional involvement of the posterior lateral cerebellum and its functional relationships with the hippocampus and the prefrontal cortex including anterior mid-cingulate cortex. Previous studies have investigated patients with cerebellar lesions such as tumors, strokes, and degenerative diseases, which frequently damage normal brain tissues. Our study evaluated patients with benign cerebellar tumors, because these lesions do not extensively destroy the surrounding normal brain tissues, so that neuropsychological assessment before and after treatment could clarify the functional involvement of the decompressed area. Human cerebellar cognitive function has been extensively studied in relation to the prefrontal cerebral cortex, but few studies have evaluated the correlation between hippocampal function and the cerebellar neocortex. Therefore, the present study also analyzed the functional activity of the posterior lateral cerebellum in relation to the hippocampus and anterior mid-cingulate cortex.

Functional involvement of the posterior lateral cerebellum

To the best of our knowledge, the present study presents the first examination of the cognitive profiles of patients with benign cerebellar tumors that compress the posterior lateral cerebellum. Neuropsychological assessments indicated that patients with right cerebellar tumors showed impairments in working memory and psychomotor speed when compared with age-matched healthy controls. Patients with right cerebellar tumors also showed lower scores in MMSE than patients with left sided tumors. We tried to interpret these cognitive declines with the view that the cerebellum contributes to intrinsic functional connectivity. The laterality and disease dominancy of cerebellar tumors may therefore be important. With regard to crossed cerebello-cerebral connections, patients with right-sided cerebellar lesion showed impairments in

verbal tasks, whereas patients with left sided tumors showed deficits in spatial tasks [35, 36]. Several studies have suggested a similar laterality in cognitive symptoms [37-39], and imaging studies have elucidated cerebellar topography and lateralization effects [40, 41]. Imaging studies [40, 41] have shown that activation peaks in language tasks were lateralized to the right lobule VI and lobule VII. In contrast, spatial processing showed greater left hemisphere activation, predominantly in lobule VI [40] and lobule VII [41]. Consistent with these imaging and clinical findings, Wang et al. [42, 43] reported cerebellar symmetry in relation to cerebral intrinsic functional connectivity. They indicated a right-lateralized cerebellar network including crus I/II and a portion of lobule VI, which couples to a left-lateralized cerebral network involving the inferior frontal gyrus, superior temporal gyrus, and temporal pole in the cerebral cortex. These regions include traditional language areas in the cerebral cortex, such that the cerebellar regions are commonly activated by language-related tasks. In our study, patients with right cerebellar tumors showed lower scores on the MMSE than patients with left side tumors. Language processing is the main cognitive demand of the MMSE. Compression of the portions of the right lobule VI and Crus I connected with language areas alters the right- lateralized cerebellar network that supports language processing, which may lead to MMSE scores in patients with right cerebellar tumors. In the working memory test, lesion studies revealed that the inferior cerebellum was associated with performance on digit span test [13, 44]. There are laterality differences within the inferior lobe of cerebellum. The left inferior lobe of cerebellum is associated with the processing of aural information, whereas the right inferior lobe is involved in visual information [12]. Damage to left inferior cerebellar lobule VIII has been shown to reduce auditory digit span [44]. However, Ravizza et al. [13] revealed that performance on the auditory digit span test was unaffected by laterality of the damaged cerebellar hemisphere. Inconsistent

with previous studies, the present study shows that patients with right-sided tumors exhibited impairment in the performance of the digit span test when compared with normal healthy volunteers. Chen and Desmond [11] hypothesized two cerebro-cerebellar networks for verbal working memory: the frontal/superior cerebellar network involving the right cerebellar lobule VI, Crus I, and Broca's area, which is associated with articulatory rehearsal; and the parietal/inferior cerebellar network involving the right cerebellar lobule VIIB and inferior parietal lobe, which is related to maintenance/storage of information. In the present study, impairment on working memory in patients with right-sided tumors might be related to some change in the neural bases for processing verbal working memory caused by tumor compression in the right superior and inferior cerebellum. We also found that psychomotor speed was disturbed in patients with right cerebellar tumors compared with control subjects. DST is a psychomotor performance test thought to be affected various cognitive demands, such as motor skill, attention, and visuomotor coordination [18]. Fronto-parietal cortical networks are related to performance on the DST, and these activations reflect the processes of visual searching and updating of working memory [45]. Since patients with right cerebellar tumors also exhibited impairment of working memory, the intrinsic functional connectivity between the left fronto-parietal network coupled with the right cerebellar hemisphere might be altered by compression. We suspected that the cognitive impairments of patients with right cerebellar tumors were related to alteration of cerebellar contributions to intrinsic functional connectivity.

We found an improvement in the raw scores of some of the neuropsychological tests after surgical intervention associated with anatomical normalization of the lateral posterior cerebellum. At the postoperative stage of neuropsychological estimation, some patients with no improvements in psychomotor speed showed transient neurological symptoms related to IVth or

Vith cranial nerve function. Double vision might be a factor in preventing optimal performance. However, follow-up neuropsychological assessments in patients with cerebellar lesions have been limited [39, 46]. Previous findings suggest that the cerebellum can recover from pathological insult by changing the relationships of cerebral connectivity. Further studies are required to identify the detailed mechanisms behind the restoration of cognitive function following treatment of cerebellar lesions.

Hippocampal memory function in patients with cerebellar tumors

The involvement of the cerebellum in non-declarative memory has been previously investigated. Patients with focal cerebellar lesions showed impaired motor sequencing [10]. Such investigations provide evidence for a cerebellar contribution to procedural learning, and support the idea that the cerebellum is an important anatomical component for competent skill acquisition. However, it is still unclear whether cerebellar lesions influence hippocampal episodic memory. On the other hand, the role of the hippocampus in episodic memory has been extensively studied, and the DG subregion of the hippocampus is well known as a substrate for cognition [47].

Pattern separation is a function of the DG that transforms similar experiences or events into discrete, non-overlapping representations. The DG and its projections into the CA3 subregion have been shown to be involved in pattern separation [14]. fMRI was used to observe the process of pattern separation by scanning normal subjects during an incidental encoding task using pictures of common objects. The present fMRI study used a similar experimental paradigm to examine hippocampal memory function involvement in pattern separation in patients with cerebellar tumors. The BOLD response showed that the latency of the positive peak was

significantly increased in patients with right cerebellar tumors, and these patients showed increases in the positive peak without any second negative peak. Logotheis et al. [48] reported a linear relationship between BOLD signals and neural activity. In addition, the BOLD signal was shown to represent the proportion of the cerebral metabolic rate of oxygen (CMRO₂) to cerebral blood flow (CBF) [49]. The factor of gain in the positive response was interpreted as either a reduction in CBF or an increase in CMRO₂ [50]. Increases in BOLD responses are influenced by hemodynamics and metabolism based on the magnitude of neural response. However, the factor that exerts influence on the increase in positive BOLD responses has not yet been elucidated. Moreover, the physiological significance of the post-stimulus undershoot was interpreted as a normal decline to the resting state of neural activity [48, 51], and reductions in the second negative peak may reflect alteration of the neural responses in patients with right cerebellar tumors. The pattern of averaged BOLD responses did not illustrate the initial dip and post-stimulus undershoot in patients with left cerebellar tumors, which may have been masked by the initial dip and post-stimulus undershoot such that it could not be recognized by means of the extended standard deviation of BOLD responses. These results indicate fluctuations in the large BOLD signals in patients with left cerebellar tumors, though there was not much of a difference between patients with left and right tumors in the size of the lesion and the compressed portion of cerebellum. Further studies are required to examine the causal mechanism of fluctuation in the BOLD signals of patients with left cerebellar tumors.

These findings suggest that the cells surrounding a metabolic disturbance area may have provided appropriate assistance to the hippocampal circuitry. The assessment of hippocampal memory function indicated that patients with cerebellar tumors showed selective inability in a lure task, which reflects pattern separation inability and disturbance of the generating activity of

young granule cells in the DG of the hippocampus. This inability was found in patients with both right and left cerebellar tumors, although performances in the other two tasks (new and same) were equal to those of normal healthy volunteers. Taken together, these findings indicate that the selective inability in the lure task was caused by cognitive dysfunction and not by motor impairment in patients with cerebellar tumors. Instead, cerebellar damage seems to affect hippocampal DG functions.

Influence on patterns separation function by global brain connectivity of posterior lateral cerebellum

The fMRI examination of cognitive processing observed cerebellar activity in the convergent area of the posterior lateral lobe, which also regulates smooth motor control. Activations of posterior lateral cerebellum were previously proposed as the internal model for new tools [7]. Our present GBC study demonstrated that the value was altered in patients with cerebellar tumors compared with the normal control group. Interestingly, the left and right values of patients with cerebellar tumors converged on a narrow window. It was reported that cerebellum, cingulate cortex, and hippocampus have high GBC values that are included in the top 10% of GBC [29]. High GBC areas have more connectivity with cortical and subcortical regions [29]. The GBC values that were restricted within the narrow window may represent a reduction in connectivity induced by lesions to the posterior lateral cerebellum.

Our present study also showed that the right cerebellar lobule VI/Curs I, right DG, and left aMCC are important regions for pattern separation. In particular, patients with right cerebellar tumors showed a disruption in the correlation of GBC to these areas associated with pattern separation function. High GBC areas are believed to integrate cortical and subcortical activity

and act as global hubs influencing cognitive control [29, 30]. According to resting state fMRI analysis, it was reported that the posterior cerebellum has a functional connection with the prefrontal cortex, involving the anterior cingulate cortex for cognitive functions [8, 9]. Reduction in the GBC of patients with right cerebellar tumors not only elicited functional dissociation of the right and left lobule VI/Curs I from pattern separation ability, but also affected the anterior mid-cingulate cortex, and hippocampus. In light of these observations, global connectivity of the right posterior lateral cerebellum may play an important role in pattern separation as well as cognitive functions.

Interaction between the hippocampus and cerebellum occurs in the spatial domain [52]. Cerebellar impairment leads to dysfunction of the spatial cord as recorded by place cells in the CA1 hippocampus using L7-PKCI mice in which protein kinase C-dependent long-term depression at the parallel fiber-Purkinje cell synapses is blocked. Consequently, the cerebellum assists navigation by participating in the building of the hippocampal spatial map. Hippocampal-cerebellar interactions occur during spatio-temporal prediction [53]. Patients with right cerebellar tumors showed a high rate of error in the lure task, as was indicated by fMRI. Just as the cerebellum contributes to the fine tuning of coordination in skilled motor sequences in motor control, it also contributes to cognition by facilitating the precise discrimination of overlapping or similar experiences among episodic memories. Newly generated young neurons have been shown to facilitate pattern separation in the hippocampus [47]. Whether cognitive decline and disability in pattern separation in patients with cerebellar disease only reflect functional changes in new neurons or are instead associated with a decrease in hippocampal neurogenesis is an interesting question that requires further investigation.

Conclusions

The present findings show that compression of the posterior lateral cerebellum causes impairment of cognitive function. Surgical decompression of the cerebellum facilitated cognitive recovery. The fMRI study demonstrated global connectivity between the Crus I, aMCC, and hippocampus during analysis of hippocampal memory function. The posterior lateral cerebellum acts as a global hub, cooperating with the hippocampus and anterior mid-cingulate cortex to facilitate pattern separation ability.

Acknowledgements

This work was supported by Industrial Disease Clinical Research Grants by the Ministry of Health, Labour and Welfare (to S.I, T.W., Y.H. & M.N.), and Special Account Budget for Education and Research (to S.I. & M.T.), Grants-in-Aid for Scientific Research (B) (23390352) (to S.I.), and Challenging Exploratory Research (24650168) (to S.I.) by the Ministry of Education, Culture, Sports, Science and Technology in Japan, and the Princess Takamatsu Cancer Fund (to S.I.), and the Grants for Takeda Science Foundation (to M.T. & S.I.).

Conflict of Interest

The authors declare that they have no conflict of interest.

Author contributions: A.S. and M.N. prepared the manuscript, A.S. and D.T. performed neuropsychological analysis, M.N. & S.M. analyzed fMRI data, H.N., T.M., Y.H. & T.W. for clinical management, and S.I. designed and administered this study and wrote the manuscript. All authors edited the manuscript.

References

1. Manto M, Bower JM, Conforto AB, Delgado-García JM, da Guarda SN, Gerwig M, et al. Consensus paper: roles of the cerebellum in motor control-the diversity of ideas on cerebellar involvement in movement. *Cerebellum* 2012;11:457–87.
2. Grimaldi G, Manto M. Topography of cerebellar deficits in humans. *Cerebellum* 2012;11:336–51.
3. Riva D, Annunziata S, Contarino V, Erbetta A, Aquino D, Bulgheroni S. Gray matter reduction in the vermis and CRUS-II is associated with social and interaction deficits in low-functioning children with autistic spectrum disorders: a VBM-DARTEL Study. *Cerebellum* 2013;12:676–85.
4. Koziol LF, Budding D, Andreasen N, D'Arrigo S, Bulgheroni S, Imamizu H, et al. Consensus paper: the cerebellum's role in movement and cognition. *Cerebellum* 2014;13:151–77.
5. Koziol LF, Budding DE, Chidekel D. From movement to thought: executive function, embodied cognition, and the cerebellum. *Cerebellum* 2012;11:505–25.
6. Schmahmann JD, Sherman JC. The cerebellar cognitive affective syndrome. *Brain* 1998;121(4):561–79.
7. Imamizu H, Miyauchi S, Tamada T, Sasaki Y, Takino R, Pütz B, et al. Human cerebellar activity reflecting an acquired internal model of a new tool. *Nature* 2000;403:192–5.
8. Habas C, Kamdar N, Nguyen D, Prater K, Beckmann CF, Menon V, et al. Distinct cerebellar contributions to intrinsic connectivity networks. *J Neurosci* 2009;29:8586–94.
9. Krienen FM, Buckner RL. Segregated fronto-cerebellar circuits revealed by intrinsic functional connectivity. *Cereb Cortex* 2009;19:2485–97.

10. Molinari M, Leggio MG, Solida A, Ciorra R, Misciagna S, Silveri MC, et al. Cerebellum and procedural learning: evidence from focal cerebellar lesions. *Brain* 1997;120(Pt 10):1753–62.
11. Chen SH, Desmond JE. Cerebrocerebellar networks during articulatory rehearsal and verbal working memory tasks. *Neuroimage* 2005;24:332–8.
12. Marvel CL, Desmond JE. Functional topography of the cerebellum in verbal working memory. *Neuropsychol Rev* 2010;20:271–9.
13. Ravizza SM, McCormick CA, Schlerf JE, Justus T, Ivry RB, Fiez JA. Cerebellar damage produces selective deficits in verbal working memory. *Brain* 2006;129:306–20.
14. Bakker A, Kirwan CB, Miller M, Stark CE. Pattern separation in the human hippocampal CA3 and dentate gyrus. *Science* 2008;319:1640–2.
15. Schmahmann JD, Gardner R, MacMore J, Vangel MG. Development of a brief ataxia rating scale (BARS) based on a modified form of the ICARS. *Mov Disord* 2009;24:1820–8.
16. Folstein MF, Folstein SE, McHugh PR. "Mini-mental state". A practical method for grading the cognitive state of patients for the clinician. *J Psychiatr Res* 1975;12:189–98.
17. Teng EL, Chui HC. The Modified Mini-Mental State (3MS) examination. *J Clin Psychiatry* 1987;48:314–8.
18. Lezak MD, Howieson DB, Loring DW. Orientation and attention. In: *Neuropsychological assessment* 4th ed. New York: Oxford University Press; 2004 pp. 365–8, 371–4.
19. Wechsler, D. *Manual for the Wechsler Adult Intelligence Scale-Revised*. New York: Psychological Corporation; 1981.
20. Maeshima S, Osawa A, Maeshima E, Shimamoto Y, Sekiguchi E, Kakishita K, et al. Usefulness of a cube-copying test in outpatients with dementia. *Brain Inj* 2004;18:889–98.

21. Burock MA, Buckner RL, Woldorff MG, Rosen BR, Dale AM. Randomized event-related experimental designs allow for extremely rapid presentation rates using functional MRI. *Neuroreport* 1998;9:3735–9.
22. Yassa MA, Stark SM, Bakker A, Albert MS, Gallagher M, Stark CE. High-resolution structural and functional MRI of hippocampal CA3 and dentate gyrus in patients with amnesic Mild Cognitive Impairment. *Neuroimage* 2010;51:1242–52.
23. Friston KJ, Holmes AP, Poline JB, Grasby PJ, Williams SC, Frackowiak RS, et al. Analysis of fMRI time-series revisited. *Neuroimage* 1995;2:45–53.
24. Tzourio-Mazoyer N, Landeau B, Papathanassiou D, Crivello F, Etard O, Delcroix N, et al. Automated anatomical labeling of activations in SPM using a macroscopic anatomical parcellation of the MNI MRI single-subject brain. *Neuroimage* 2002;15:273–89.
25. Schmahmann JD, Doyon J, McDonald D, Holmes C, Lavoie K, Hurwitz AS, et al. Three-dimensional MRI atlas of the human cerebellum in proportional stereotaxic space. *Neuroimage* 1999;10:233–60.
26. Duvernoy HM. *The Human Hippocampus: Functional Anatomy, Vascularization and Serial Sections with MRI*. Berlin: Springer Verlag; 2005.
27. Vogt BA, editor. *Cingulate neurobiology and disease*. NY: Oxford University Press; 2009.
28. Matthew Brett, Jean-Luc Anton, Romain Valabregue, Jean-Baptiste Poline. Region of interest analysis using an SPM toolbox [abstract] Presented at the 8th International Conference on Functional Mapping of the Human Brain, June 2-6, 2002, Sendai, Japan. Available on CD-ROM in *NeuroImage*, Vol 16, No 2.
29. Cole MW, Pathak S, Schneider W. Identifying the brain's most globally connected regions. *Neuroimage* 2010;49:3132–48.

30. Cole MW, Yarkoni T, Repovs G, Anticevic A, Braver TS. Global connectivity of prefrontal cortex predicts cognitive control and intelligence. *J Neurosci* 2012;32:8988–99.
31. Fisher R. A. Frequency distribution of the values of the correlation coefficient in samples from an indefinitely large population. *Biometrika* 1915;10:507–21.
32. Mukaka MM. Statistics corner: A guide to appropriate use of correlation coefficient in medical research. *Malawi Med J* 2012;24:69–71.
33. Honey CJ et al. Predicting human resting-state functional connectivity from structural connectivity. *Proc Natl Acad Sci USA* 2009;106:2035–40.
34. Smith SM et al. Correspondence of the brain's functional architecture during activation and rest. *Proc Natl Acad Sci USA* 2009;106:13040–45.
35. Riva D, Giorgi C. The cerebellum contributes to higher functions during development: evidence from a series of children surgically treated for posterior fossa tumours. *Brain* 2000;123:1051–61.
36. Baillieux H, De Smet HJ, Dobbeleir A, Paquier PF, De Deyn PP, Mariën P. Cognitive and affective disturbances following focal cerebellar damage in adults: a neuropsychological and SPECT study. *Cortex* 2010;46:869–79.
37. Gottwald B, Mihajlovic Z, Wilde B, Mehdorn HM. Does the cerebellum contribute to specific aspects of attention? *Neuropsychologia* 2003;41:1452–60.
38. Gottwald B, Wilde B, Mihajlovic Z, Mehdorn HM. Evidence for distinct cognitive deficits after focal cerebellar lesions. *J Neurol Neurosurg Psychiatry* 2004;75:1524–31.
39. Hokkanen LS, Kauranen V, Roine RO, Salonen O, Kotila M. Subtle cognitive deficits after cerebellar infarcts. *Eur J Neurol* 2006;13:161–70.

40. Stoodley CJ, Schmahmann JD. Functional topography in the human cerebellum: a meta-analysis of neuroimaging studies. *Neuroimage* 2009;44:489–501.
41. Stoodley CJ, Valera EM, Schmahmann JD. Functional topography of the cerebellum for motor and cognitive tasks: an fMRI study. *Neuroimage* 2012;59:1560–70.
42. Wang D, Buckner RL, Liu H. Cerebellar asymmetry and its relation to cerebral asymmetry estimated by intrinsic functional connectivity. *J Neurophysiol* 2013;109:46–57.
43. Wang D, Buckner RL, Liu H. Functional specialization in the human brain estimated by intrinsic hemispheric interaction. *J Neurosci* 2014;34:12341–52.
44. Kirschen MP et al. Verbal memory impairments in children after cerebellar tumor resection. *Behav Neurol* 2008;20:39–53.
45. Usui N et al. Cortical areas related to performance of WAIS Digit Symbol Test: a functional imaging study. *Neurosci Lett* 2009;463:1–5.
46. Neau JP, Arroyo-Anllo E, Bonnaud V, Ingrand P, Gil R. Neuropsychological disturbances in cerebellar infarcts. *Acta Neurol Scand* 2000;102:363–70.
47. Nakashiba T, Cushman JD, Pelkey KA, Renaudineau S, Buhl DL, McHugh TJ, et al. Young dentate granule cells mediate pattern separation, whereas old granule cells facilitate pattern completion. *Cell* 2012;149:188–201.
48. Logothetis NK, Pauls J, Augath M, Trinath T, Oeltermann A. Neurophysiological investigation of the basis of the fMRI signal. *Nature* 2001;412:150–7.
49. Schridde U, Khubchandani M, Motelow JE, Sangahalli BG, Hyder F, Blumenfeld H. Negative BOLD with large increases in neuronal activity. *Cereb Cortex* 2008;18:1814–27.
50. Hu X, Yacoub E. The story of the initial dip in fMRI. *Neuroimage* 2012;62:1103–8.

51. Shmuel A, Augath M, Oeltermann A, Logothetis NK. Negative functional MRI response correlates with decreases in neuronal activity in monkey visual area V1. *Nat Neurosci* 2006;9:569–77.
52. Rochefort C, Arabo A, André M, Poucet B, Save E, Rondi-Reig L. Cerebellum shapes hippocampal spatial code. *Science* 2011;334:385–9.
53. Onuki Y, Van Someren EJ, De Zeeuw CI, Van der Werf YD. Hippocampal-Cerebellar Interaction During Spatio-Temporal Prediction. *Cereb Cortex* 2015;25(2):313–21.

Table 1. Summary of 28 patients examined by neuropsychological assessment

Patient number	Sex/Age/ Handedness	Diagnosis	Lesion side	Size of lesion (mL)	Follow-up assessment	fMRI study (preop)
R1	F/38/right	meningioma	right	3.41		
R2	M/21/right	schwannoma	right	50.56	+	
R6	M/61/right	schwannoma	right	0.27	+	
R7	F/42/right	schwannoma	right	18.31	+	+
R10	F/51/right	meningioma	right	6.55	+	+
R11	M/64/right	epidermoid	right	2.66	+	+
R12	F/34/right	meningioma	right	3.46	+	+
R13	F/52/right	meningioma	right	5.85	+	
R14	M/63/right	schwannoma	right	7.95		+
R15	M/76/right	schwannoma	right	5.79		
R16	F/50/right	meningioma	right	5.79	+	+
R17	M/49/right	schwannoma	right	3.68	+	+
R18	F/40/right	schwannoma	right	11.7	+	+
R19	M/60/right	schwannoma	right	5.22		+
R20	F/40/right	meningioma	right	0.42	+	+
R21	F/36/right	meningioma	right	7.71	+	+
R22	F/63/right	meningioma	right	13.51		+
L2	M/49/right	meningioma	left	3.82		
L4	F/48/right	schwannoma	left	27.34		+
L9	F/55/right	schwannoma	left	3.18		
L10	F/47/right	schwannoma	left	4.69		+
L11	F/69/right	meningioma	left	5.68		+
L12	F/59/right	epidermoid	left	3.97		
L13	M/53/right	Lipoma	left	0.79		+
L14	M/38/left	schwannoma	left	25.94		
L15	F/62/right	schwannoma	left	0.25		+
L16	M/55/right	epidermoid	left	13.55		+
L17	F/38/right	schwannoma	left	16.89		+

+ indicates participation in the follow-up assessment or fMRI study. Male (M); female (F).

Table 2. Lesion characteristics in patients with cerebellar tumors

Case code	Hemisphere											
	I	II	III	IV	V	VI	Crus I	Crus II	VII B	VIII	IX	X
Right side												
R1							×	×				
R2			×	×	×	×	×	×	×	×	×	×
R6												×
R7			×	×	×	×	×	×		×	×	×
R10						×	×	×	×	×		
R11				×	×	×	×	×	×	×		
R12						×	×	×	×	×		×
R13							×	×	×	×		
R14			×	×	×	×				×	×	×
R15				×	×	×						×
R16			×	×	×	×	×	×	×	×		×
R17			×	×	×	×				×		×
R18						×	×			×	×	×
R19				×	×	×	×	×	×	×	×	×
R20						×	×		×			
R21				×	×	×	×	×	×			×
R22			×	×	×	×	×		×	×		×
Left side												
L2			×	×	×	×						×
L4			×	×	×	×	×	×	×	×	×	×
L9						×				×		×
L10				×	×	×	×		×	×		×
L11				×	×	×	×	×	×	×		×
L12				×	×	×	×	×	×	×		×
L13												×
L14			×	×	×	×	×	×	×	×		×
L15												×
L16			×	×	×	×						×
L17			×	×	×	×						×


× denotes the existence of a tumor at preoperative stage.  indicates the residue at postoperative stage.

Table 3. Results of neuropsychological assessment of patients with damage to the right or left cerebellar hemispheres

Test	Cerebellar lesion		Controls, n = 23	<i>P</i>
	Right, n = 17	Left, n = 11		
Age, yrs	49.41 (13.99)	52.09 (9.48)	53.39 (14.05)	n.s
Education, yrs	13.29 (1.90)	12.82 (2.04)	12.91(2.39)	n.s
Cerebellar lesion size, mL	8.99 (11.66)	9.65 (9.86)	—	n.s.
3MS	96.18 (4.37)	97.59 (2.52)	97.50(2.14)	n.s.
MMSE	28.53 (2.00) †	29.73 (0.90)	29.13(1.26)	0.034
WAIS-R Digit symbol test #	8.65 (3.57)*	11.64 (3.38)	12.04 (2.44)	0.015
WAIS-R Digit span test				
Forward span	5.88 (1.05)*	6.45 (1.13)	6.86 (1.39)	0.025
Backward span	4.12 (0.86)*	4.64 (1.29)	5.43 (1.31)	0.006
Total score #	10.06 (2.70)*	11.55 (2.30)	12.08 (2.82)	0.048
TMT, sec				
Part A	36.94 (11.94)	34.82 (11.16)	30.74 (8.59)	n.s
Part B	64.82 (22.74)	64.00 (26.20)	52.52 (19.61)	n.s
Part B-A	27.88 (13.61)	29.18 (19.41)	21.78 (14.20)	n.s
Stroop test, sec				
Reading (I)	24.94 (4.70)	22.00 (4.38)	22.78 (4.19)	n.s
Naming (II)	33.24 (6.89)	30.64 (5.28)	30.35 (6.59)	n.s
Interference (III)	58.41 (22.61)	48.09 (15.27)	48.04 (13.62)	n.s.
III-II	25.18 (18.46)	17.45 (12.19)	17.70 (8.19)	n.s.
Cube-copying test				
Point of connection	7.00 (1.97)	7.45 (1.04)	8.00	0.011
Plane-drawing errors	0.41 (1.00)	0.45 (0.82)	0	n.s

Values are mean (standard deviation).

denotes scaled score (mean = 10, standard deviation = 3).

n.s. denotes not significant; *P* indicates a significant difference after Kruskal-Wallis test or

Mann-Whitney U test; * indicates a significant decline compared to controls (post hoc

Mann-Whitney U test with Bonferroni correction, $p < 0.05$); † denotes a significant decline compared to patients with left lesions (post hoc Mann-Whitney U test with Bonferroni correction, $p < 0.05$). 3MS indicates modified mini-mental state examination; MMSE, mini-mental state examination; TMT, Trail Making Test.

Table 4. Neuropsychological assessment of 12 patients with right cerebellar tumors at the preoperative stage and postoperative stage

Test	Preoperative assessment	Postoperative assessment	<i>P</i>
3MS	96.28 (4.99)	97.88(2.59)	n.s.
MMSE	29.17 (1.11)	29.25(1.76)	n.s.
WAIS-R Digit symbol test [#]	8.33(3.20)	8.92 (3.23)	n.s.
WAIS-R Digit span test			
Forward span	6.08 (1.16)	6.25 (1.60)	n.s.
Backward span	4.08 (0.90)	4.58 (1.73)	n.s.
Total score [#]	9.92 (3.06)	10.83 (4.59)	n.s.
TMT, sec			
Part A	33.58 (10.74)	36.50 (17.20)	n.s.
Part B	59.50 (23.33)	59.92 (23.91)	n.s.
Part B-A	25.92 (13.85)	23.42 (11.75)	n.s.
Stroop test, sec			
Reading (I)	24.75(2.30)	25.17 (3.79)	n.s.
Naming (II)	32.42 (4.64)	33.83 (7.76)	n.s.
Interference (III)	52.58 (18.92)	49.25 (14.64)	n.s.
III-II	20.17 (16.08)	15.42 (9.24)	n.s.
Cube-copying test			
Point of connection	7.33 (1.79)	7.92 (0.29)	n.s.
Plane-drawing errors	0.33 (0.89)	0	n.s.

Values are mean (standard deviation).

[#] denotes a scaled score (mean = 10, standard deviation = 3).

n.s. denotes not significant after a Wilcoxon signed rank test.

Table 5. Latency and amplitude of BOLD in the lure task in normal healthy subjects and patients with cerebellar tumors

Peak	Mean latency (second)			Mean (SD) amplitude (% BOLD change)		
	Normal (n = 30)	RC (n = 12)	LC (n = 7)	Normal (n = 30)	RC (n = 12)	LC (n = 7)
N1	1.7 (1.3)	2.1 (0.9)	0.2 (1.1)	- 0.039 (0.165)	- 0.074 (0.070)	0.000 (0.000)
N2	8.3 (5.1)	none	none	- 0.191 (0.272)	none	None
P1	3.9 (4.2)	5.3 (1.9)	3.3 (1.4)	0.074 (0.292)	0.190 (0.060)	0.140 (0.140)

RC indicates patients with right cerebellar tumors; LC, patients with left cerebellar tumors. The

first negative peak is defined as N1, second negative peak as N2, and first positive peak as P1.

None indicates the absence of a peak.

Table 6. Significant whole-brain activations for the lure task

Region	Cluster size	Peak of T-value	Peak coordinates		
			x	y	z
Rt. cerebellar lobule VI/Crus I	10064	13.18	-32	-47	-33
Lt. cerebellar lobule VI/Crus I	8572	12.96	35	-54	-22
Lt. lateral prefrontal cortex	12393	12.25	57	10	29
Lt. caudate nucleus	4885	11.45	13	6	11
Lt. middle cingulate gyrus	19034	11.07	3	11	42
Rt. lateral prefrontal cortex	8725	10.74	-49	9	25
Rt. basal ganglia	5150	8.73	-13	11	2
Rt. hippocampus including DG	1859	8.51	-20	-36	-6
Rt. middle frontal gyrus	1927	7.32	-33	2	55

Voxel level threshold at $p < 0.001$ uncorrected, corrected for multiple comparisons (family-wise error) to $p < 0.05$ using a cluster threshold. Rt indicates right; Lt, left; DG, dentate gyrus.

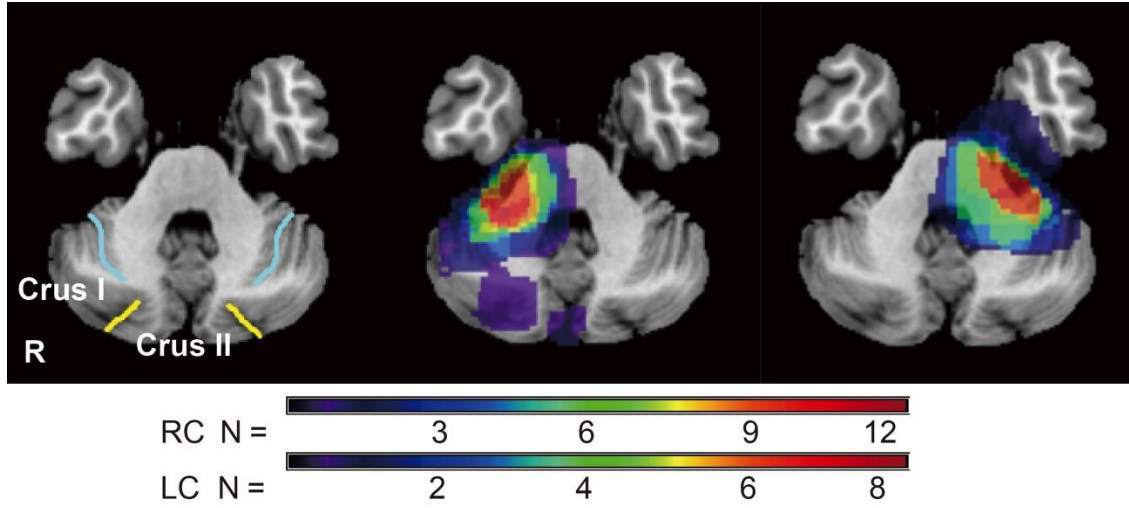


Figure 1. Tumor topography of right (*middle image*, n = 17) and left cerebellar tumors (*right image*, n = 11)

Light blue line indicates the superior posterior fissure; *yellow line* indicates the horizontal fissure in the left image.

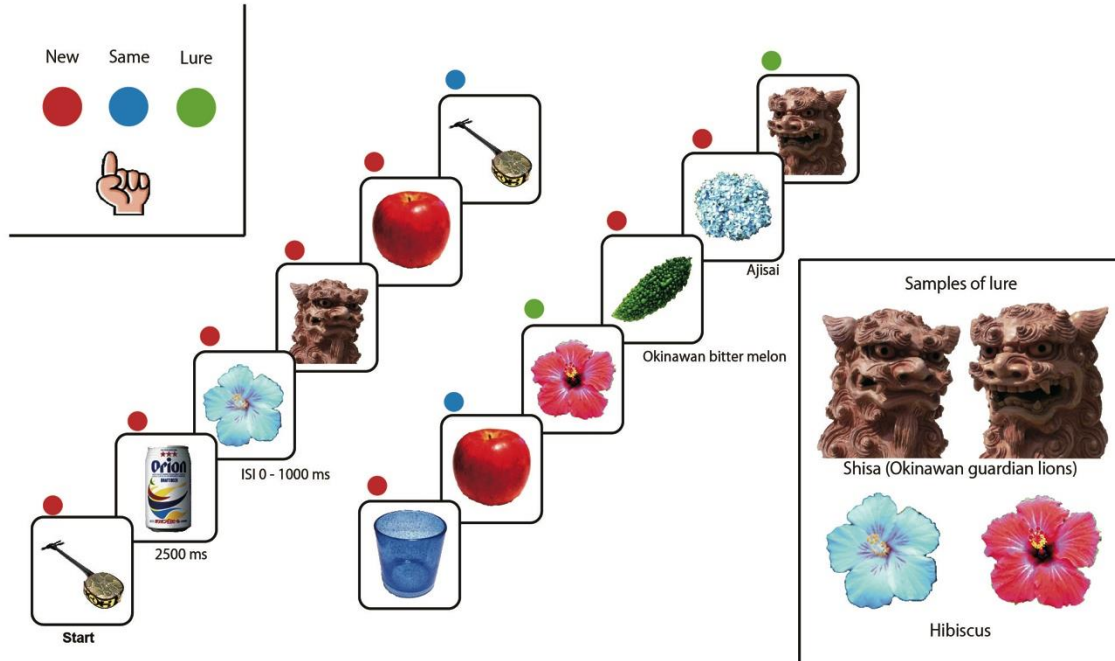


Figure 2. fMRI behavioral task

Images of single items were presented for 2500 ms followed by a 0–1000 ms interstimulus interval. Novel, repeated, and similar lure items were randomly shuffled in the task. *Upper left insets* show three task buttons for new (*red*), lure (*green*), and repeated (*blue*) stimuli. *Lower right insets* show examples of lure pairs; Okinawa guardian lions and hibiscuses.

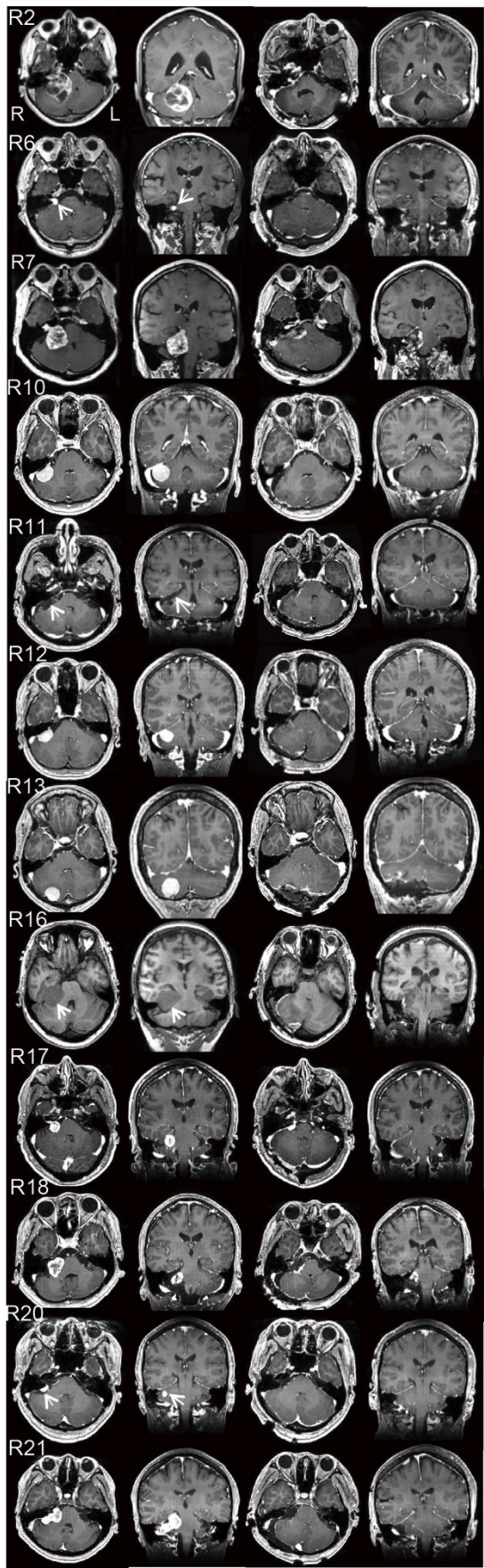


Figure 3. Panels of pre- and postoperative gadolinium-enhanced T1-weighted MRI of Cases R2, R6, R7, R10, R11, R12, R13, R16, R17, R18, R20, and R21 (from top to bottom)

Rows show axial and coronal images before the operation, and axial and coronal images after the operation (from left to right). Since Case R16 is subject to asthma, T1-weighted MRI was performed without contrast medium.

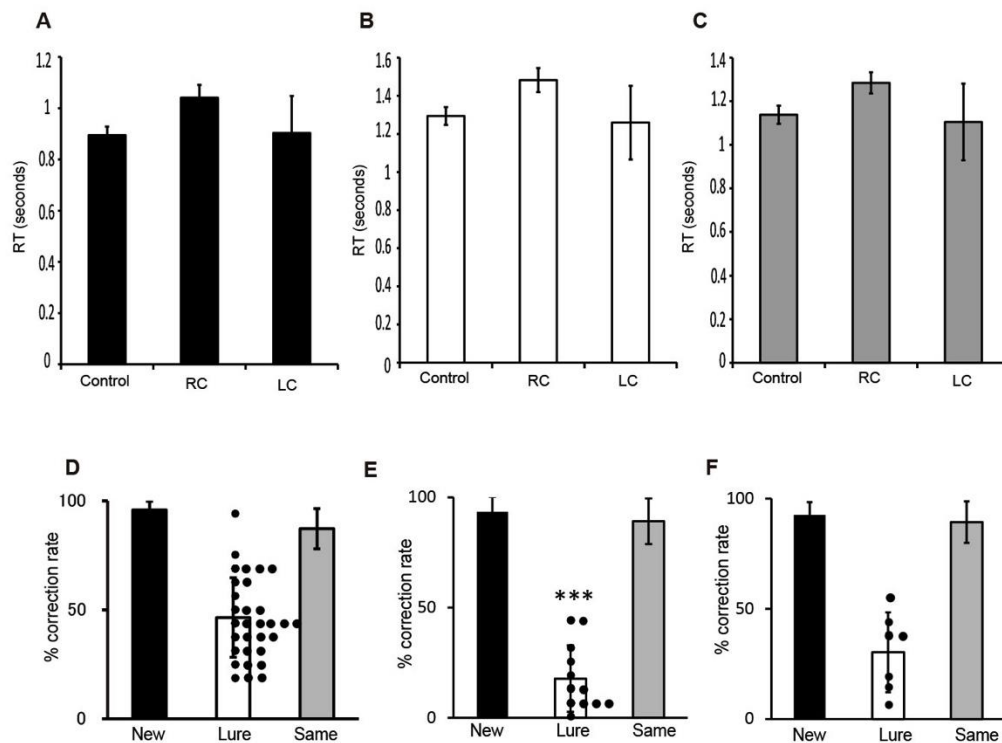


Figure 4. Pattern separation task examined by fMRI

A-C. Reaction times (RT) for new (**A**), lure (**B**), and repeated (**C**) tasks. Control indicates normal healthy volunteers ($n = 30$); RC, patients with right cerebellar tumors ($n = 12$); LC, patients with left cerebellar tumors ($n = 7$). Bars indicate mean; Dots, scores of individual cases. **D-F.** Percentage of correct response to new, lure, and repeated tasks in normal healthy volunteers (**D**), patients with right cerebellar tumors (**E**), and patients with left cerebellar tumors (**F**).-*** in **E** indicates significant decrease compared to control ($p < 0.001$, Mann-Whitney U test).

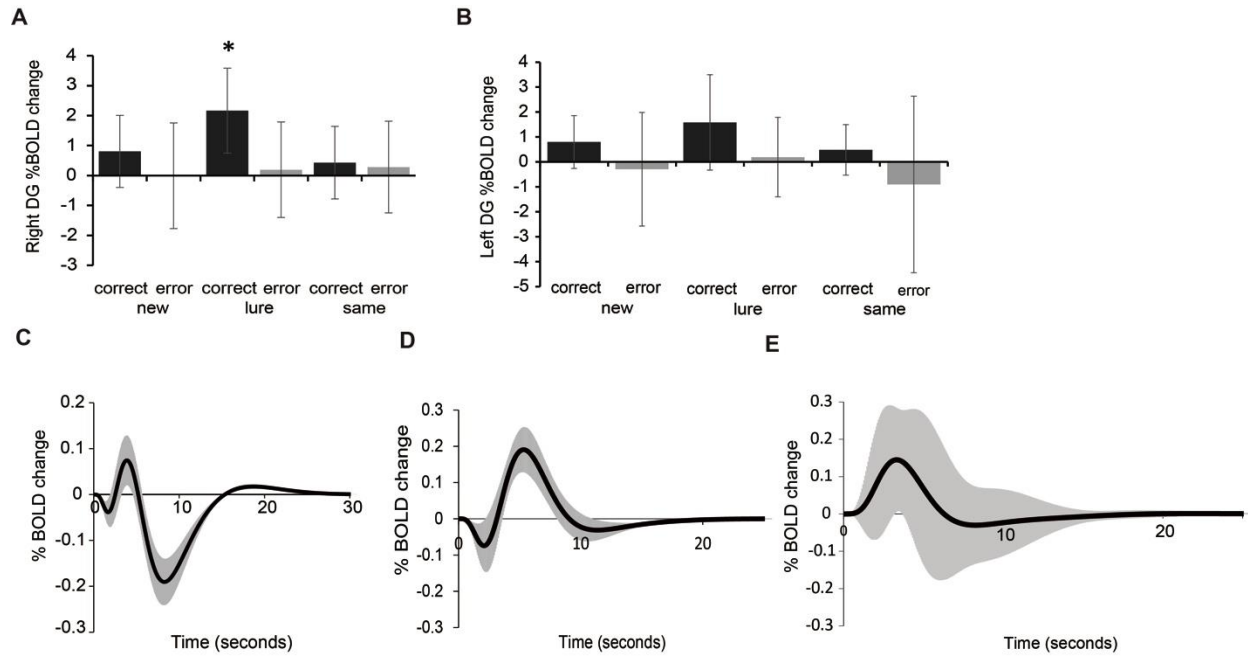


Figure 5. BOLD response by pattern separation task

A - B. Bar graph showing BOLD responses in the right and left DG for correct and error responses of the new, lure, and same tasks in normal healthy volunteers. Correct responses in the lure task were increased during activation of the right DG more so than correct and error responses in other tasks ($n = 30$) (two-way ANOVA, $F = 4.52$, $p < 0.001$, multiple comparisons two-sided test with Bonferroni-corrected critical $p < 0.05$) (**A**). There was no significant difference in % BOLD change in the left DG caused by responses and/or tasks (two-way ANOVA, $F = 1.79$, $p = 0.13$) (**B**). Y-axis indicates the magnitude of the % BOLD change. * denotes a significant increase compared to other conditions ($p < 0.05$).

Graphs showing the average BOLD curve for the lure task in normal healthy volunteers (**B**, $n = 30$), that of patients with right cerebellar tumors (**C**, $n = 12$), and that of patients with left

cerebellar tumors (**D**, $n = 7$). The *black line* shows the average BOLD curve and the *gray line* shows standard deviation. The x-axis represents time course (seconds) of the percentage of BOLD change. The y-axis represents the magnitude of % BOLD change, or the percentage BOLD signal change from the resting to stimulus condition.

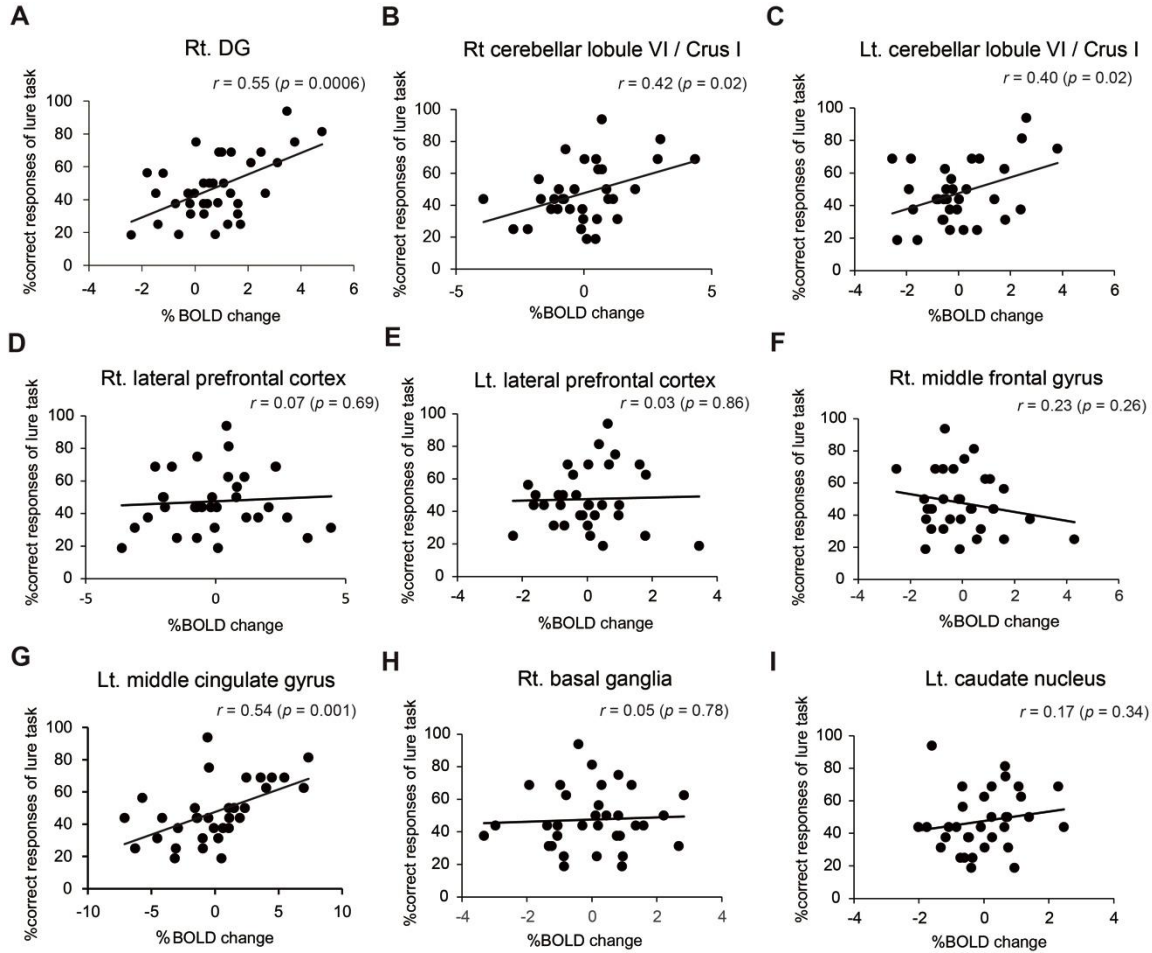


Figure 6. Regions related to pattern separation ability

Graph (A to I) showing correlation of percentage of correct responses of the lure task and that of BOLD signals in control subjects ($n = 30$). Hippocampus including dentate gyrus (DG) (A), right cerebellar lobule VI including Crus I (lobule VI/Crus I) (B), left lobule VI/Crus I (C), right lateral prefrontal cortex (D), left lateral prefrontal cortex (E), right middle frontal cortex (F), left middle cingulate gyrus (G), right basal ganglia (H), and left caudate nucleus (I). The percentage of correct responses in the lure task was significantly correlated with BOLD signals in right DG (A), right lobule VI/Crus I (B), left lobule VI/Crus I (C), and left middle cingulate cortex (G).

No significant relationships were observed in the percentage of BOLD signals in the right and left lateral prefrontal cortex, right middle frontal cortex, right basal ganglia, and left caudate nucleus. The r -value indicates the correlation coefficient of the Pearson product-moment (**A - I**). The P-value indicates the significance level of the correlation coefficient. When the P-value is lower than 0.05, the significance of correlation coefficient is accepted. X-axis represents the magnitude of % BOLD change that represents the rate of BOLD signal from stimulus to resting condition. Y-axis represents the correct response rate in the lure task.

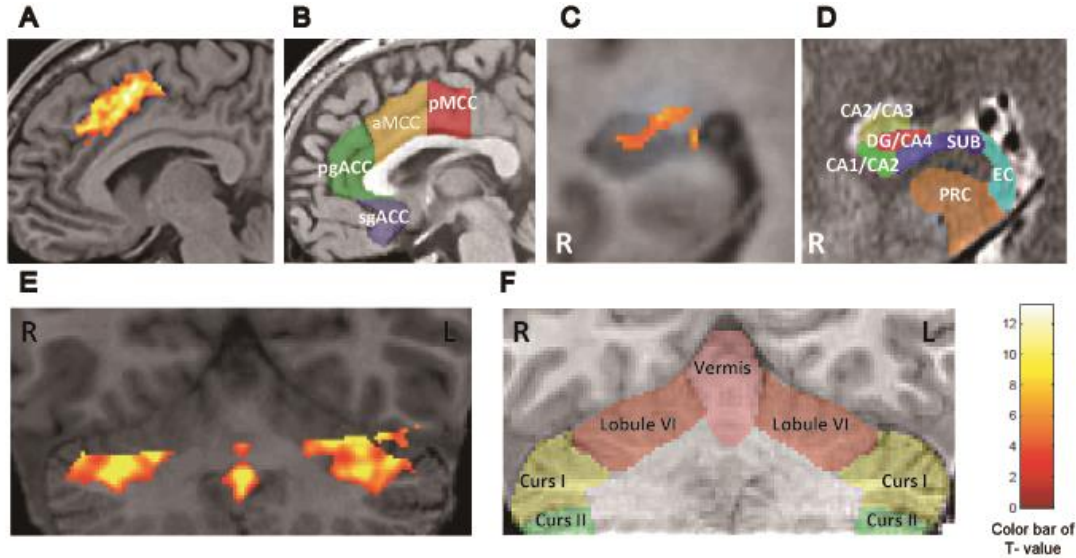


Figure 7. Identification of source ROIs in the activation maps and topographical schemas in healthy subjects

A - F. Identification of source ROIs in the activation maps during a lure task from healthy subjects ($n = 30$, voxel level threshold at $p < 0.001$ uncorrected, corrected for multiple comparisons (family-wise error) to $p < 0.05$ using a cluster threshold) (**A**, **C**, and **E**). Each transparent color indicates the subdivisions of the rostral cingulate cortex (**B**), right hippocampus (**D**), and cerebellum (**F**). The color maps were painted according to references [24-27], and are explained in details in the text. **B**, transparent red, yellow, green, and blue, indicate the pMCC, posterior mid-cingulate cortex; aMCC, anterior mid-cingulate cortex; pgACC, pregenual anterior cingulate cortex; sgACC, subgenual anterior cingulate cortex, respectively. **D**, transparent red, yellow, green, blue, light blue, and orange indicate the hippocampal dentate gyrus and Cornu Ammonis 4 (DG/CA4); Cornu Ammonis 2 and 3 (CA2/CA3); Cornu Ammonis 1 and 2 (CA1/CA2); subiculum (SUB); entorhinal cortex (EC); and perirhinal cortex (PRC), respectively.

F, Transparent pink, orange, yellow, and green indicate the cerebellar vermis, and bilateral lobule VI, Crus I, and Crus II, respectively. Anatomical identification is specified in the text. Note that the aMCC in **A**, and DG/CA4 in **C**, and lobule VI and/or Crus I in **E** were selectively activated. The color bar indicates *t*-values (maximum $t = 13.18$, white represents the highest value). R, the right hemisphere. L, the left hemisphere.

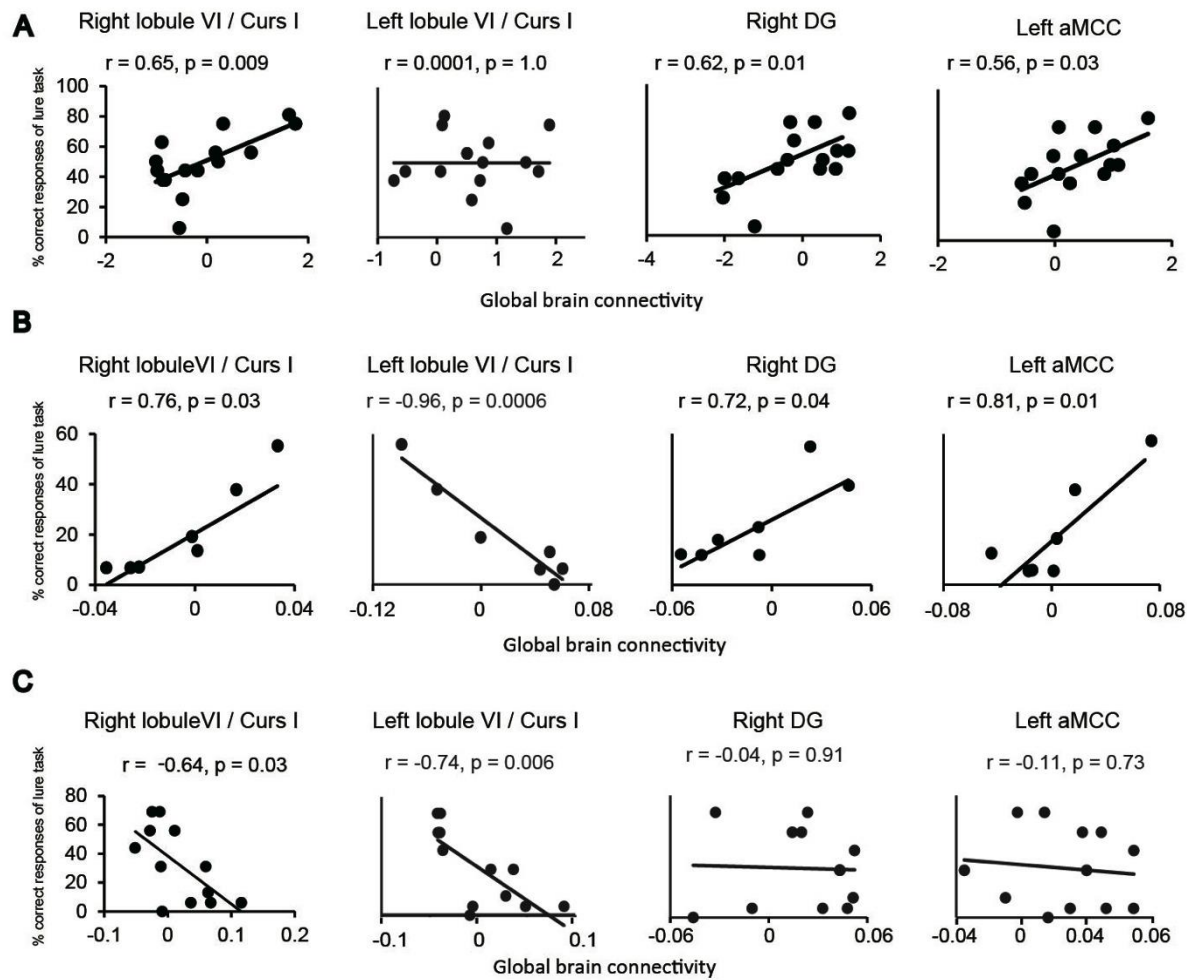


Figure 8. Correlation of GBC value and pattern separation ability

A – C. Graphs showing correlation between the correct response rate in the lure task and the GBC value in the right cerebellar lobule VI including Crus I (lobule VI/Crus I), left lobule VI/Crus I, right dentate gyrus (DG), and left anterior middle cingulate cortex (aMCC). **A** healthy subjects ($n = 15$). **B** patients with left cerebellar tumors ($n = 7$). **C** patients with right cerebellar tumors ($n = 12$). The r -value, the correlation coefficient of the Pearson product-moment. The

p-value, the significance level of correlation coefficient. X-axis, the value of GBC. Y-axis, the percentage of correct responses of lure task. Details are described in the text.

出願完了の御通知

国立大学法人琉球大学 様



2014年03月31日
〒102-0073
東京都千代田区九段北4-3-14
九段堀江ビル6階
西澤国際特許事務所
弁理士 西澤利夫
TEL: 03-3512-9300(代表)
FAX: 03-3512-9301
E-mail: nisi-pat@nisi-pat.com

謹啓 時下益々ご清祥のこととお慶び申し上げます。

先に御依頼いただきました件につき、2014年03月31日付にて出願完了致しましたので、出願書類一式を御送付してお知らせ申し上げます。

尚、今後は、下記の出願番号をもって御対応申し上げますので、御確認下さいますようお願い申し上げます。

敬 具

(記)

名 称	海馬機能の評価値算出方法、海馬機能の評価値算出システム、海馬機能の評価方法およびテストアイテムセット		
出 願 番 号	特願2014-074112		
出 願 日	2014年03月31日		
発 明 者	石内 勝吾		
出 願 人	国立大学法人琉球大学		
審 査 請 求 期 限	2017年03月31日		
海外優先権主張期限	2015年03月31日		
国内優先権主張期限	2015年03月31日		
貴 整 理 番 号	当所整理番号	NP14034	

<添付書類>

- | | |
|------------|-----|
| (1) 出願書類一式 | 1 通 |
| (2) 請求書 | 1 通 |

受領書

平成26年 3月31日
特許庁長官識別番号 100093230
氏名(名称) 西澤 利夫 様

以下の書類を受領しました。

項番	書類名	整理番号	受付番号	提出日	出願番号通知(事件の表示)
1	特許願	NP14034	51400699411	平26. 3. 31	特願2014- 74112 以上

【書類名】 特許願
【整理番号】 NP14034
【提出日】 平成26年 3月31日
【あて先】 特許庁長官 殿
【国際特許分類】 A61B 10/00
【発明者】
【住所又は居所】 沖縄県中頭郡西原町字千原 1 番地 国立大学法人琉球大学内
【氏名】 石内 勝吾
【特許出願人】
【識別番号】 504145308
【氏名又は名称】 国立大学法人琉球大学
【代理人】
【識別番号】 100093230
【弁理士】
【氏名又は名称】 西澤 利夫
【電話番号】 03-3512-9300
【手数料の表示】
【予納台帳番号】 009911
【納付金額】 15,000円
【提出物件の目録】
【物件名】 明細書 1
【物件名】 特許請求の範囲 1
【物件名】 要約書 1
【物件名】 図面 1

【書類名】明細書

【発明の名称】海馬機能の評価値算出方法、海馬機能の評価値算出システム、海馬機能の評価方法およびテストアイテムセット

【技術分野】

【0001】

海馬機能の評価値算出方法、海馬機能の評価値算出システム、海馬機能の評価方法およびテストアイテムセットに関する。

【背景技術】

【0002】

海馬は、学習と記憶に重要な役割を果たすことが知られており、その機能についての様々な研究が行われている。

【0003】

例えば、非特許文献1には、遺伝子改変動物を用いて、海馬歯状回のNMDA受容体が似ているが少し異なる事物に対する認識 (pattern separation) に関与することが記載されている。非特許文献2には、新生神経細胞がpattern separationに関与し、成熟神経細胞がpattern completion (似ている物の形状の認識) に関与することが記載されている。

【0004】

一方、特許文献1には、被験者にディスプレイに表示した一次画像と二次画像が同じであるか異なるかを回答してもらい、その回答結果から脳機能の活性度を計測する脳機能計測方法が記載されている。より具体的には、特許文献1の方法は、注視エリアが設けられた一次画像が順次、自動的に表示され、つづいて、これら一次画像に対して、注視エリア内の画像情報が同じまたは異なる二次画像が同様に順次、自動的に表示され、その指定注視エリアの画像を目視して、先に目視した一次画像と同じ画像か異なる画像かを回答させるものである。特許文献1の方法によれば、機能的磁気共鳴画像 (fMRI) などの高価な装置を利用しなくても、簡便に、海馬などの機能の活性度を計測することができるとされている。

【先行技術文献】

【特許文献】

【0005】

【特許文献1】特開2005-192637号公報

【非特許文献】

【0006】

【非特許文献1】Science 317, 94-97, Jul6, 2007

【非特許文献2】Cell 149, 188-201, March30, 2012

【発明の概要】

【発明が解決しようとする課題】

【0007】

非特許文献1、2に記載されているように、被験者の海馬機能を適確に評価するためには、pattern separationに関与する海馬の新生神経細胞の状態を把握することが重要であると考えられるが、特許文献1の脳機能計測方法は、注視エリアを設けた一次画像と二次画像が同じであるか異なるかを判断させるものであるため、主に被験者の一次記憶 (最初に入る記憶の情報) についての検査が行われているに過ぎない。また、特許文献1の方法では、被験者が注視エリアを確認できるか否かの注意機能 (前頭葉機能) が回答結果に大きく影響するため、海馬機能を評価することは難しいという問題がある。

【0008】

本発明は、以上のとおりの事情に鑑みてなされたものであり、被験者の海馬機能を簡便かつ確実に評価することができる海馬機能の評価値算出方法、海馬機能の評価値算出システムおよび海馬機能の評価方法を提供することを課題としている。また、海馬機能の評価に利用されるテストアイテムを提供することを課題としている。

【課題を解決するための手段】

【0009】

上記の課題を解決するために、本発明の海馬機能の評価値算出方法は、被験者の海馬機能の健全性を判断するための指標となる海馬機能の評価値を算出する方法であって、以下の工程：

複数のテストアイテムを被験者に順次提示する試行を繰り返し行う試行工程；

前記試行工程における各試行の終了後、被験者にその試行で提示されたテストアイテムが、以下の (A) ～ (C) のパターン、

(A) 初めて提示されたテストアイテム

(B) 従前の試行で提示されたテストアイテムと類似する別種のテストアイテム

(C) 従前の試行で提示されたことがあるテストアイテムと同一のテストアイテム

のうちのいずれであるかを回答させる回答工程；

前記試行工程で提示したテストアイテムと前記回答工程で得られた回答結果とを比較して各試行に対する回答結果の正誤を判定する正誤判定工程；および

前記正誤判定工程で得られた結果を集計して、前記 (A)、(B)、(C) の各パターンごとに正答率を算出し、その正答率を海馬機能の評価値として得る評価値算出工程を含むことを特徴としている。

【0010】

本発明の海馬機能の評価値算出システムは、被験者の海馬機能の健全性を判断するための指標となる海馬機能の評価値を算出するためのシステムであって、

複数のテストアイテムを被験者に順次提示する試行を繰り返し実行するためのテストアイテム提示手段と、

各試行で提示するテストアイテムをテストアイテム提示手段に出力するテストアイテム出力手段と、

各試行の終了後、被験者が各試行で提示されたテストアイテムが、以下の (A) ～ (C) のパターン、

(A) 初めて提示されたテストアイテム

(B) 従前の試行で提示されたことがあるテストアイテムと類似する別種のテストアイテム

(C) 従前の試行で提示されたことがあるテストアイテムと同一のテストアイテムのうちのいずれであるかについての回答結果を入力する回答結果入力手段と、

回答結果入力手段を介して入力された回答結果を記憶する回答結果記憶手段と、

前記テストアイテム出力手段によって出力された各試行におけるテストアイテムと、前記回答結果記憶手段に記憶された回答結果とを比較して、各試行に対する回答結果の正誤を判定して、前記 (A)、(B)、(C) の各パターンごとに正答率を算出し、その正答率を海馬機能の評価値として得る評価値算出手段、を含むことを特徴としている。

【0011】

本発明の海馬機能の評価方法は、被験者の海馬機能の健全性を評価するための海馬機能の評価方法であって、以下の工程：

複数のテストアイテムを被験者に順次提示する試行を繰り返し行う試行工程；

前記試行工程における各試行の終了後、被験者にその試行で提示されたテストアイテムが、以下の (A) ～ (C) のパターン、

(A) 初めて提示されたテストアイテム

(B) 従前の試行で提示されたテストアイテムと類似する別種のテストアイテム

(C) 従前の試行で提示されたことがあるテストアイテムと同一のテストアイテム

のうちのいずれであるかを回答させる回答工程；

前記試行工程で提示したテストアイテムと前記回答工程で得られた回答結果とを比較して各試行に対する回答結果の正誤を判定する正誤判定工程；

前記回答工程で得られた回答結果の正誤を集計して、前記 (A)、(B)、(C) の各パターンごとに正答率を算出する正答率算出工程；

前記正答率算出工程で算出された被験者のパターン (B) の正答率を、健常者のパターン (B) の正答率の (平均値±標準偏差) と比較する工程、

被験者の正答率が、健常者のパターン (B) の正答率の標準偏差の2倍以上低い場合に、海馬に疾患または損傷が生じていると評価する海馬機能評価工程；を含むことを特徴としている。

【0012】

本発明のテストアイテムセットは、前記海馬機能の評価値算出方法に使用されるテストアイテムのセットであって、30名以上の健常者のうちの85%~98%が同一であると判断するアイテム群からなる同一テストアイテムセットと、30名以上の健常者のうちの40%~50%が前記同一テストアイテムと類似しているが異なると判断するアイテム群からなる類似テストアイテムセットと、前記同一テストアイテムセットおよび類似テストアイテムセットとは異なると判断される単独のテストアイテム群からなる単独テストアイテムセットとを含むことを特徴としている。

【発明の効果】

【0013】

本発明の海馬機能の評価値算出方法、海馬機能の評価値算出システムによれば、被験者の海馬機能の健全性の指標となる評価値を簡便かつ確実に算出することができる。また、本発明の海馬機能の評価方法によれば、被験者の海馬に疾患または損傷が生じている否かや新生神経細胞の状態、放射線治療後の認知機能の回復経過、内分泌系代謝疾患、糖尿病、肥満患者の認知能力 (海馬新生機能) を簡便かつ確実に評価することができる。さらに、本発明のテストアイテムによれば、海馬機能の評価値を簡便に得ることができる。

【図面の簡単な説明】

【0014】

【図1】「類似する別種のテストアイテム」の具体例を示した図である。

【図2】本発明の海馬機能の評価値算出方法の一実施形態を例示した概要図である。

【図3】健常者1例 (25歳男子) のBOLD解析の結果および海馬機能の評価値 (New、Lure、Sameの正答率 (平均値±標準偏差)) の結果を示す図である。

【図4】健常者、良性脳腫瘍患者、悪性脳腫瘍患者、悪性脳腫瘍放射線治療施行患者のNew、Lure、Sameの正答率の結果を示す図である。

【図5】被験者の左右の海馬に放射線を照射して治療した際の放射線量とLure正答率の関係を示す図である。

【図6】海馬のBOLD信号とLure正答率との関係を示す図である。

【図7】非定型髄膜腫の患者に対して、放射線化学療法を施行した例におけるNew、Lure、Sameの正答率とBOLD信号を示す図である。

【図8】悪性脳腫瘍 (グリオーマ) の患者に対して、放射線化学療法を施行した例におけるNew、Lure、Sameの正答率とBOLD信号を示す図である。

【図9】左側頭葉神経膠芽腫の患者に対して放射線化学療法を施行後、薬剤による治療介入した例におけるNew、Lure、Sameの正答率の変化を示す図である。

【発明を実施するための形態】

【0015】

本発明の海馬機能の評価値算出方法は、被験者の海馬機能の健全性を判断するための指標となる海馬機能の評価値を算出する方法であって、以下の工程：

複数のテストアイテムを被験者に順次提示する試行を繰り返し行う試行工程；

前記試行工程における各試行の終了後、被験者にその試行で提示されたテストアイテムが、以下の (A) ~ (C) のパターン、

(A) 初めて提示されたテストアイテム

(B) 従前の試行で提示されたテストアイテムと類似する別種のテストアイテム

(C) 従前の試行で提示されたことがあるテストアイテムと同一のテストアイテム

のうちのいずれであるかを回答させる回答工程；

前記試行工程で提示したテストアイテムと前記回答工程で得られた回答結果とを比較し