

114

D

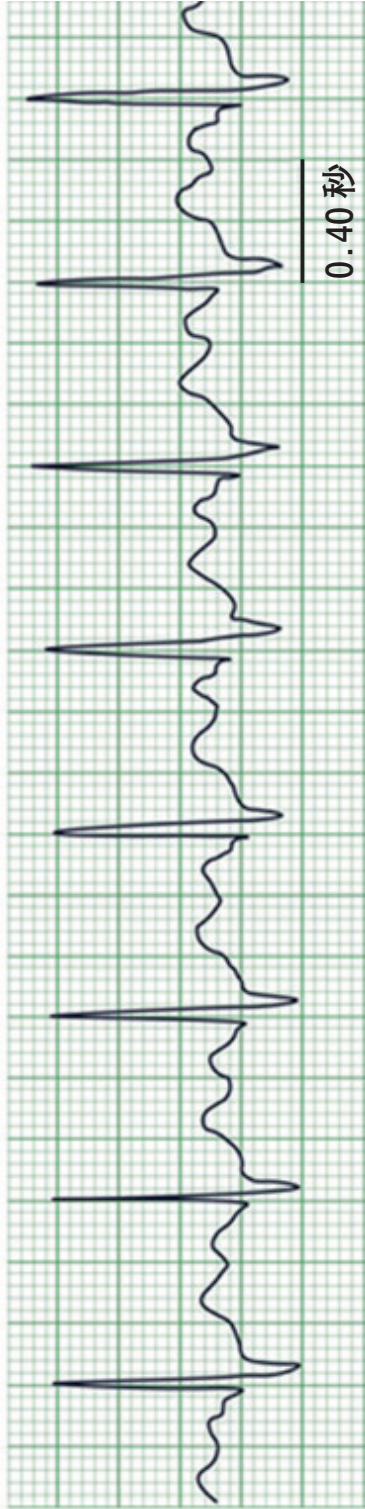
別 冊







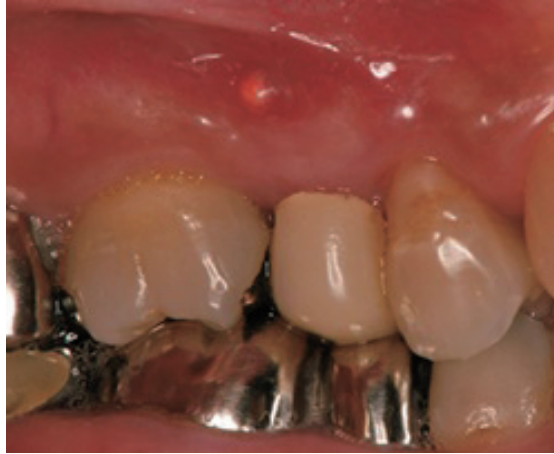No. 1 (D 問題 14)



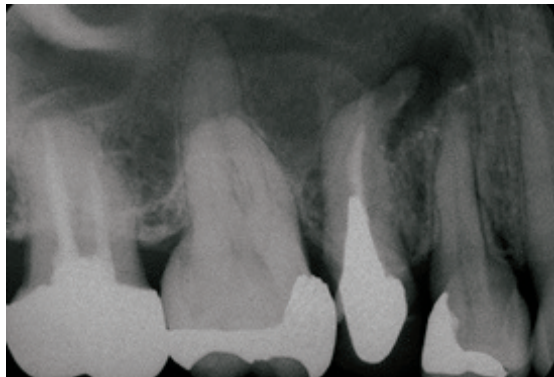
No. 2

(D 問題 26)

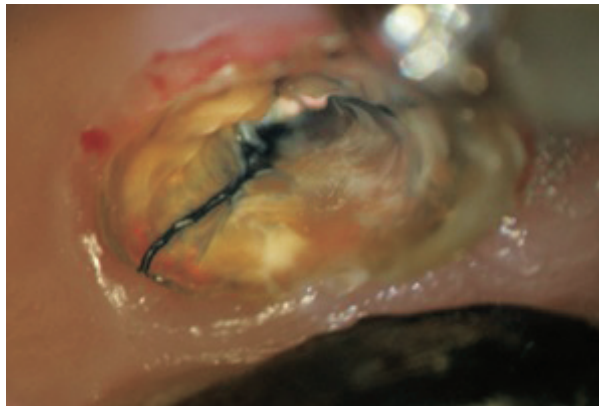
A



B

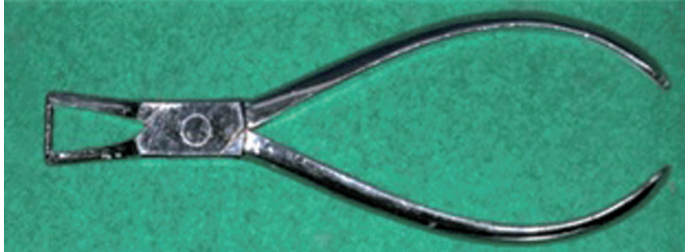


C

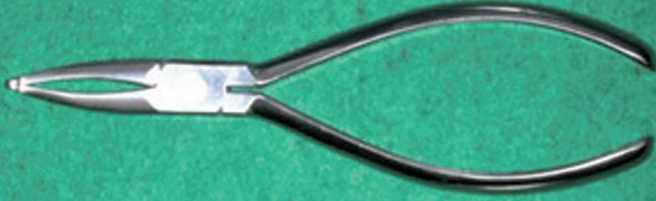

No. 3 (D 問題27)

オ



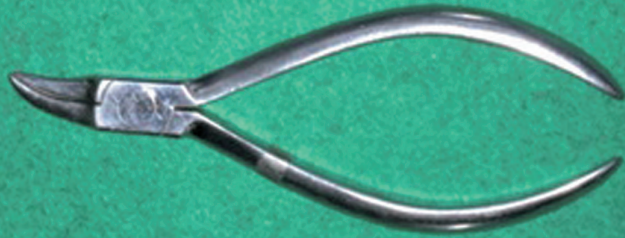
エ



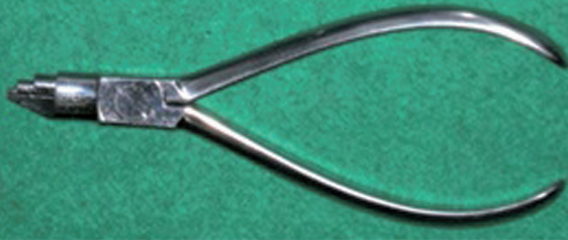
ウ



イ



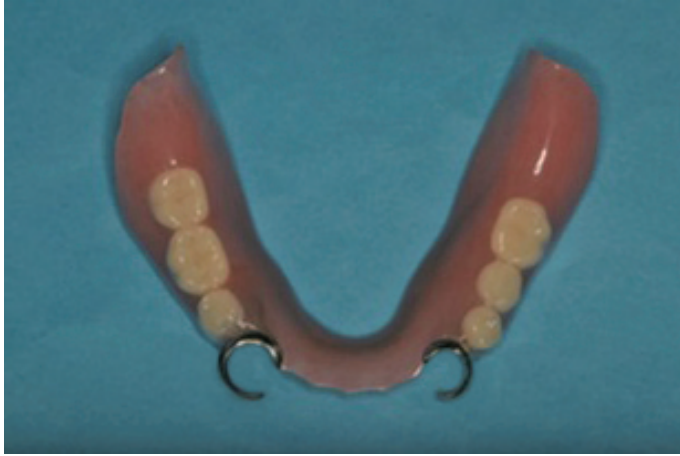ア



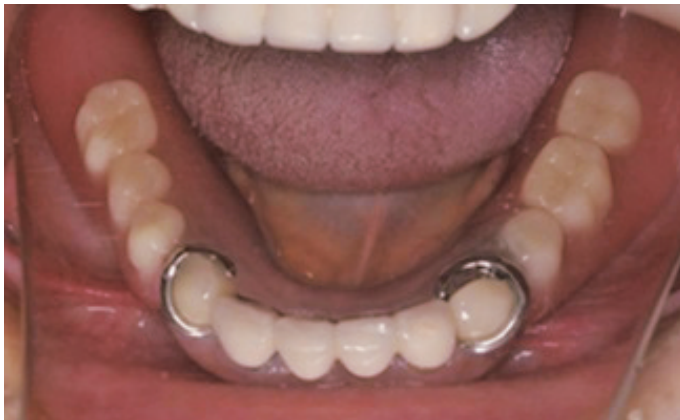No. 4

(D 問題 30)

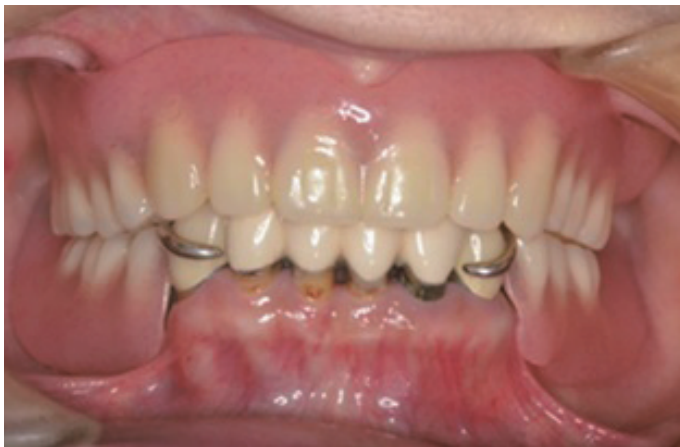A



B



(ミラー像)

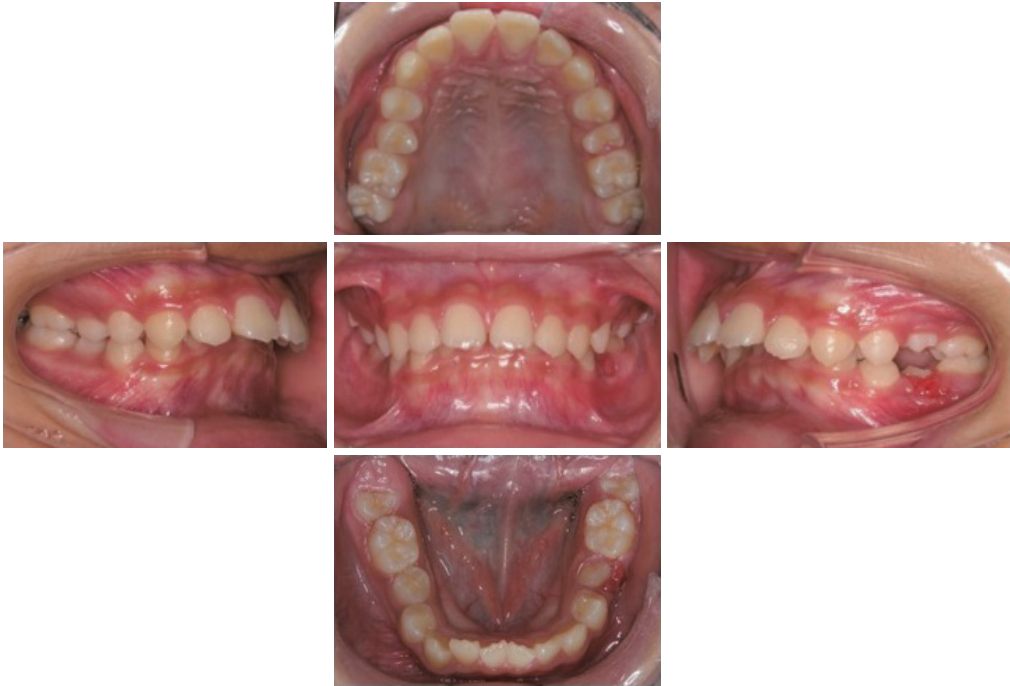



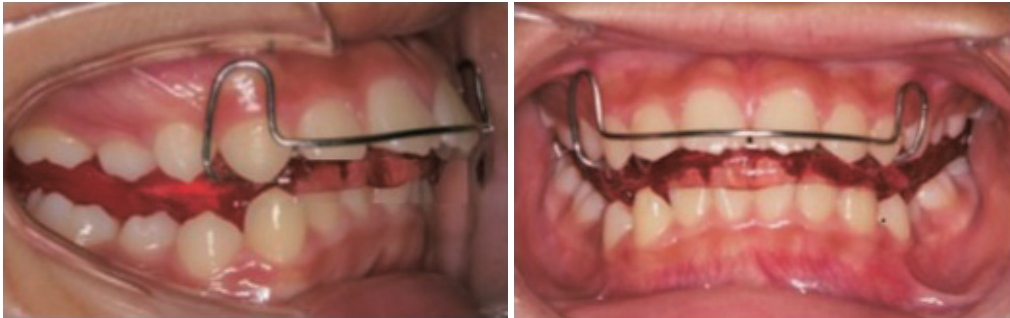
No. 5

(D 問題 31)

A



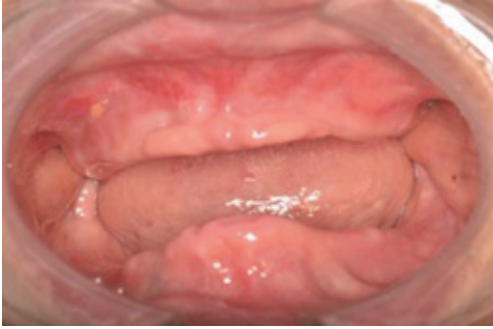B



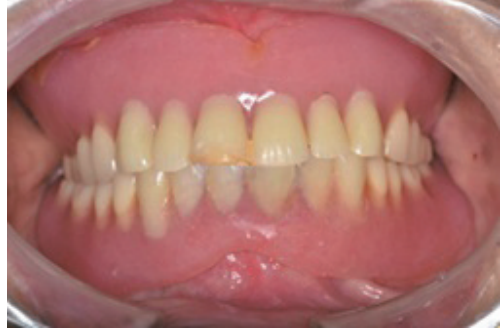No. 6

(D 問題 33)

A

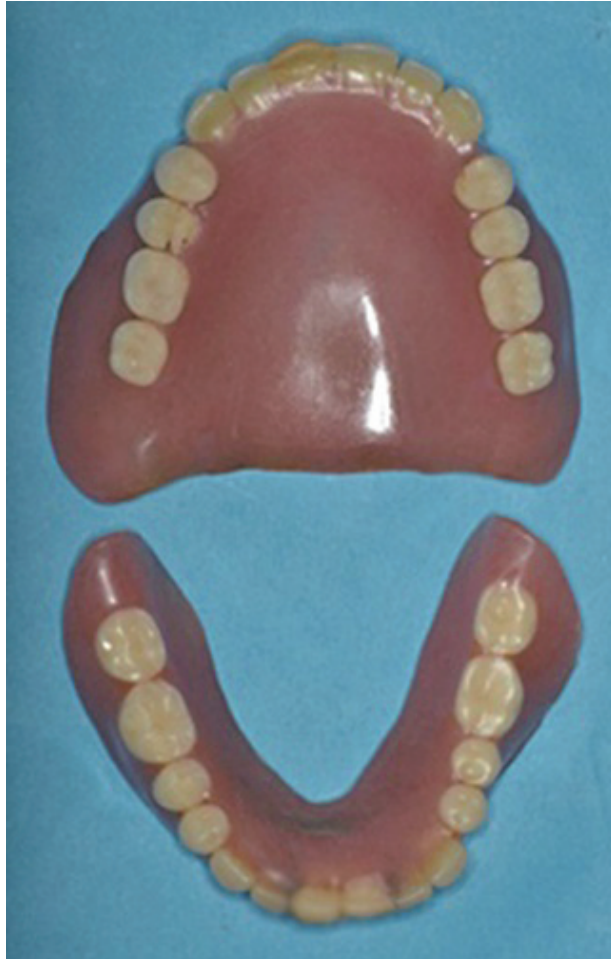

旧義齒装着前



旧義齒装着後

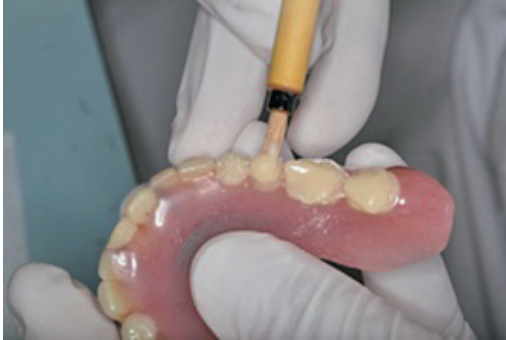B



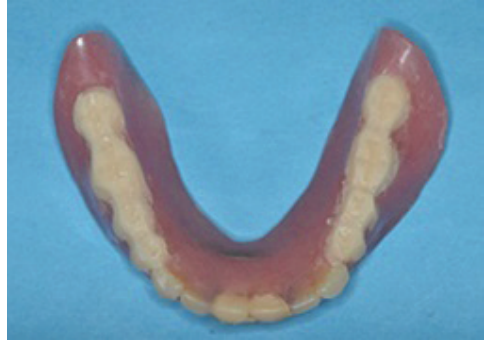No. 6

(D 問題 33)

C

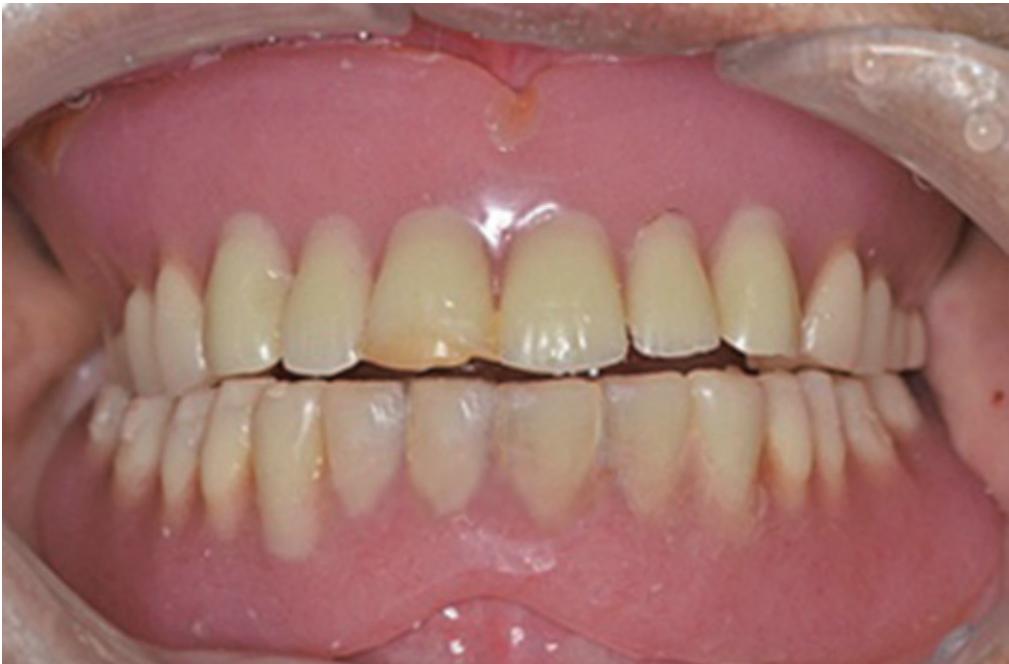

前処置中



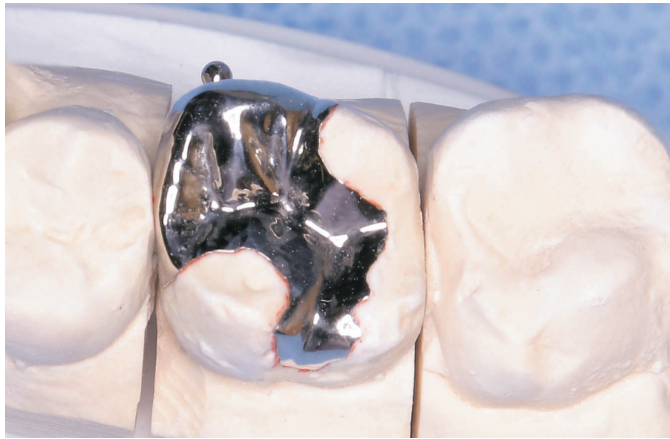
前処置後

D



No. 7

(D 問題 35)

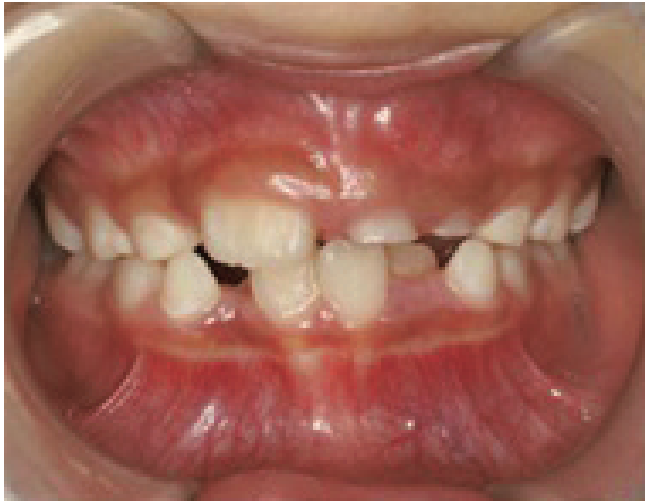

余 白

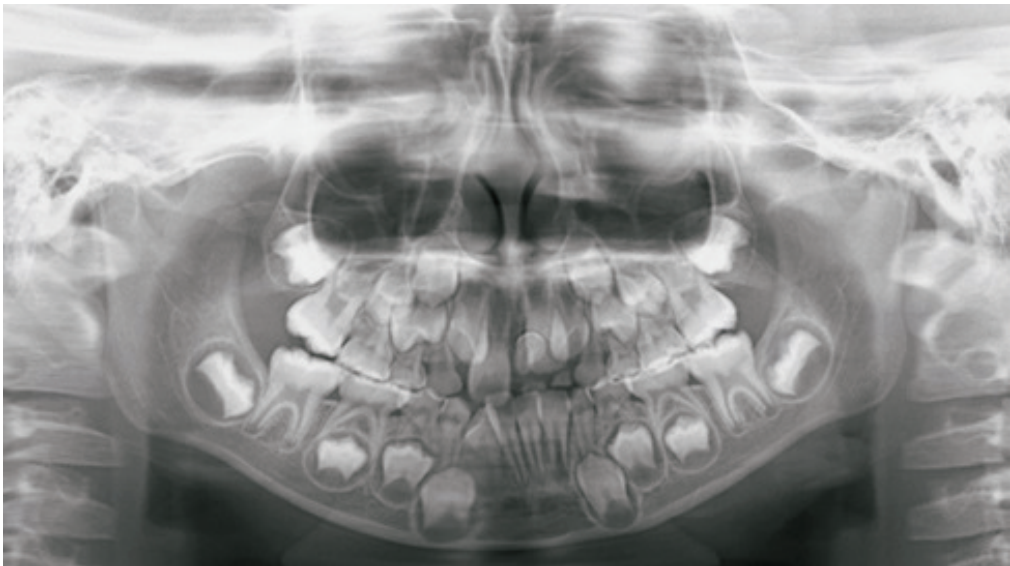
No. 8

(D 問題 36)

A



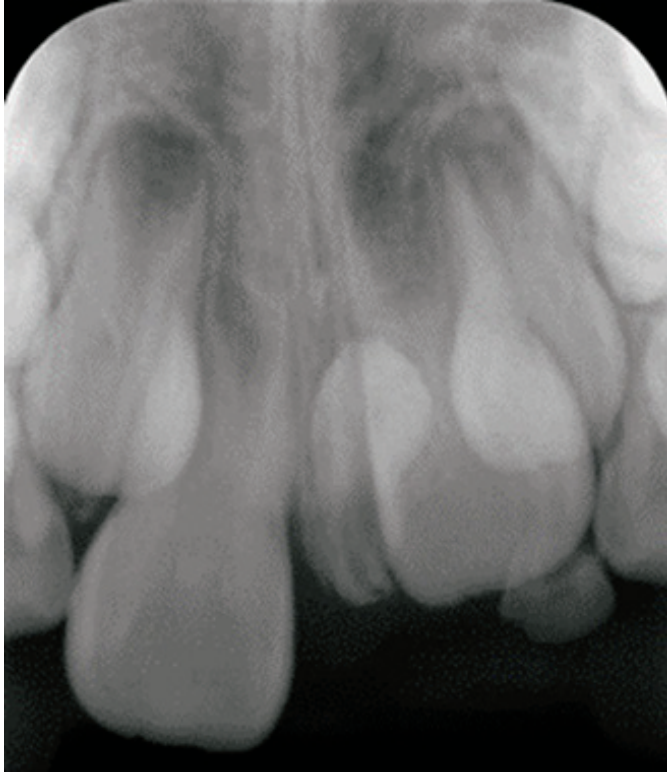B



No. 8

(D 問題 36)

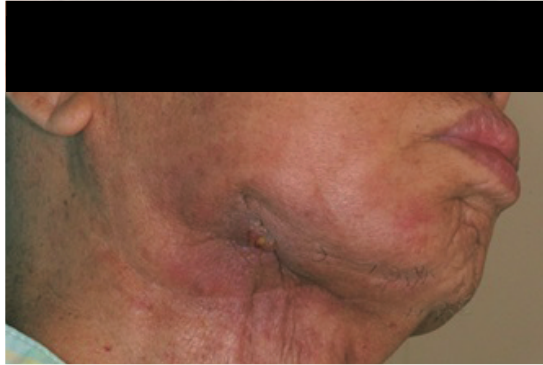C



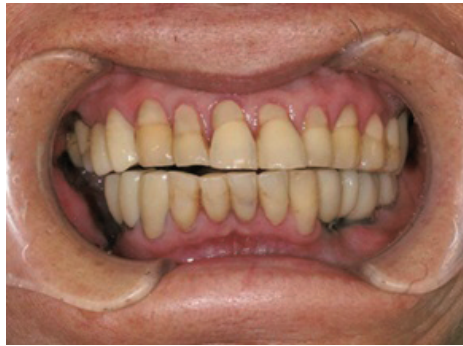No. 9

(D 問題 37)

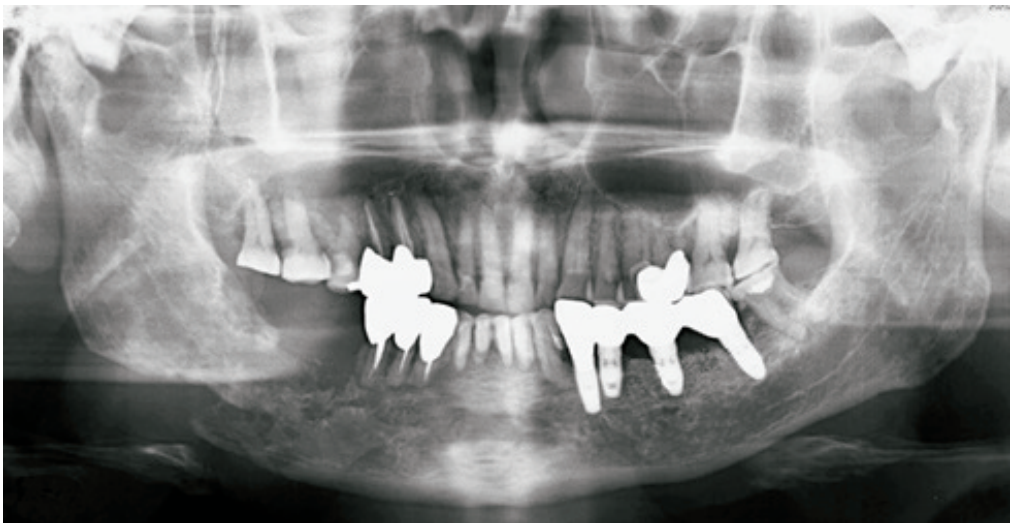
A



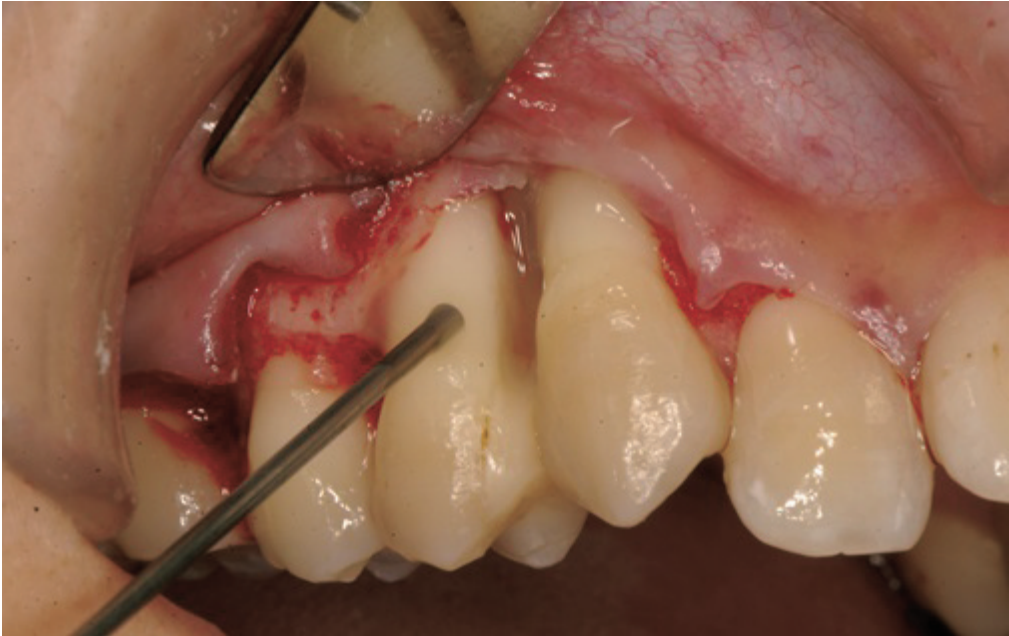
B



C

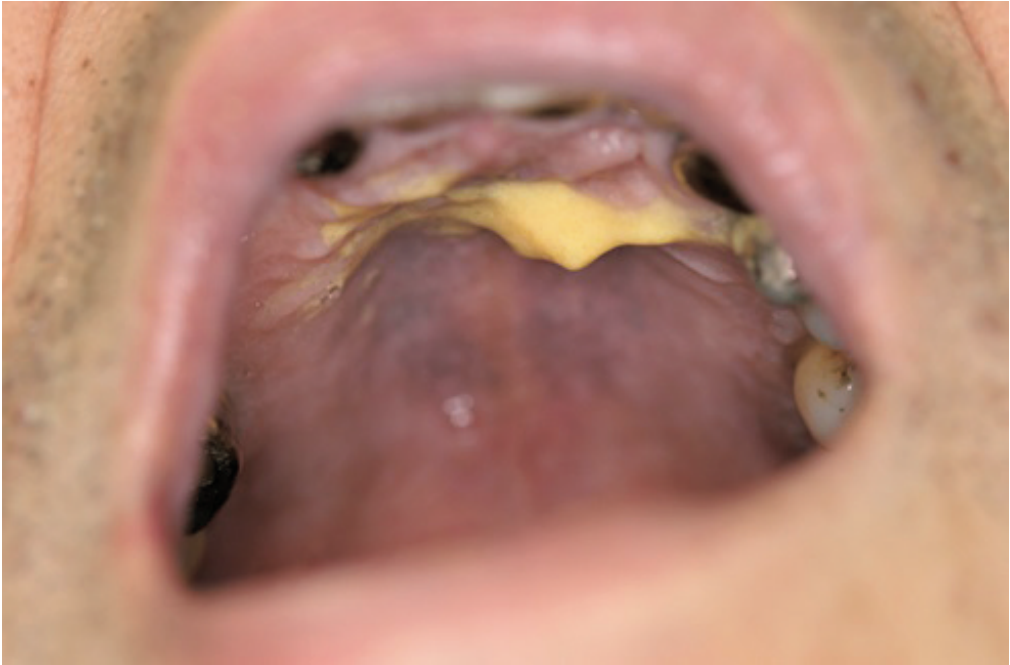

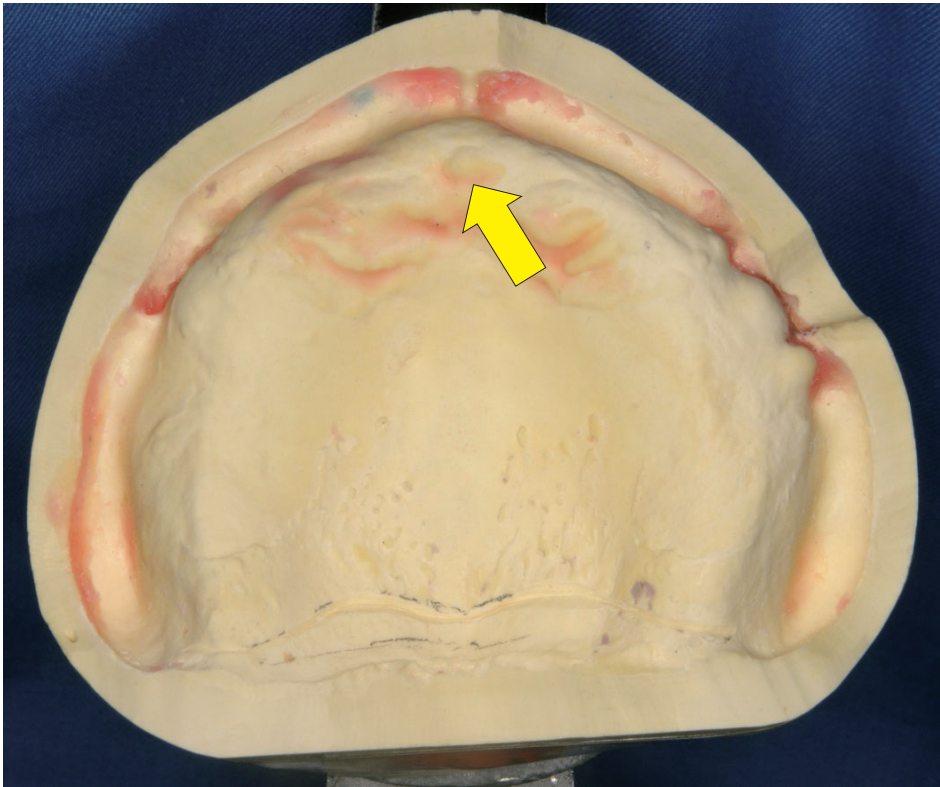




No. 11

(D 問題 46)

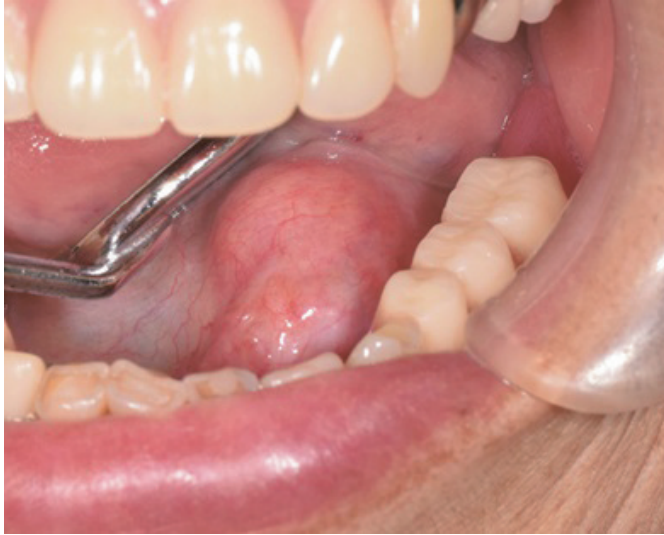



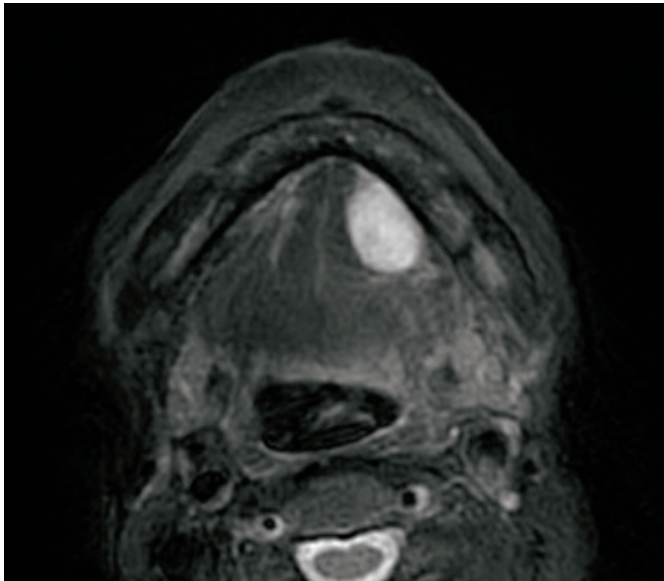
No. 13

(D 問題 49)

A



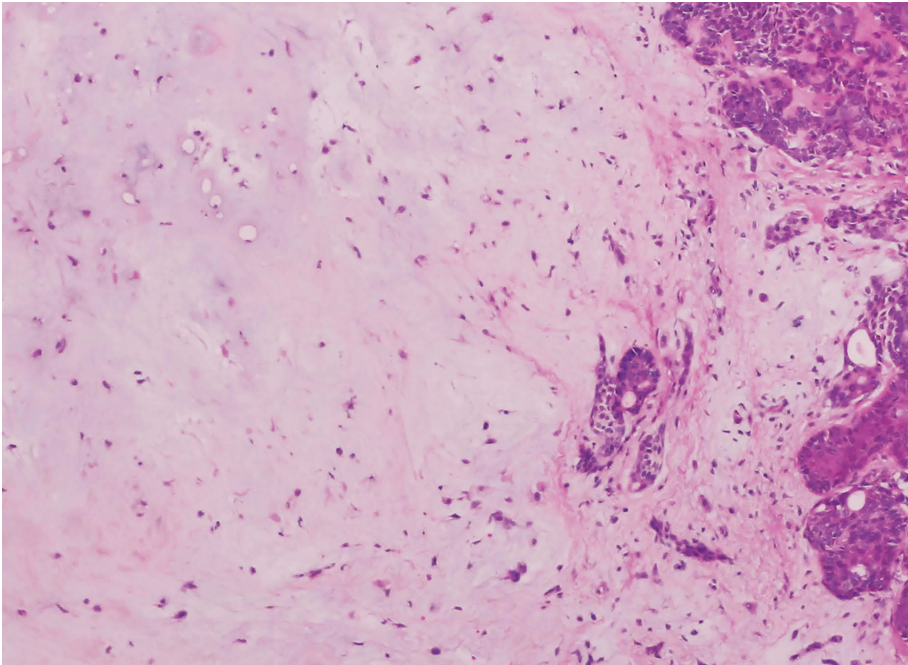
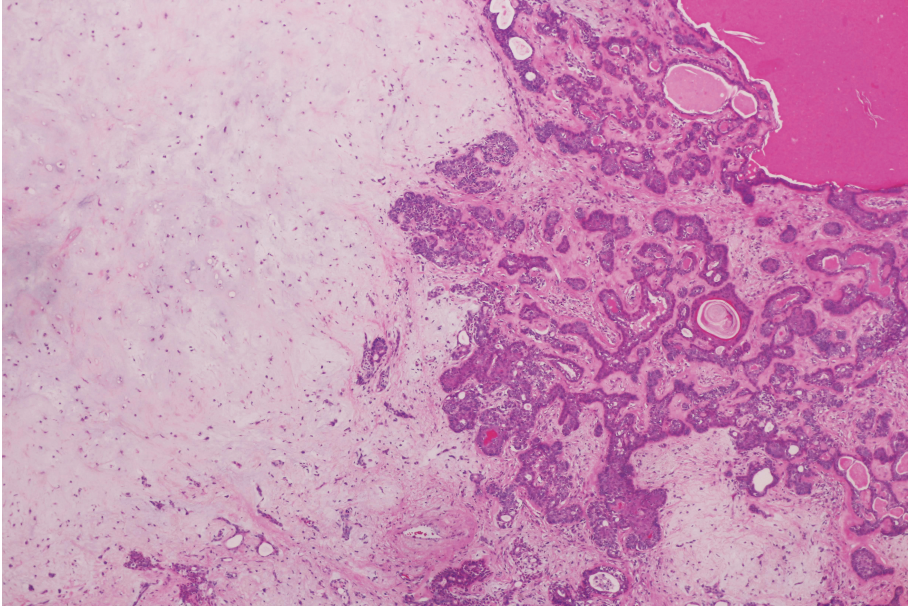
B



No. 13

(D 問題 49)

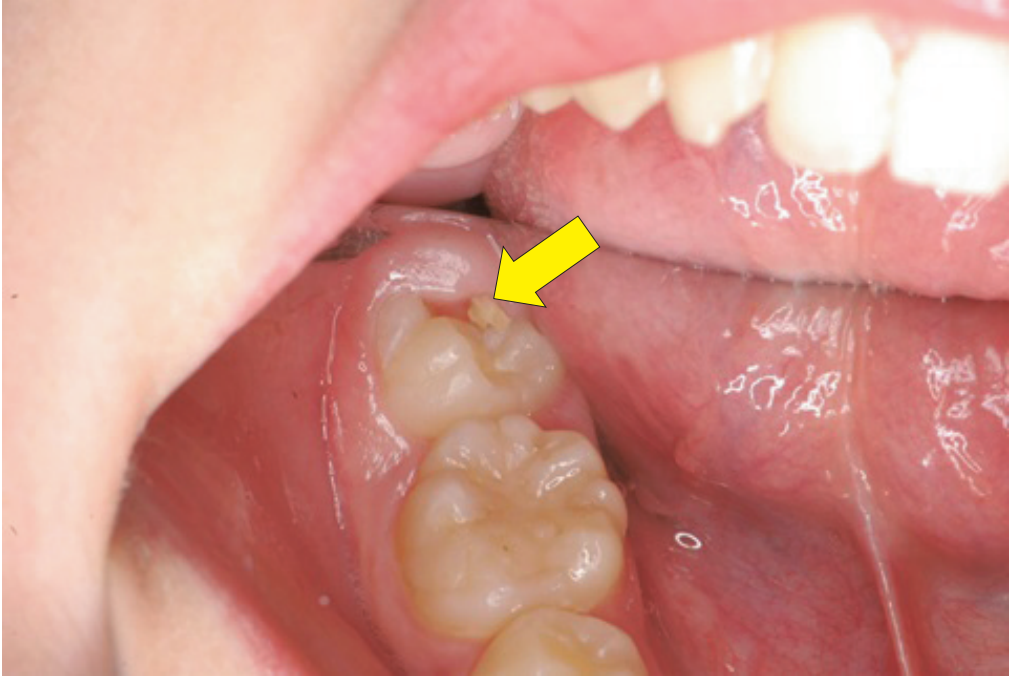
C



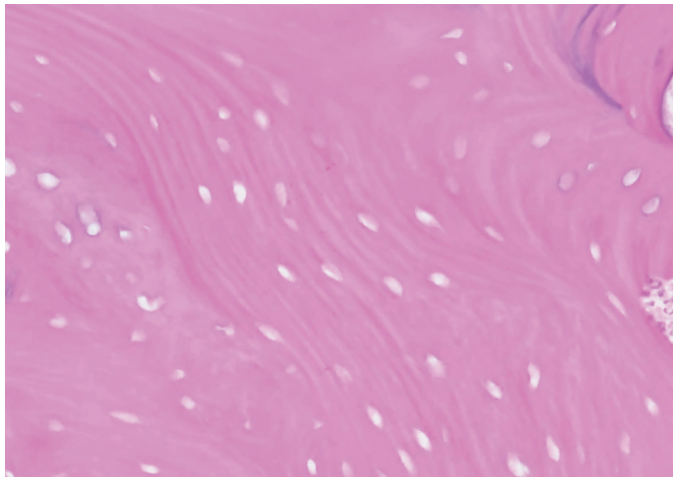
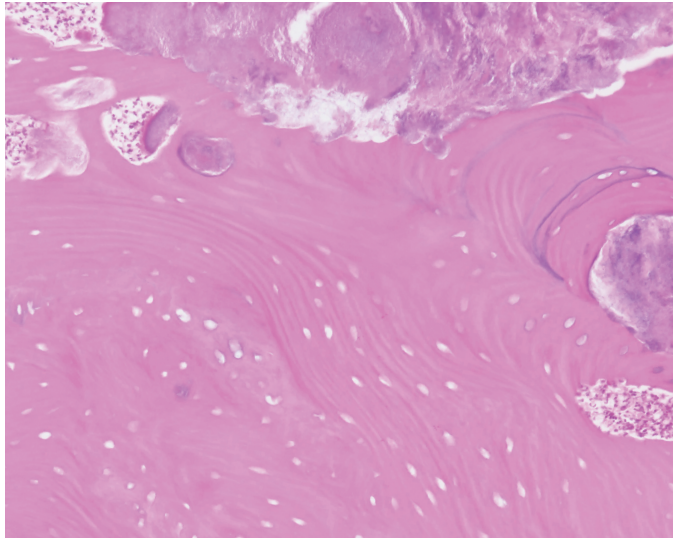
No. 14

(D 問題 50)

A



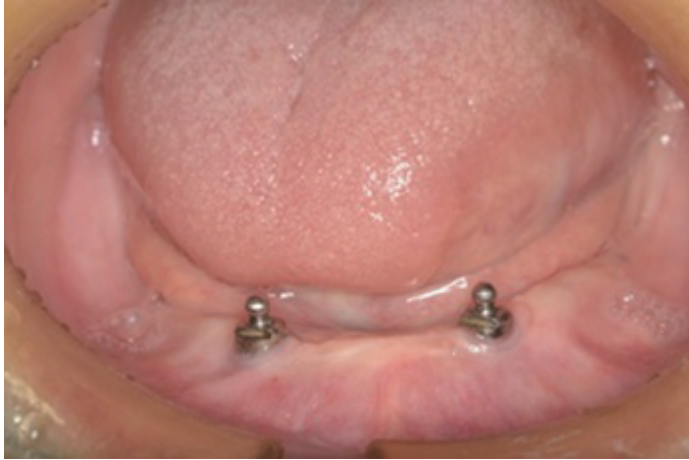**B**



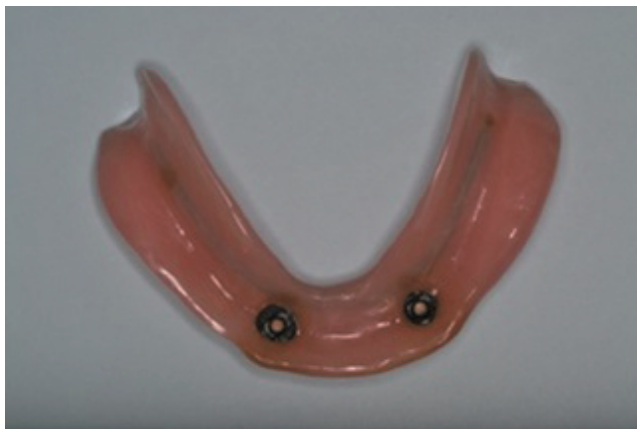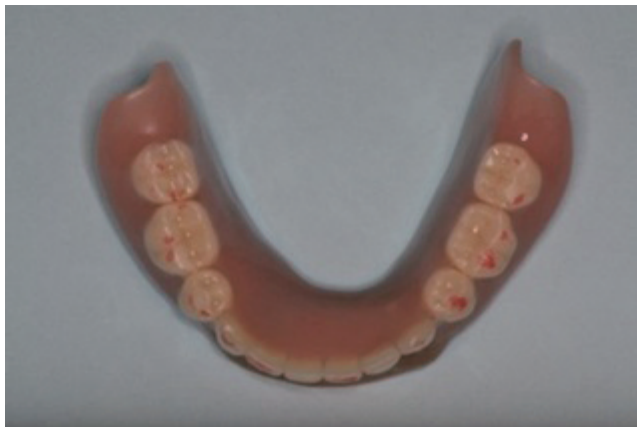No. 15

(D 問題 53)

A



B

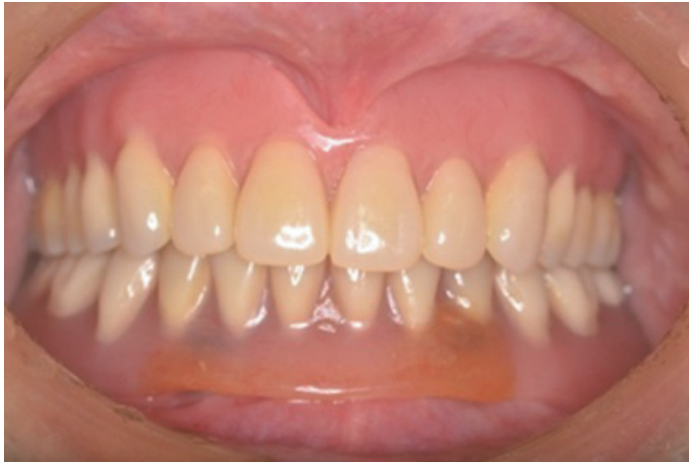



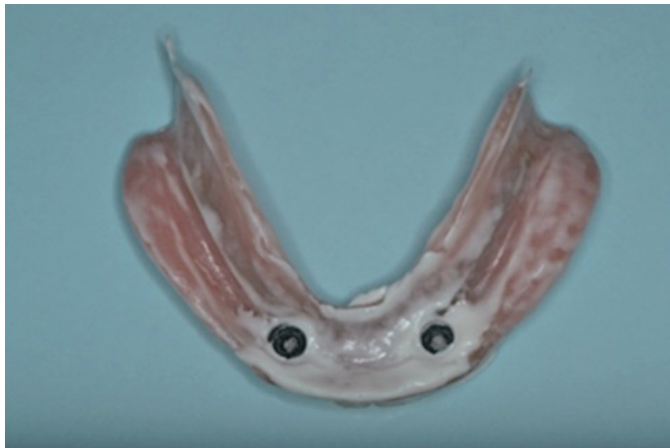No. 15

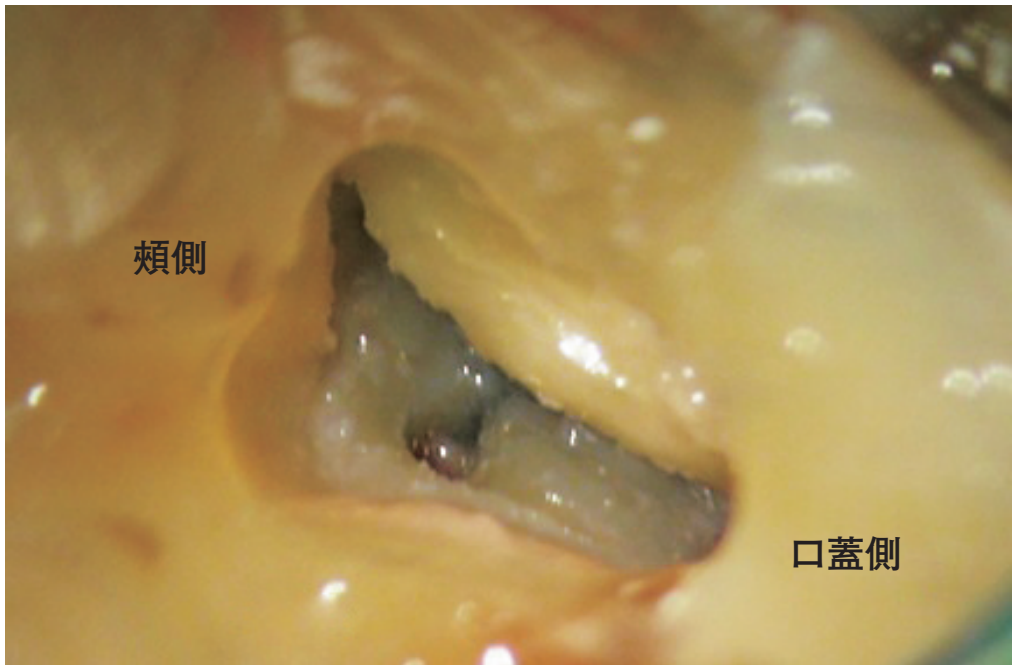(D 問題 53)

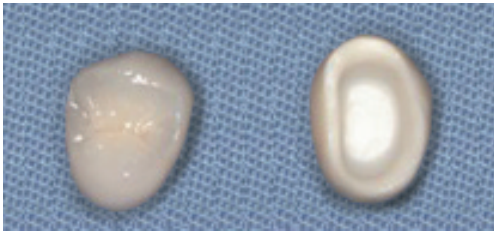C



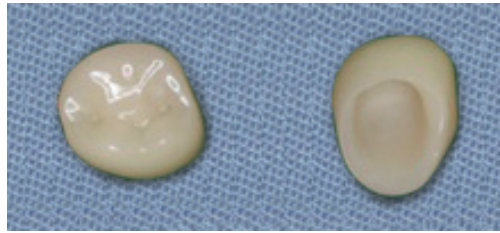D



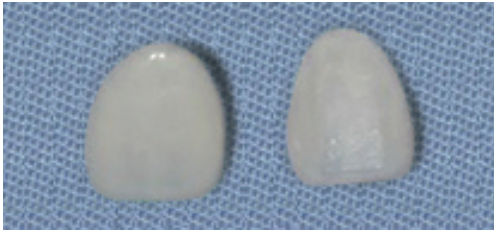




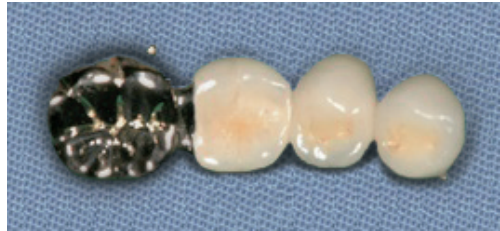ア



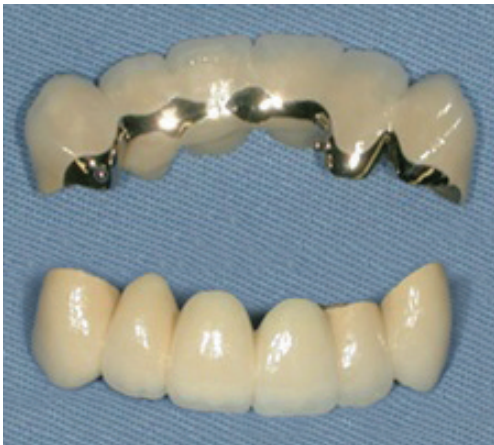イ



ウ



エ



オ

No. 18

(D 問題 60)

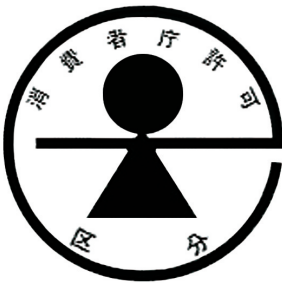ア



イ



ウ



エ



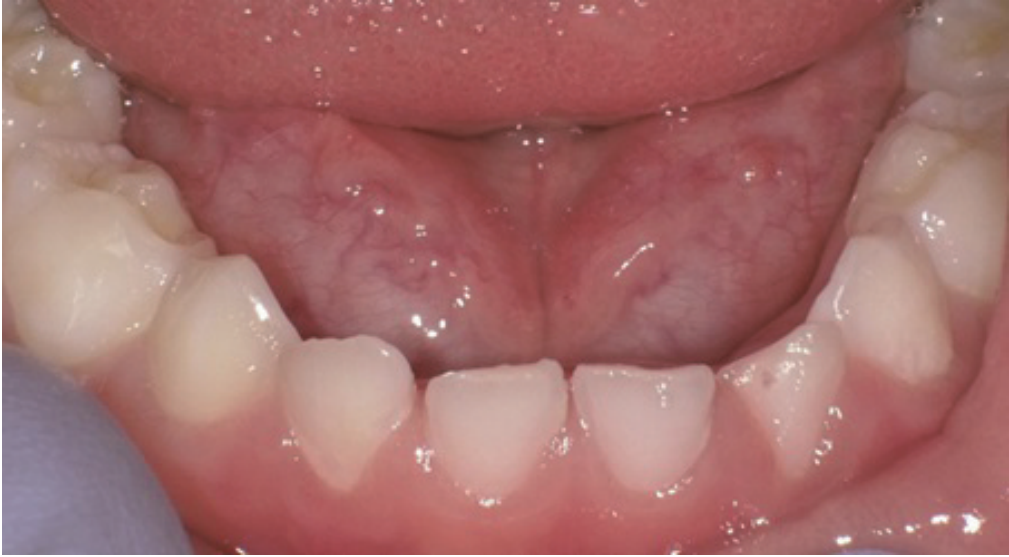オ



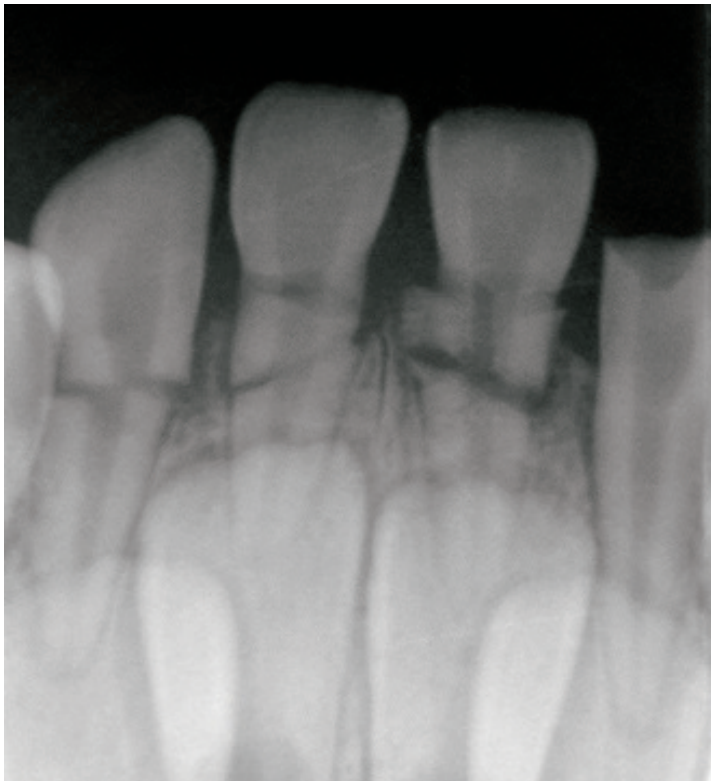
No. 19

(D 問題61)

A



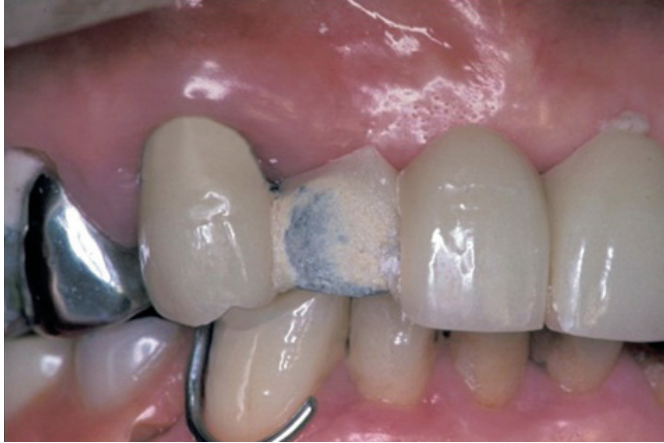B



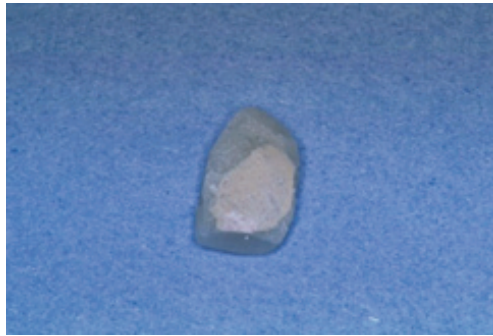
No. 20

(D 問題 62)

A

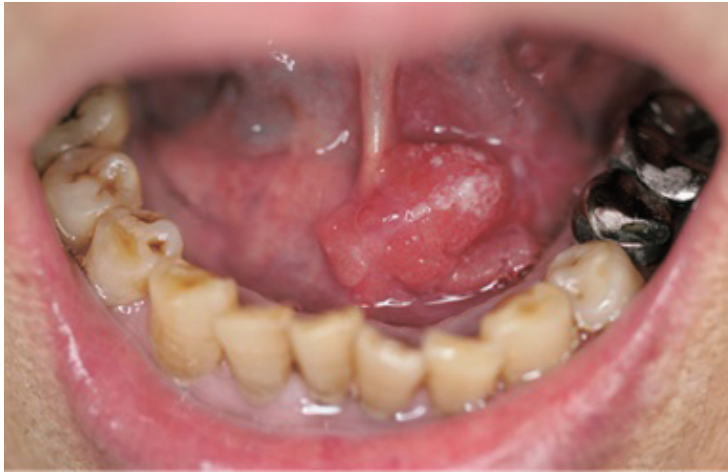

B

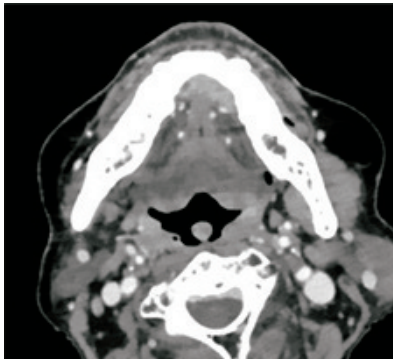


余 白

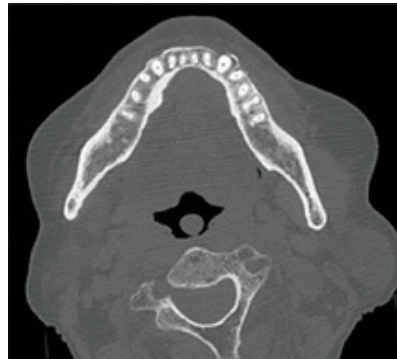A



B

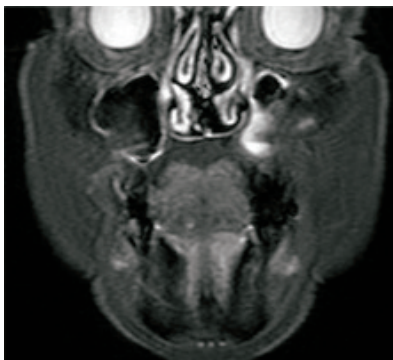


造影 CT 横断像

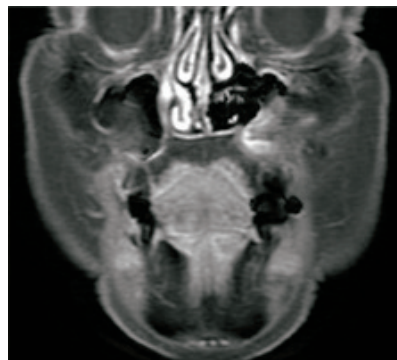


骨表示 CT 横断像

C



脂肪抑制 T2 強調冠状断像



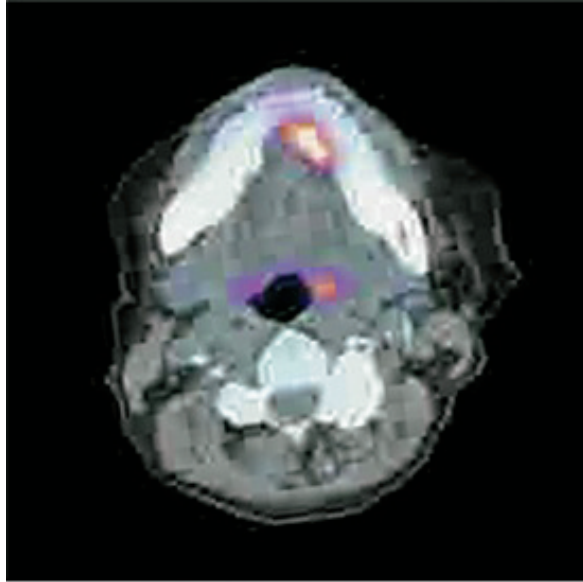
脂肪抑制造影 T1 強調冠状断像



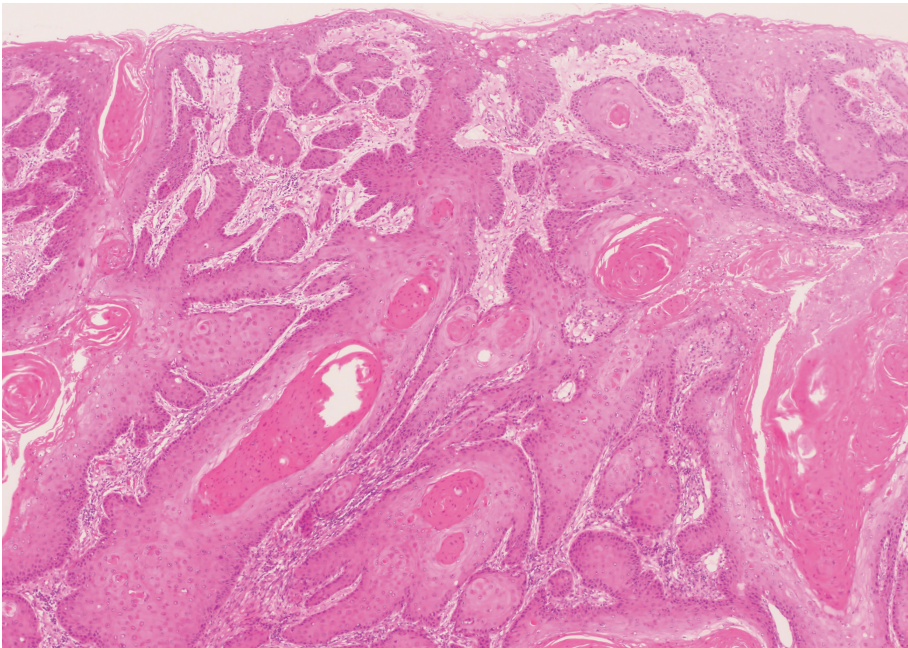
No. 21

(D 問題 65)

D



E



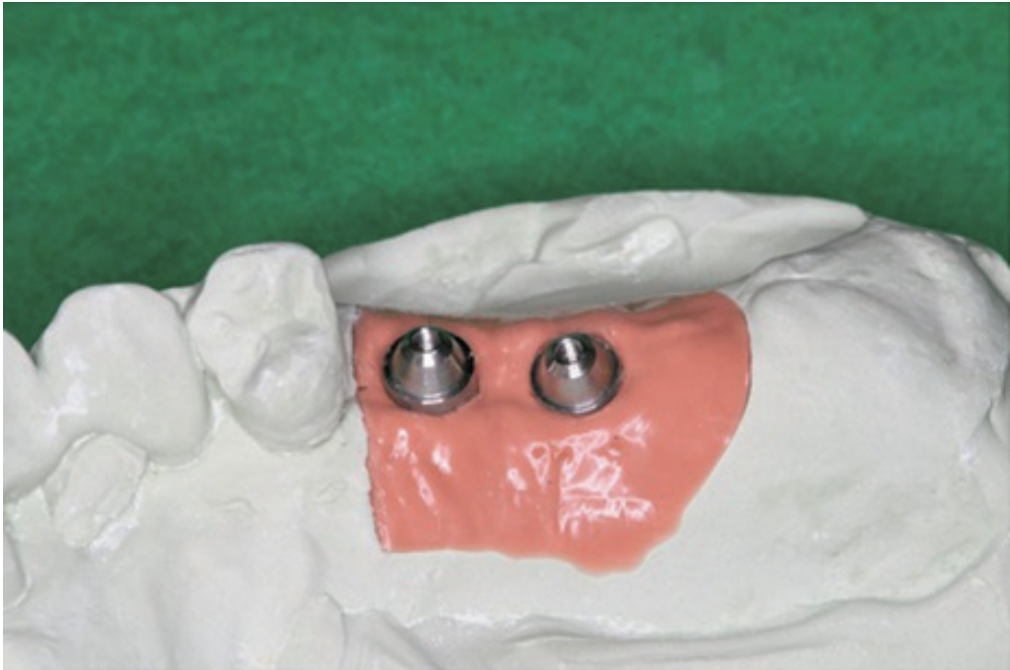No. 22

(D 問題 66)

A



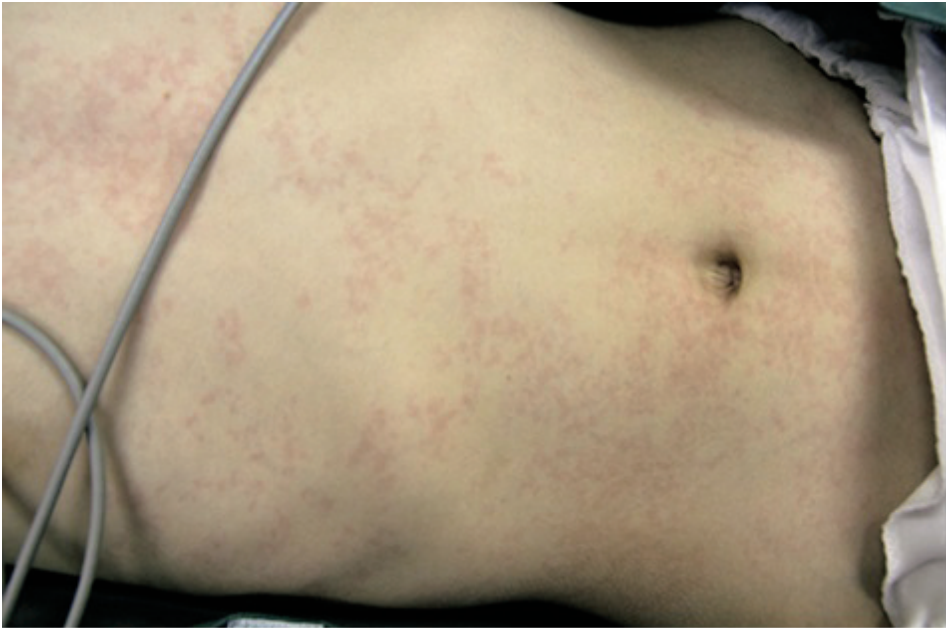B



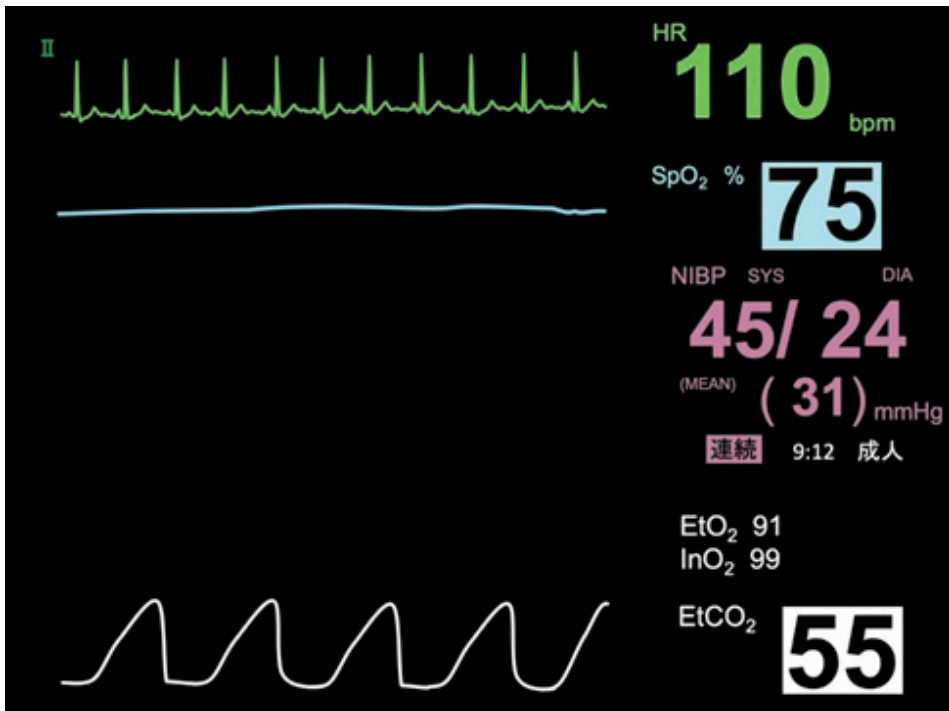
No. 23

(D 問題 68)

A



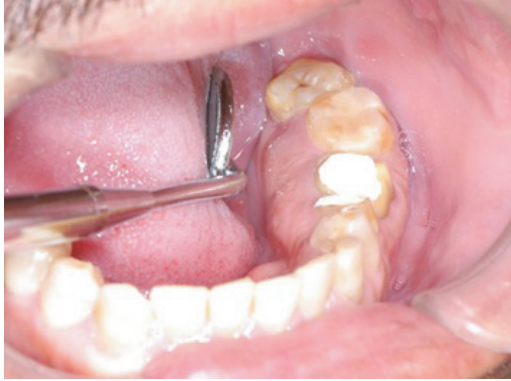B



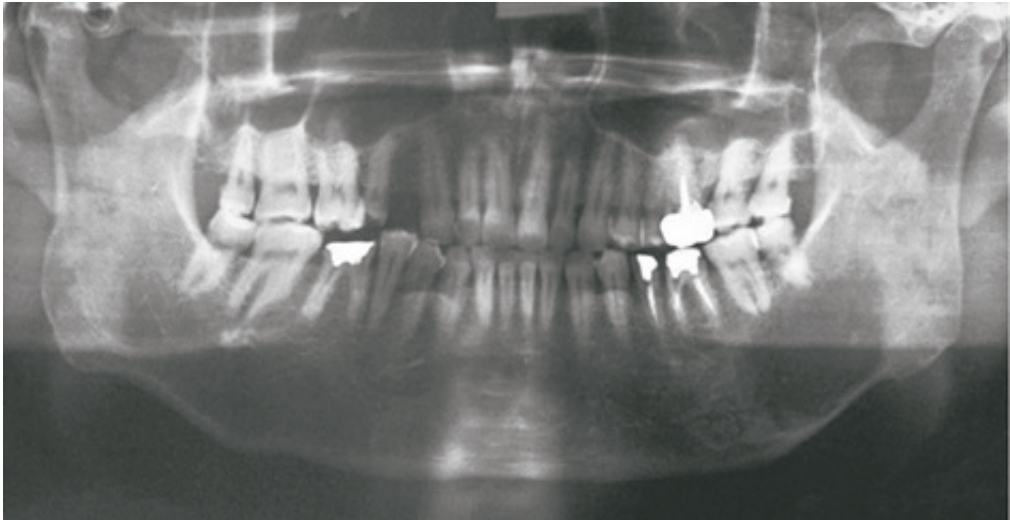
No. 24

(D 問題 72)

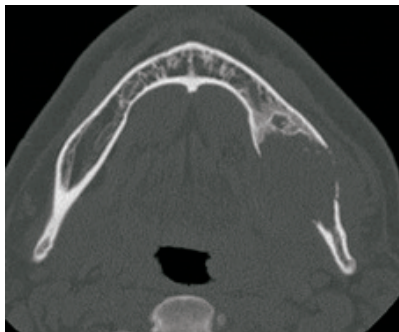A



B



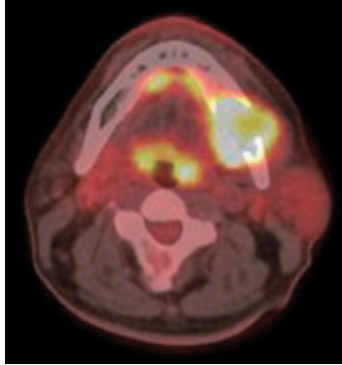
C



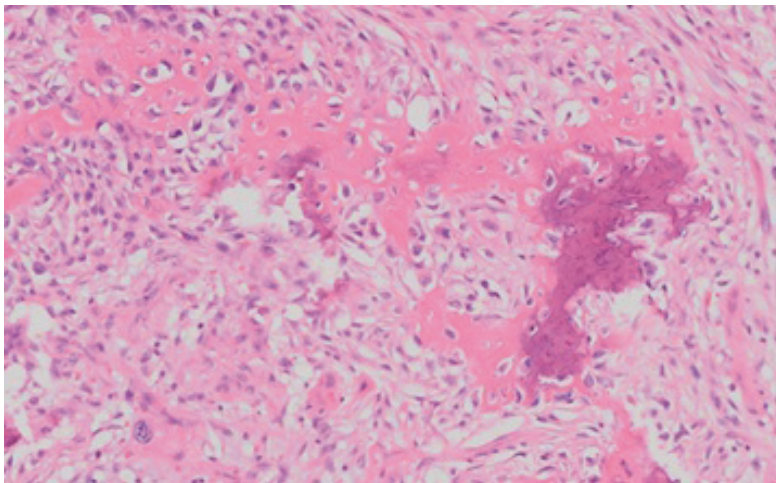
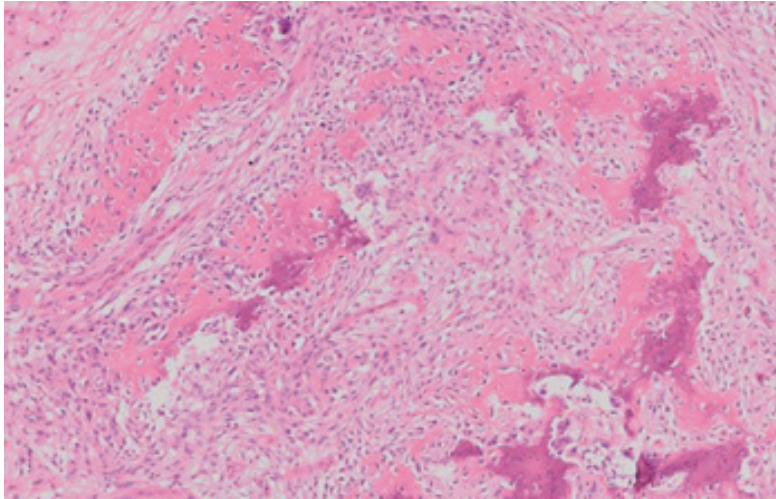
No. 24

(D 問題 72)

D



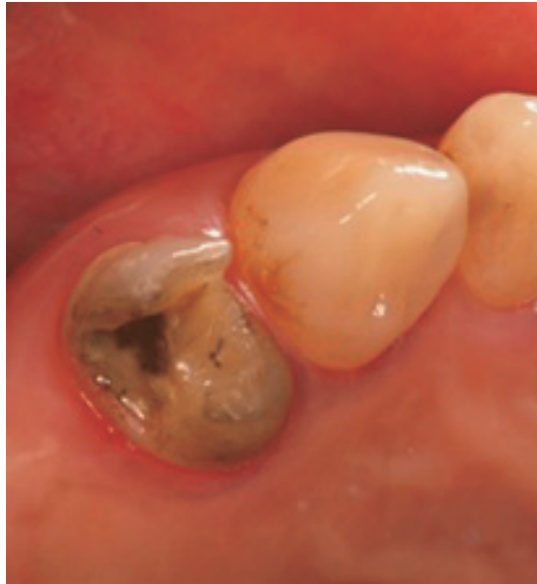E



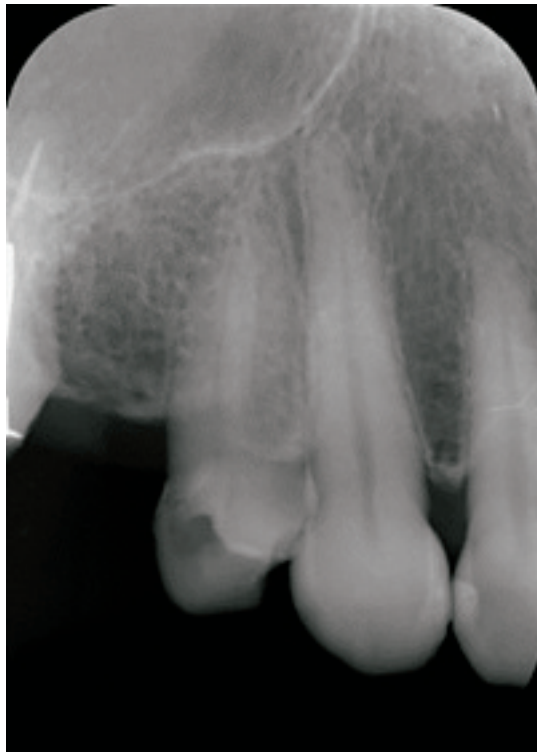No. 25

(D 問題 74)

A



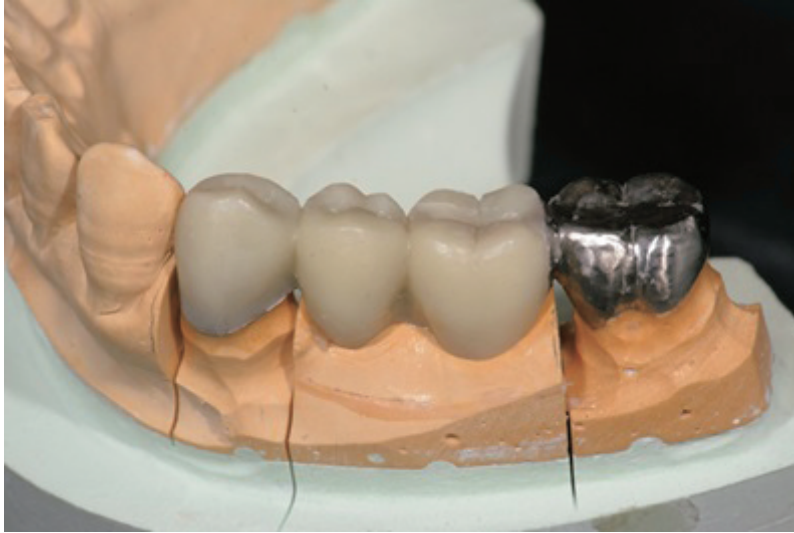B



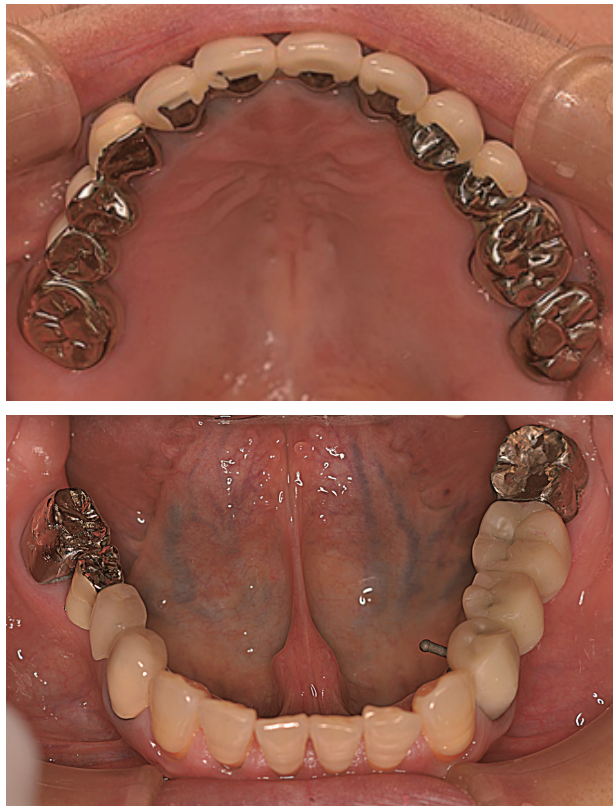No. 26

(D 問題77)

A

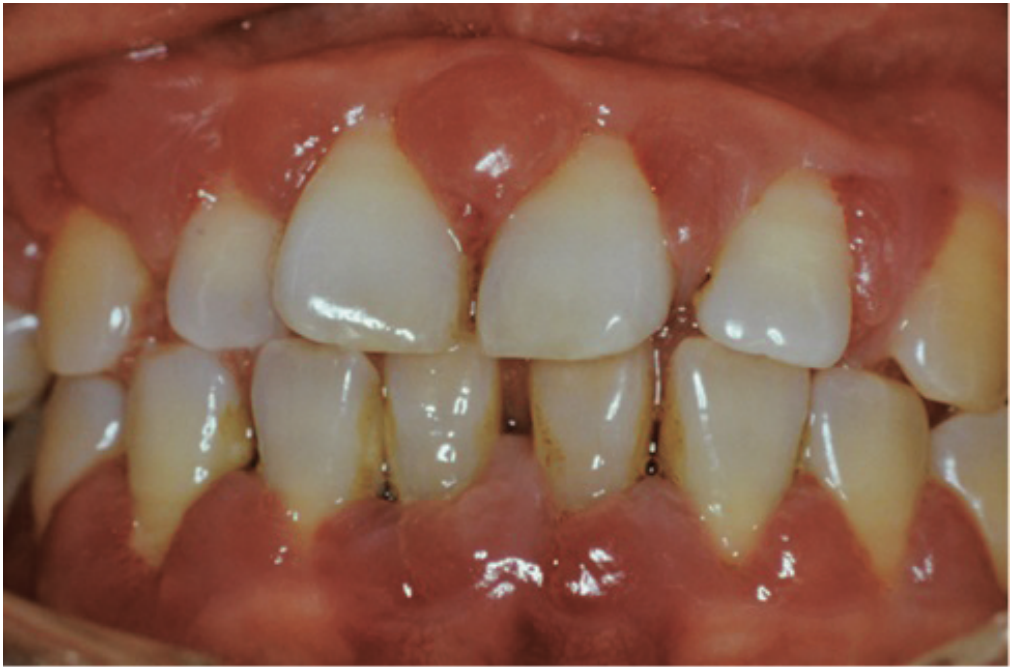

B



No. 27

(D 問題 78)

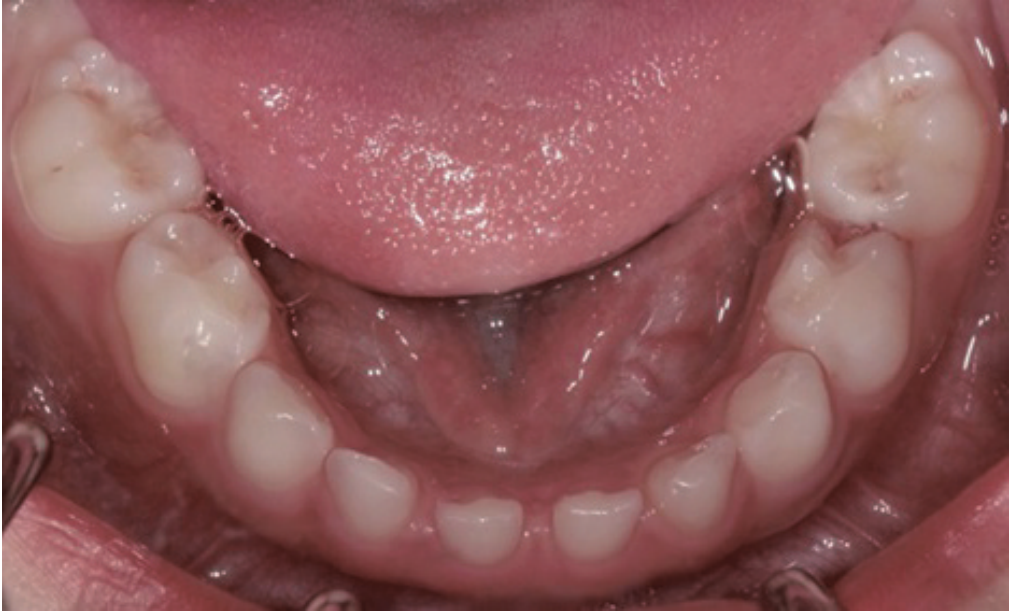



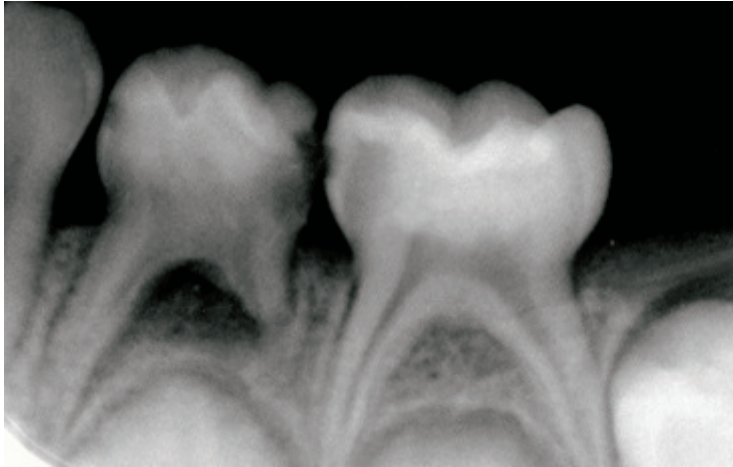
No. 28

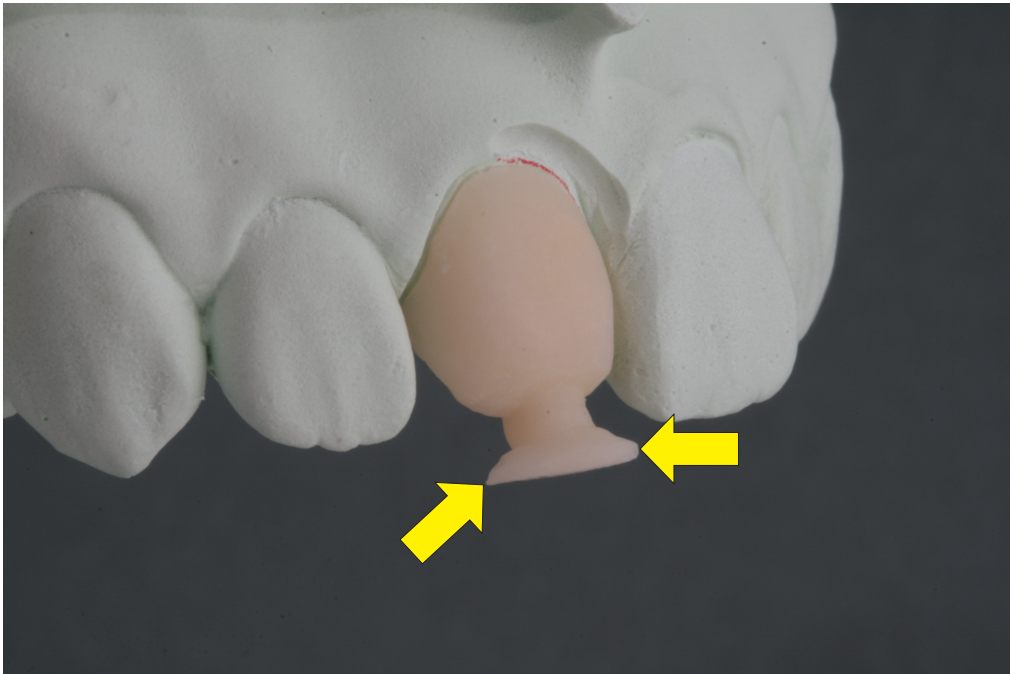
(D 問題 80)

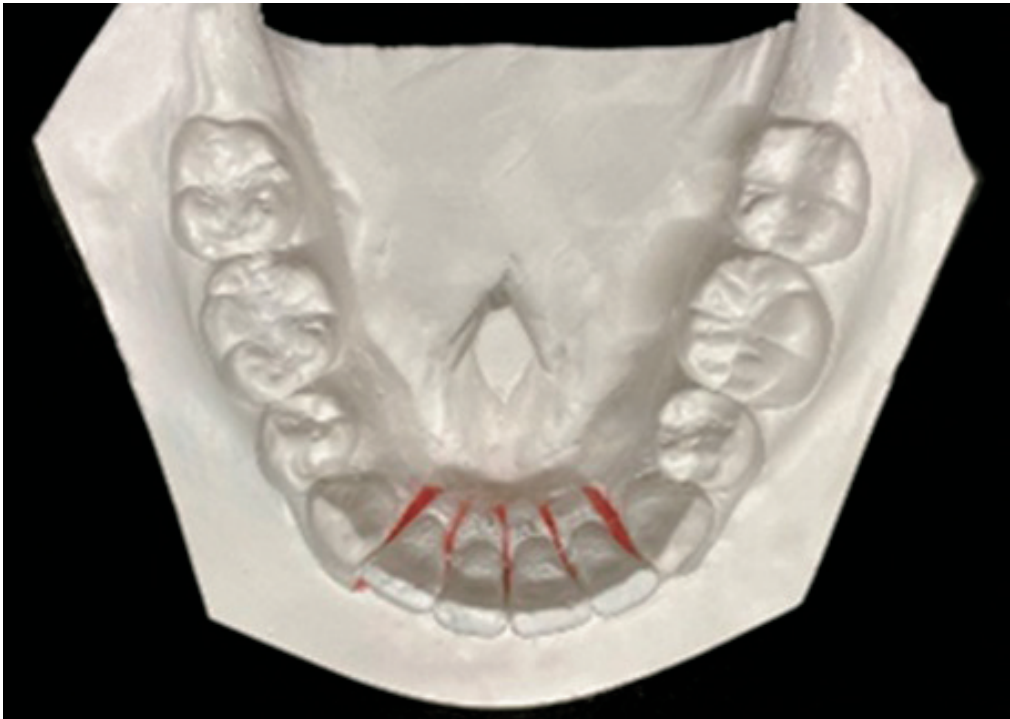A



B



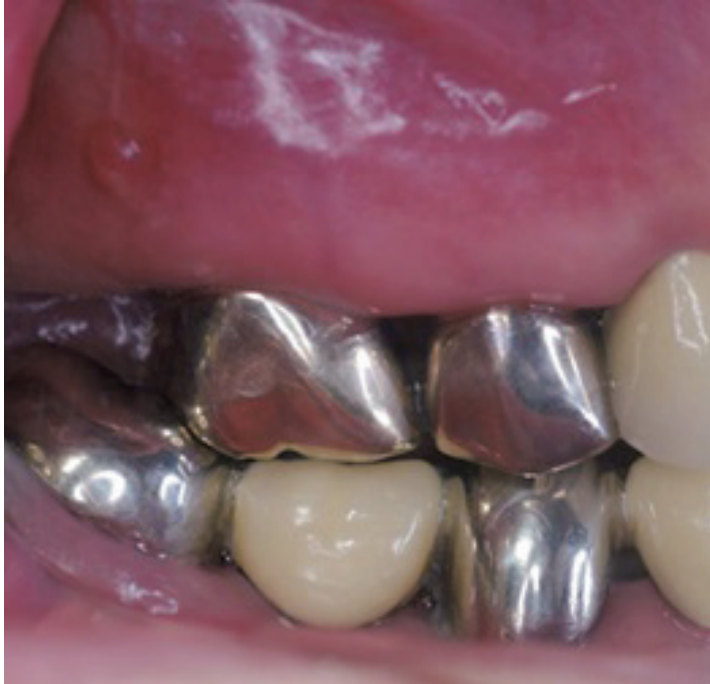



No. 31

(D 問題 89)

A



B

