

114

C

別 冊

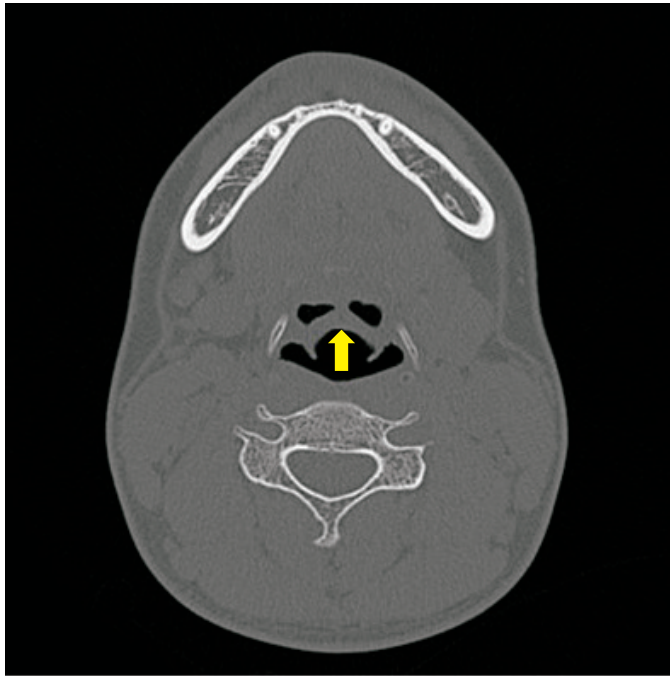





No. 1

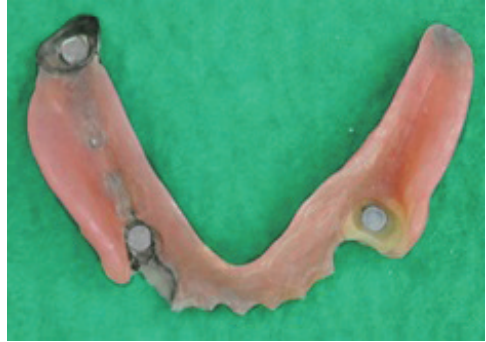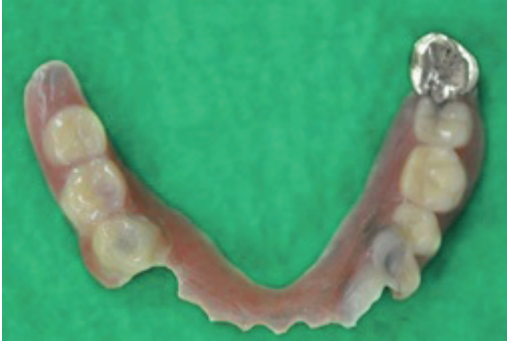(C 問題 10)



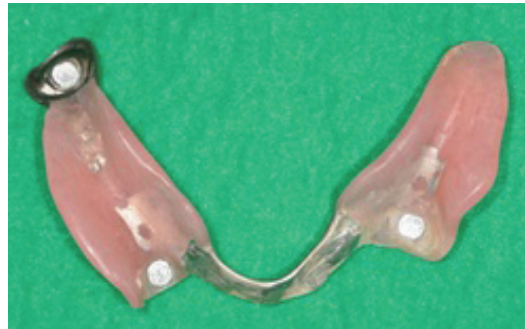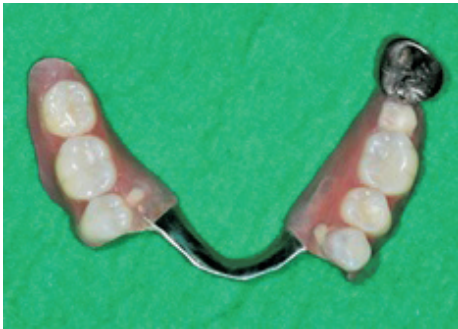No. 2

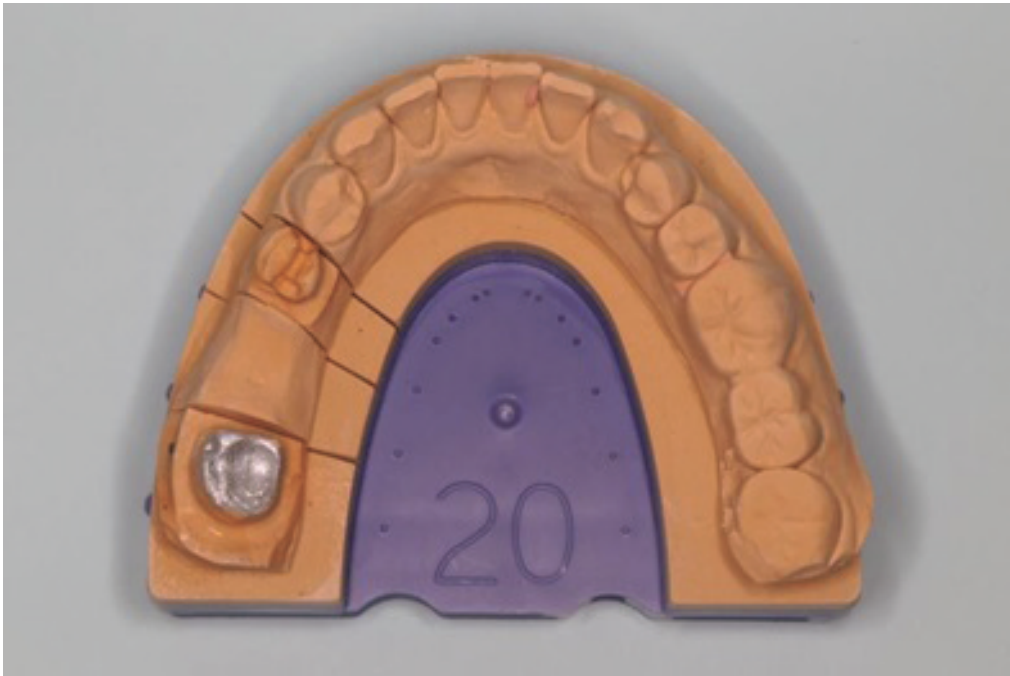
(C 問題 22)

A



B

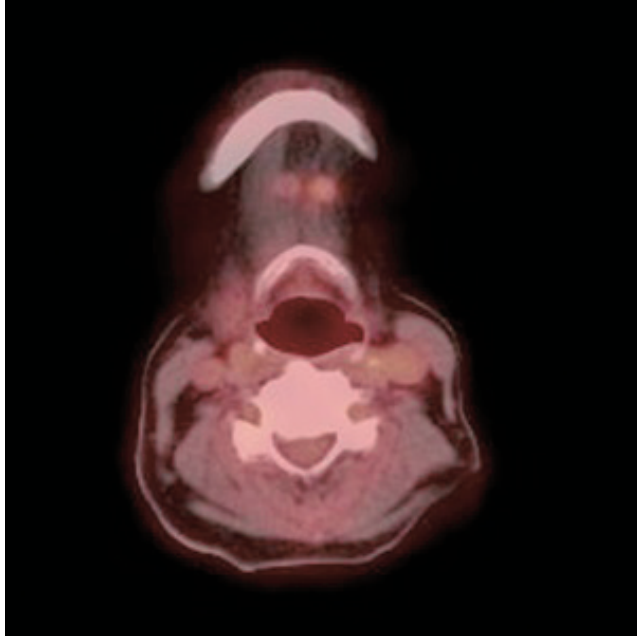




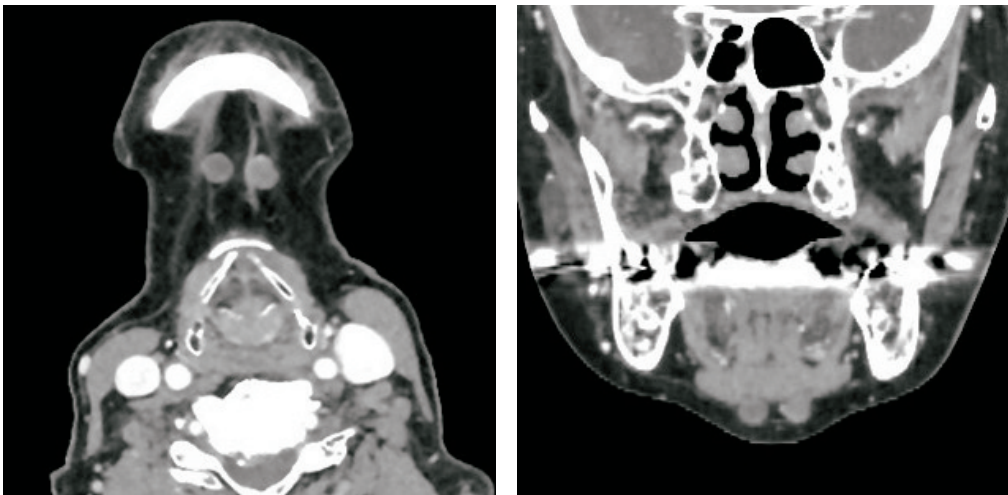
No. 4

(C 問題 25)

A



B

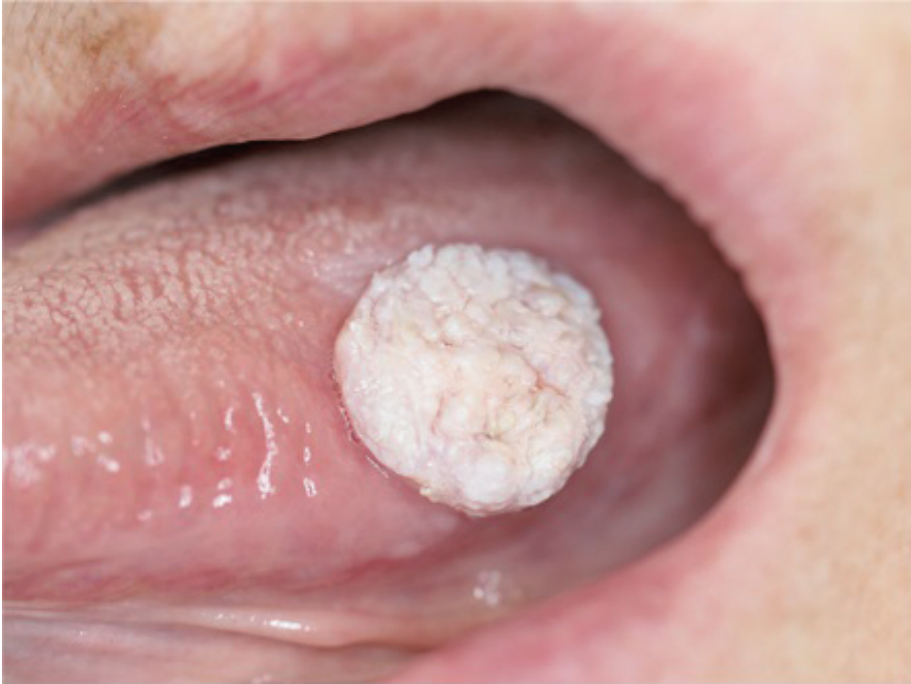



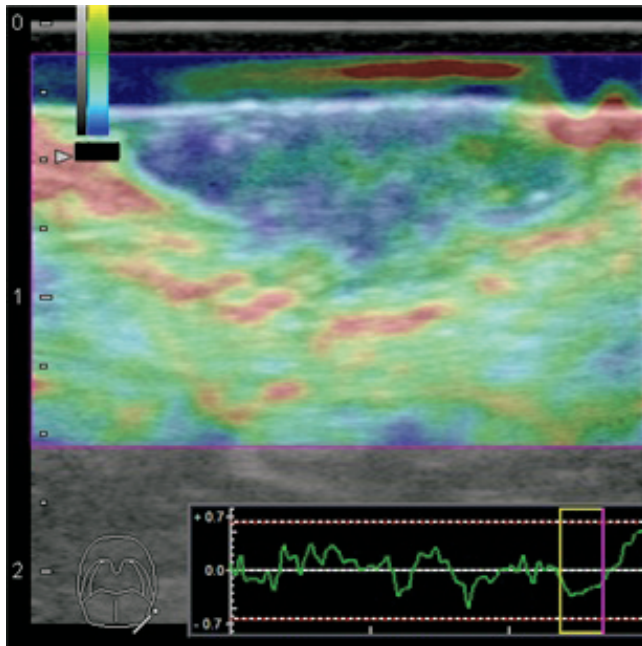
No. 5

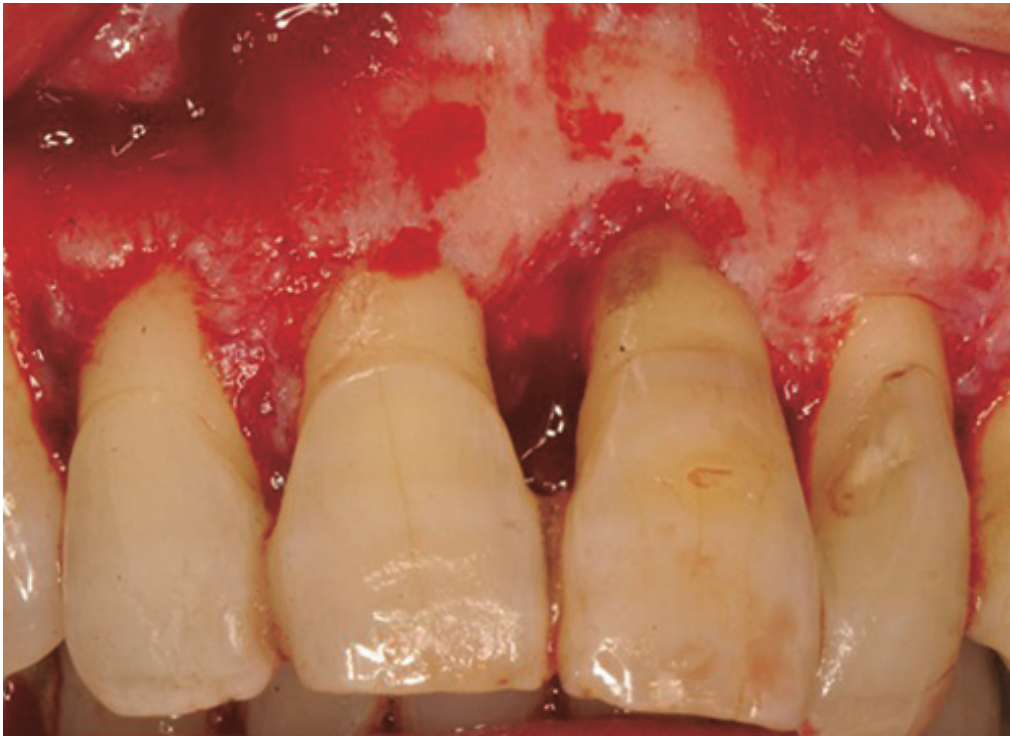(C 問題27)

A



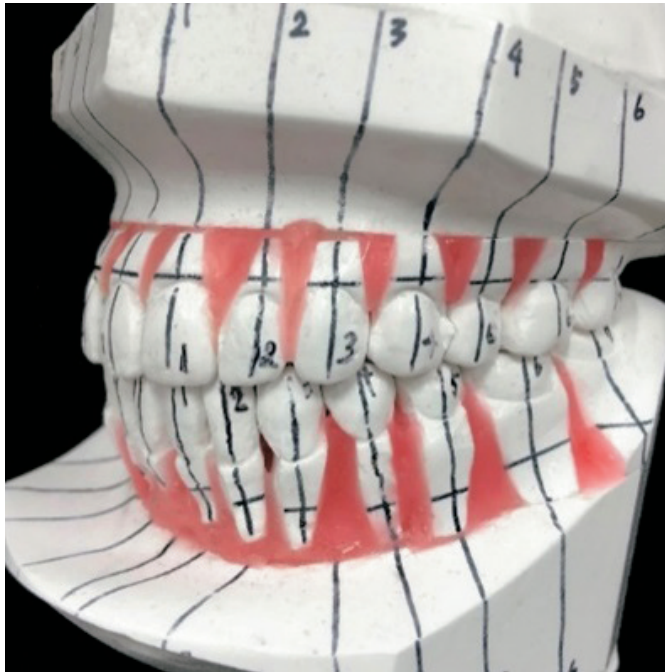
B





No. 7

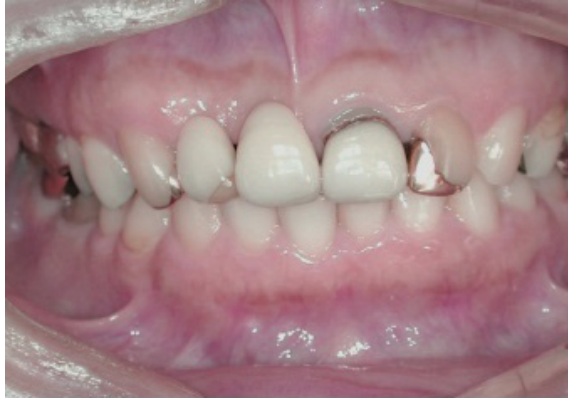(C 問題 36)



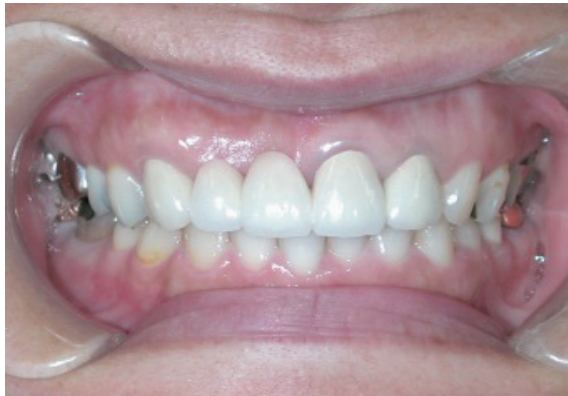No. 8

(C 問題 39)

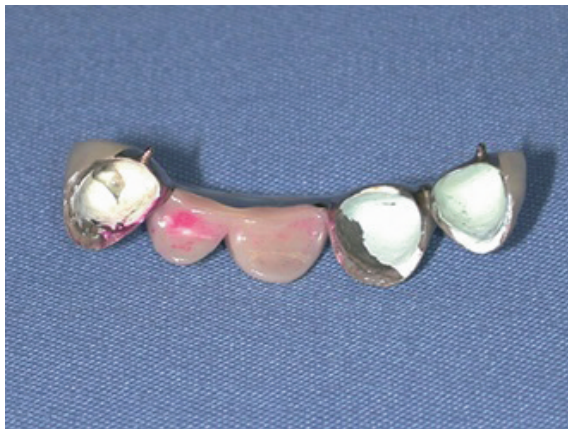A



B



C

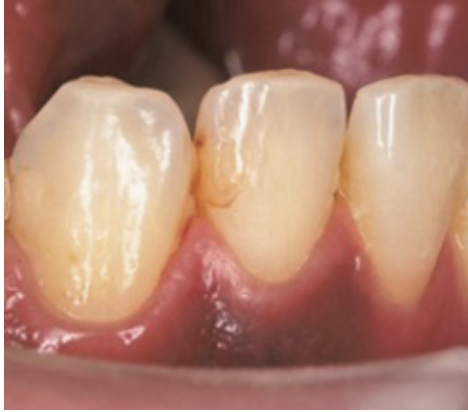

余 白

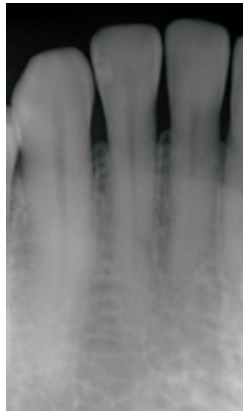
No. 9

(C 問題 40)

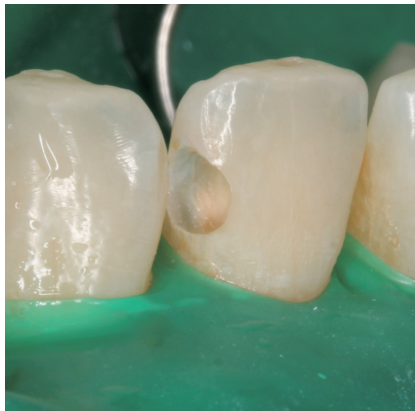A



B

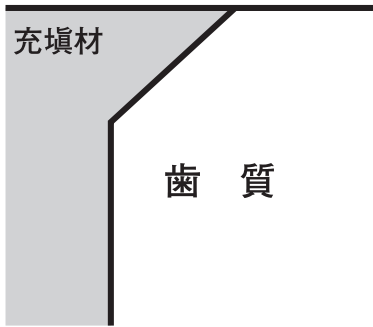


C

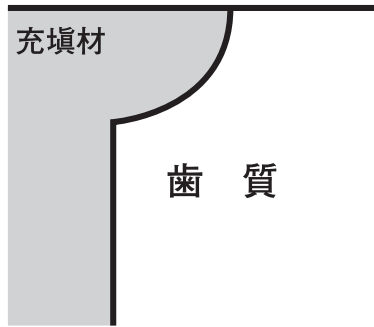


D

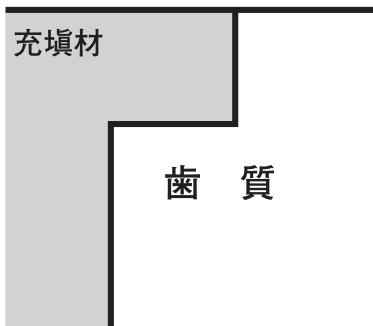
ア



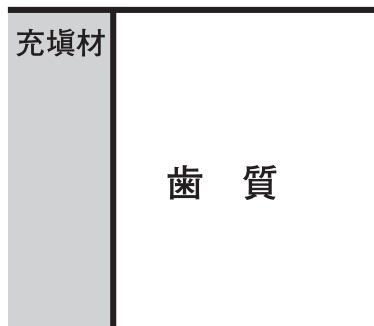
イ



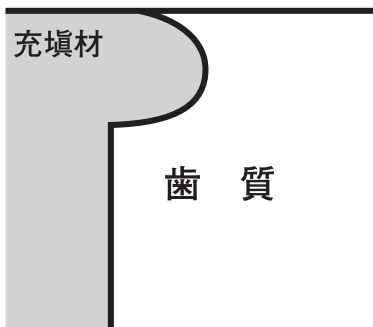
ウ



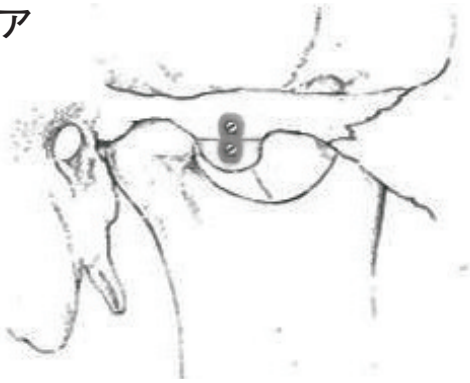
エ



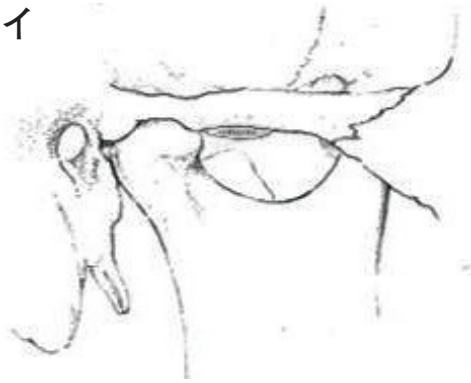
オ



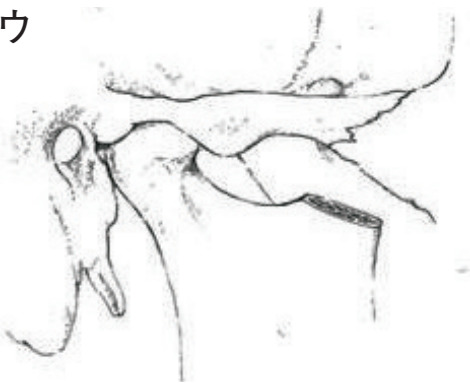
ア



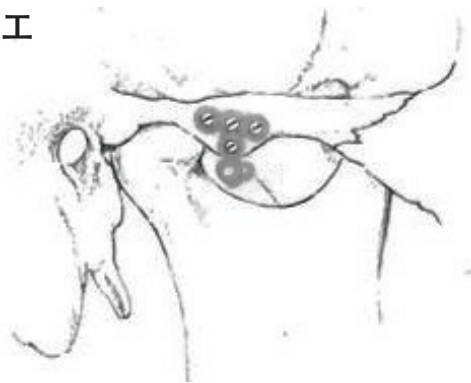
イ



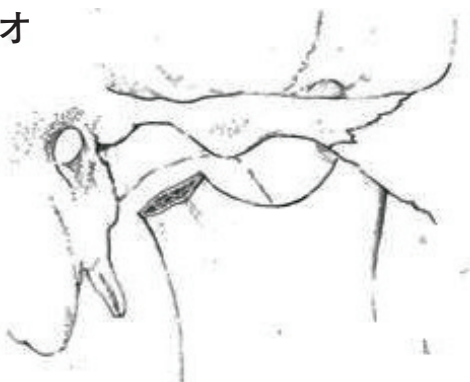
ウ



エ



オ

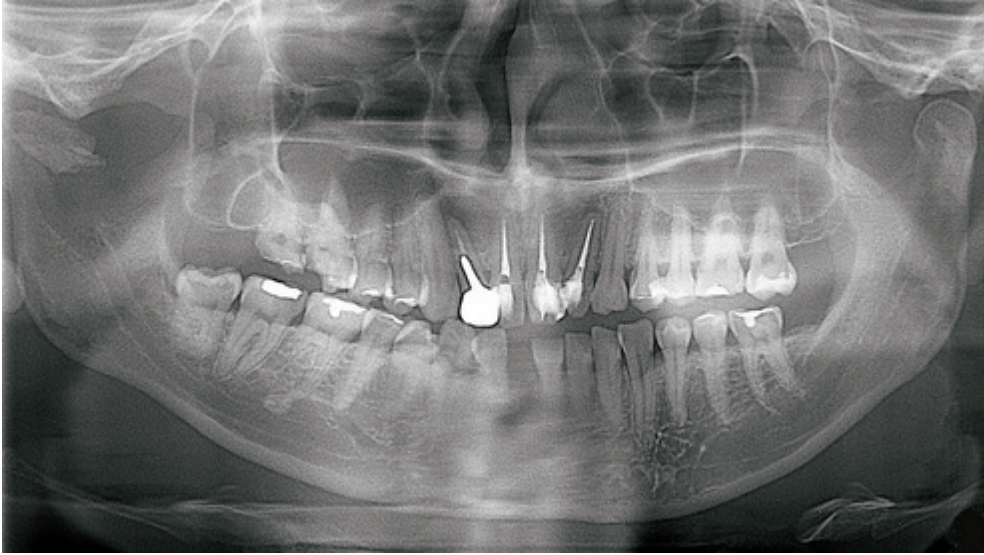




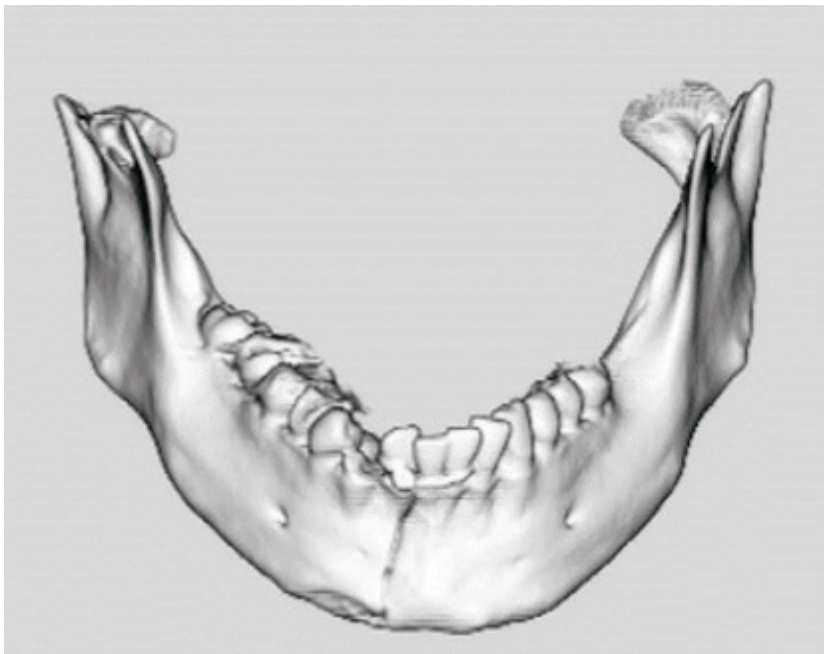No. 11

(C 問題 42)

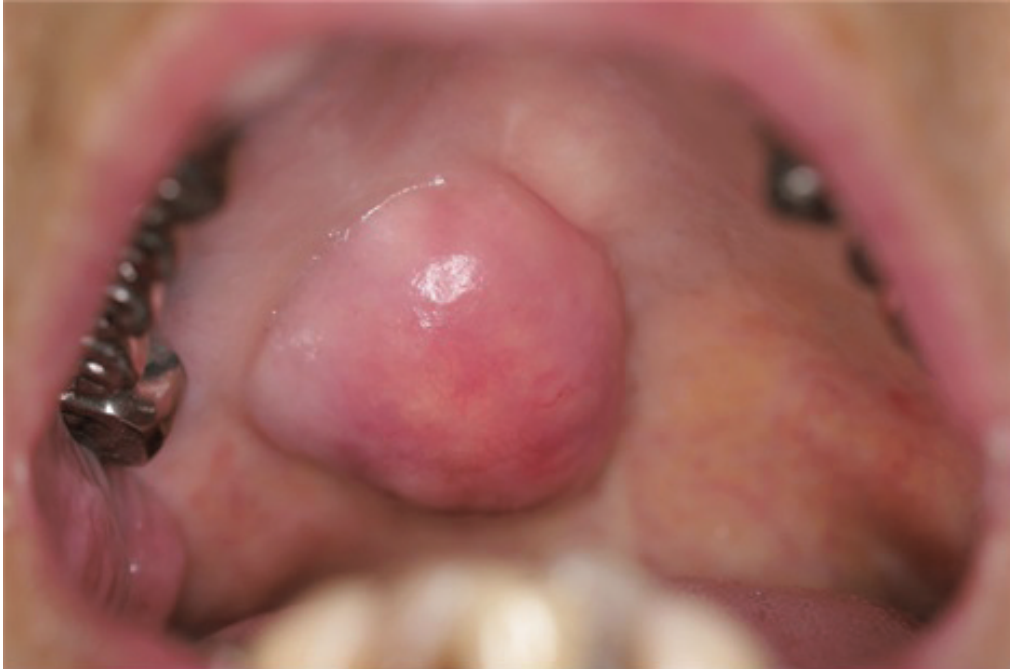A



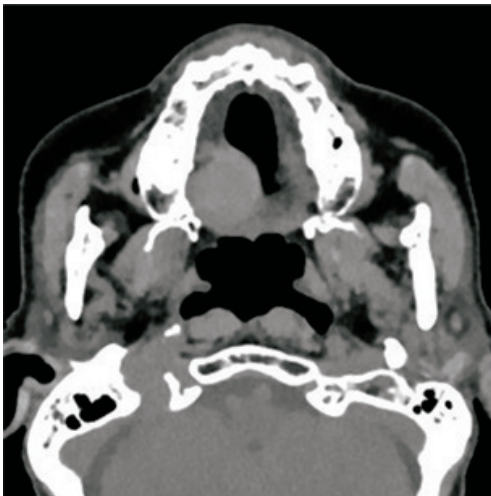
B



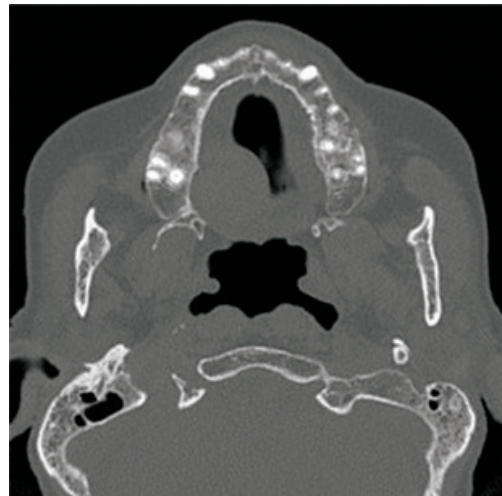
A



B



軟組織表示 CT 横断像

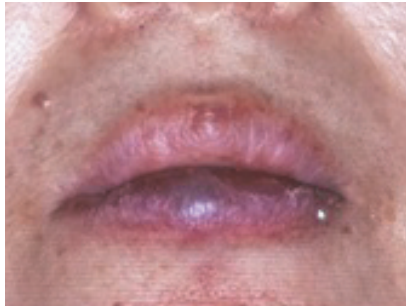

骨表示 CT 横断像

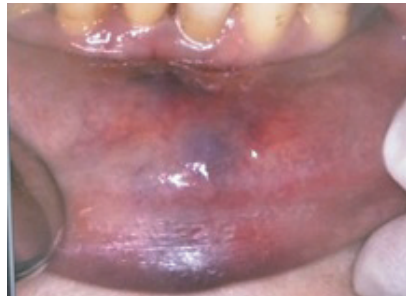No. 13

(C 問題 44)

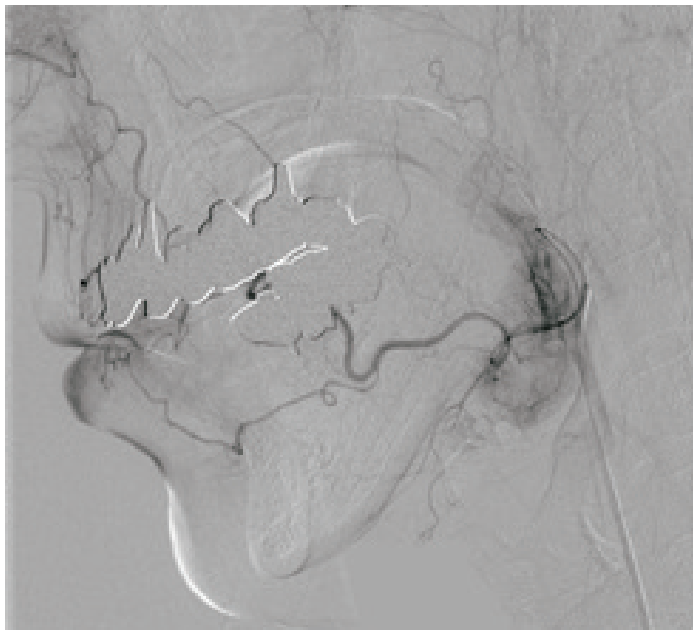A



B



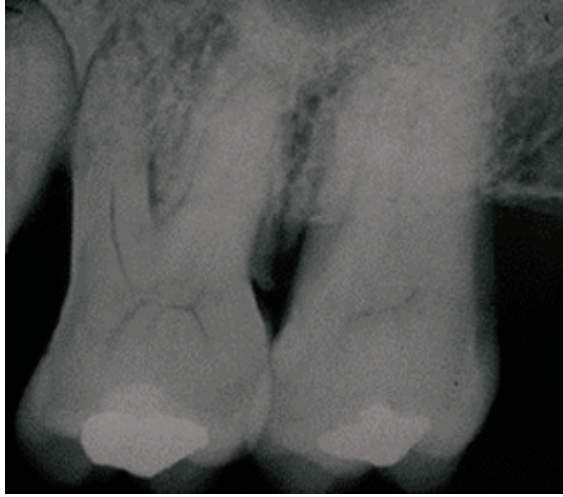C



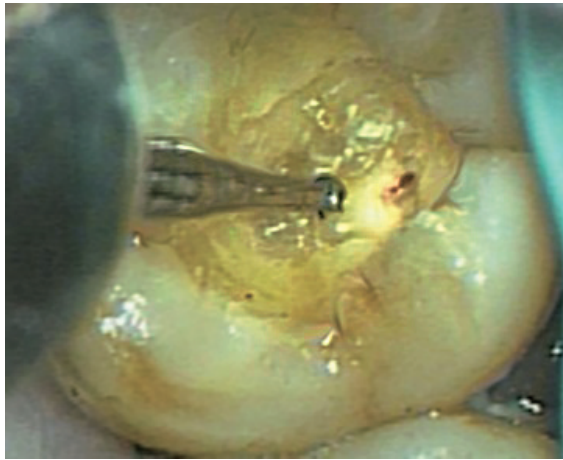
No. 14

(C 問題 45)

A



B

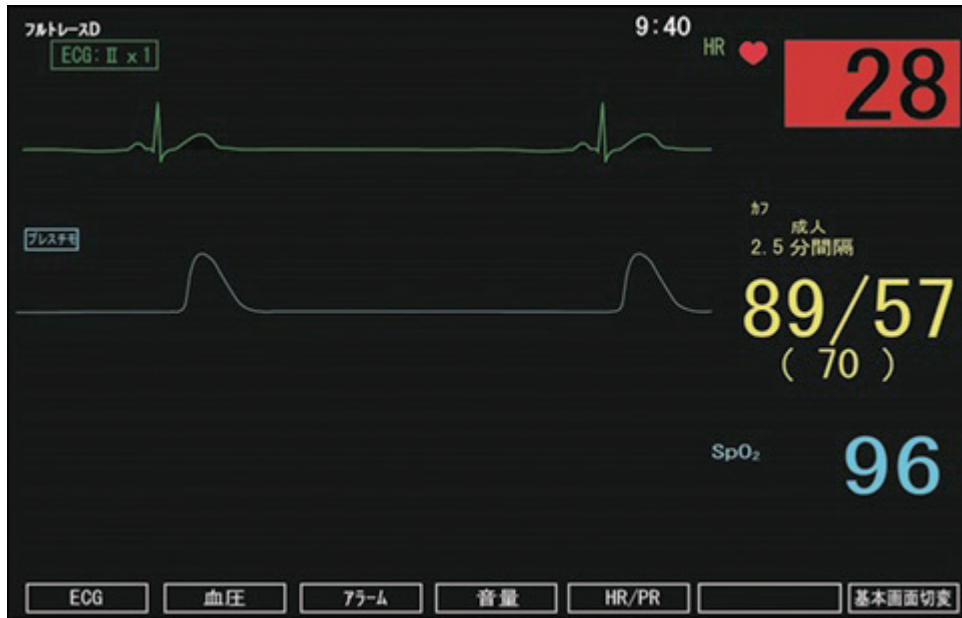


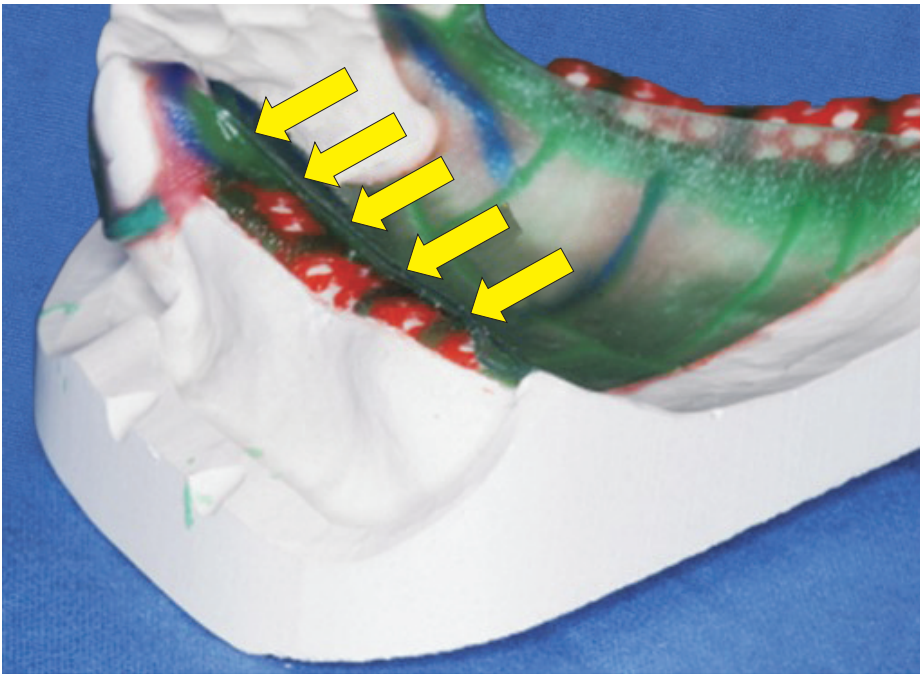
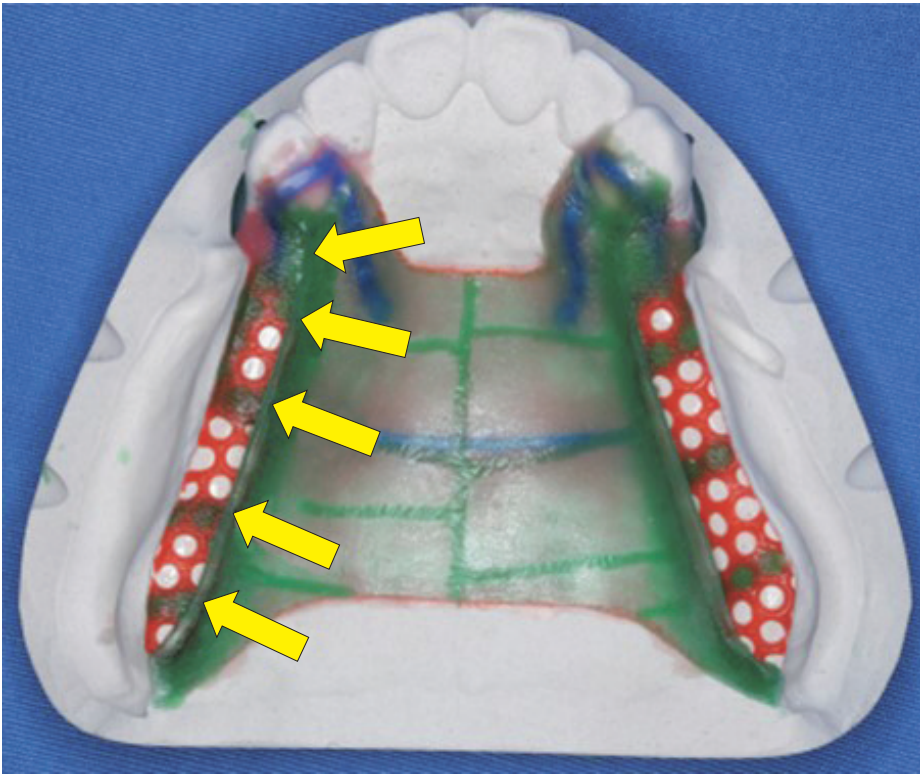


訓練前



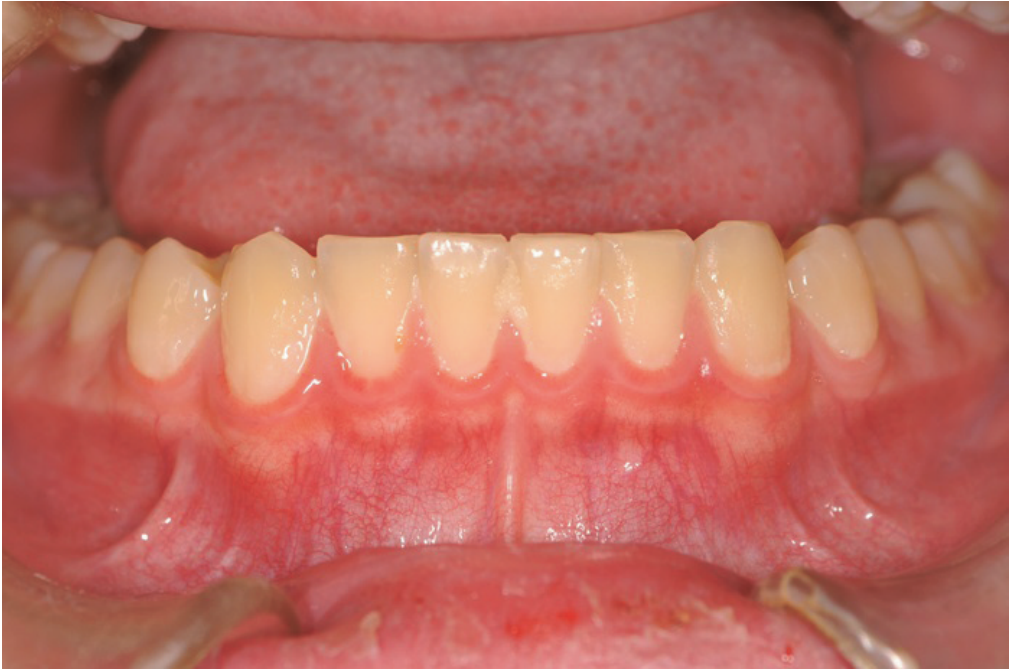訓練中





No. 18

(C 問題 49)





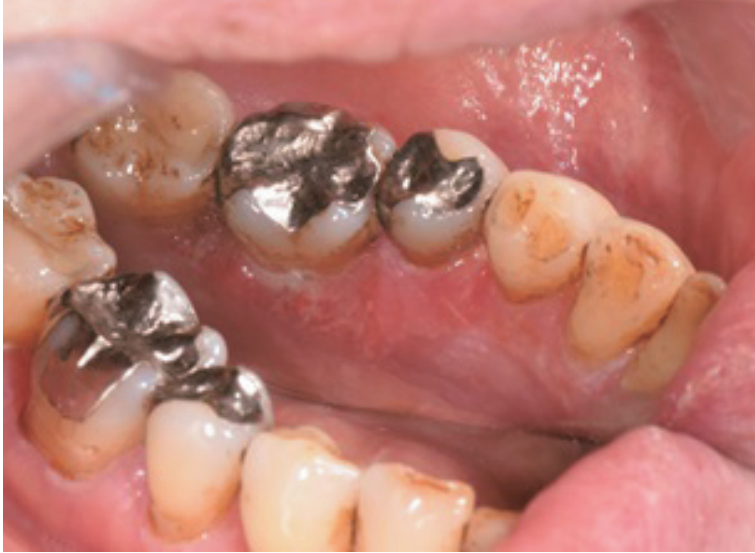余 白

No. 19

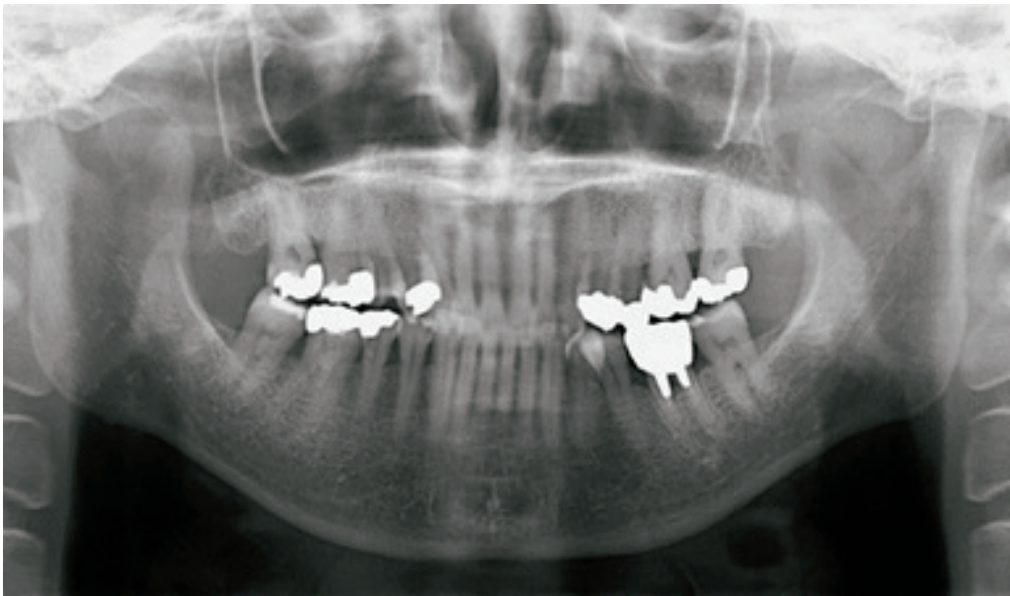(C 問題 52)

A

(ミラー像)



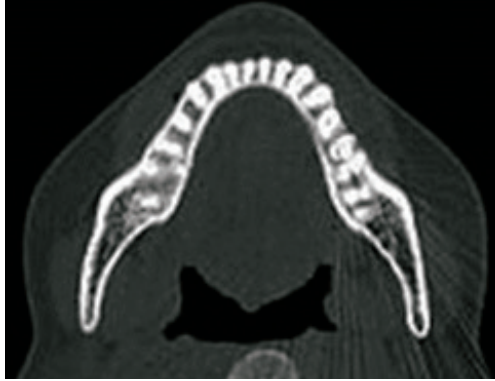
B



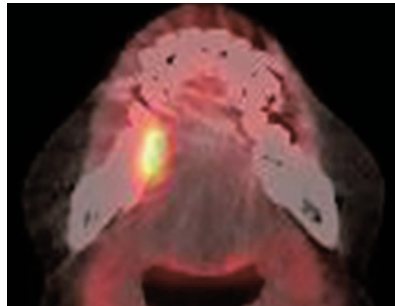
No. 19

(C 問題 52)

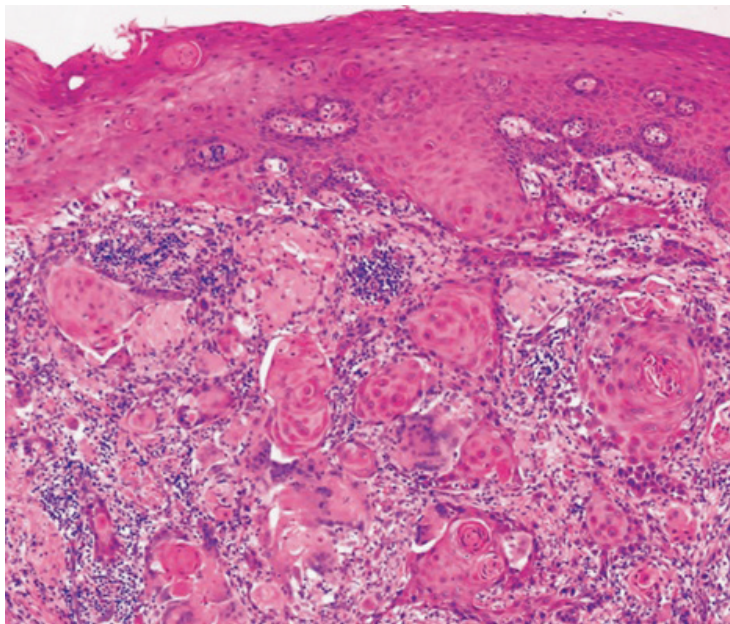
C



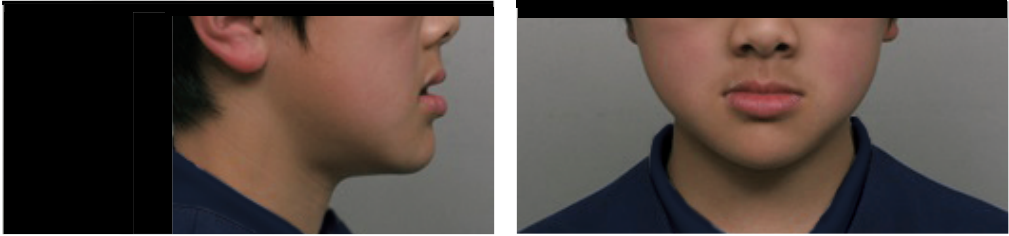D



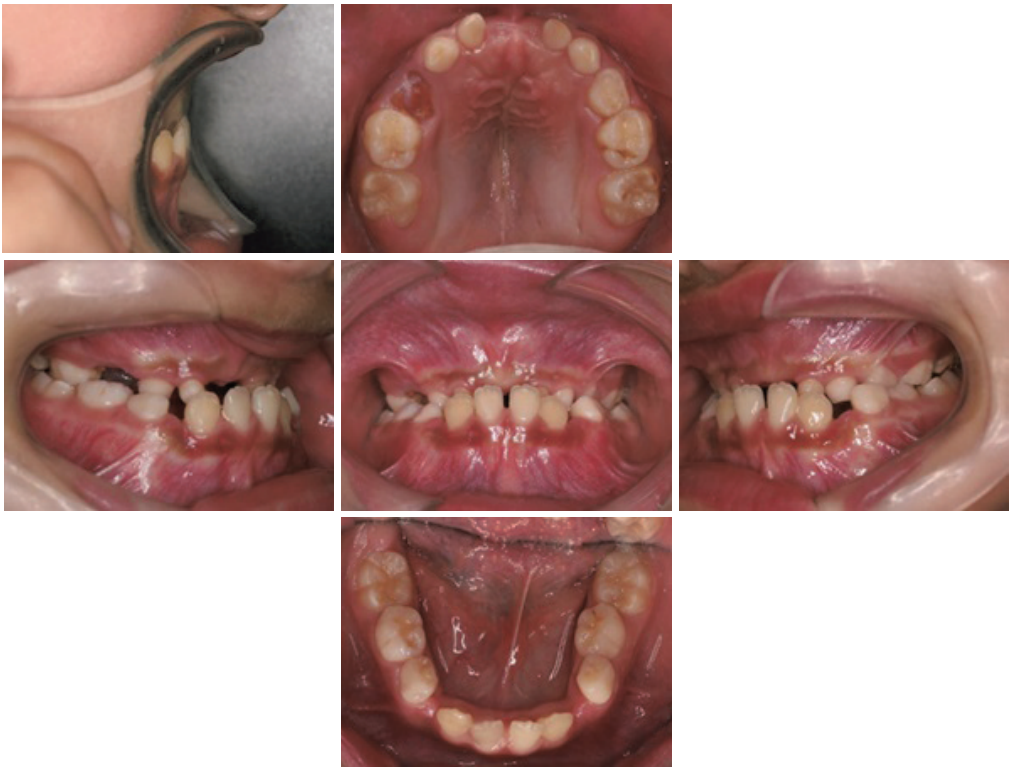E



A



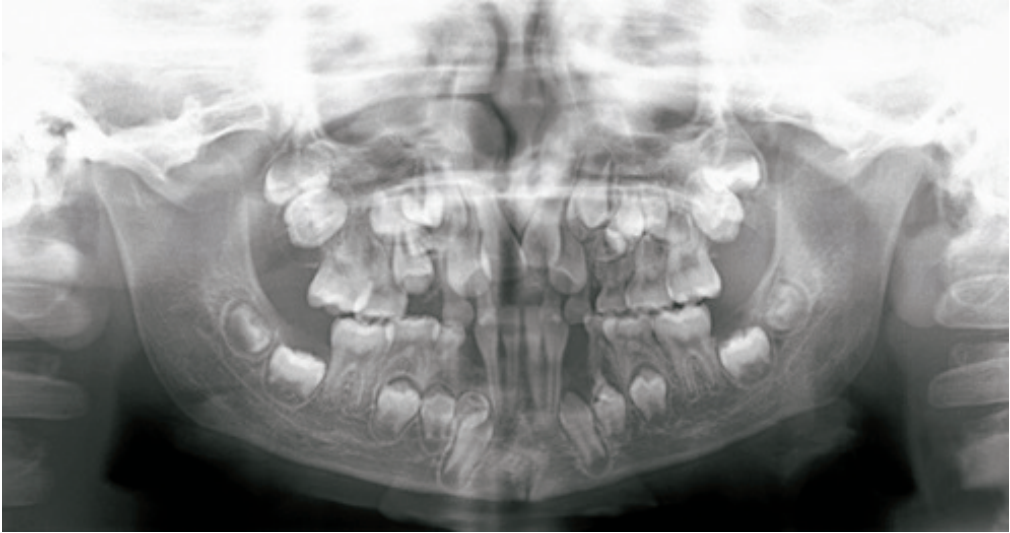
B



No. 20

(C 問題 53)

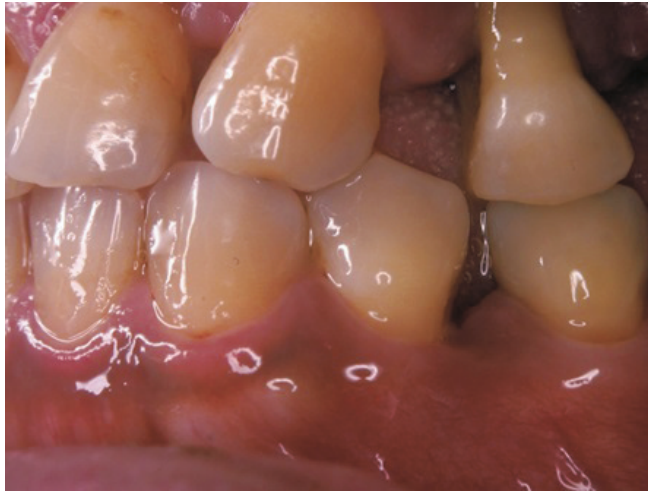C



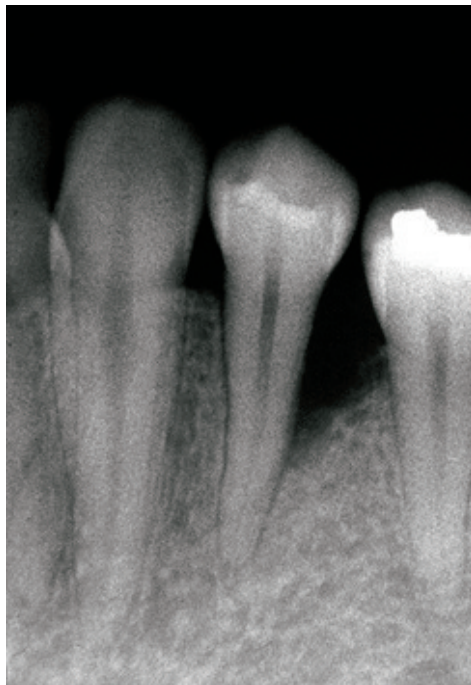No. 21

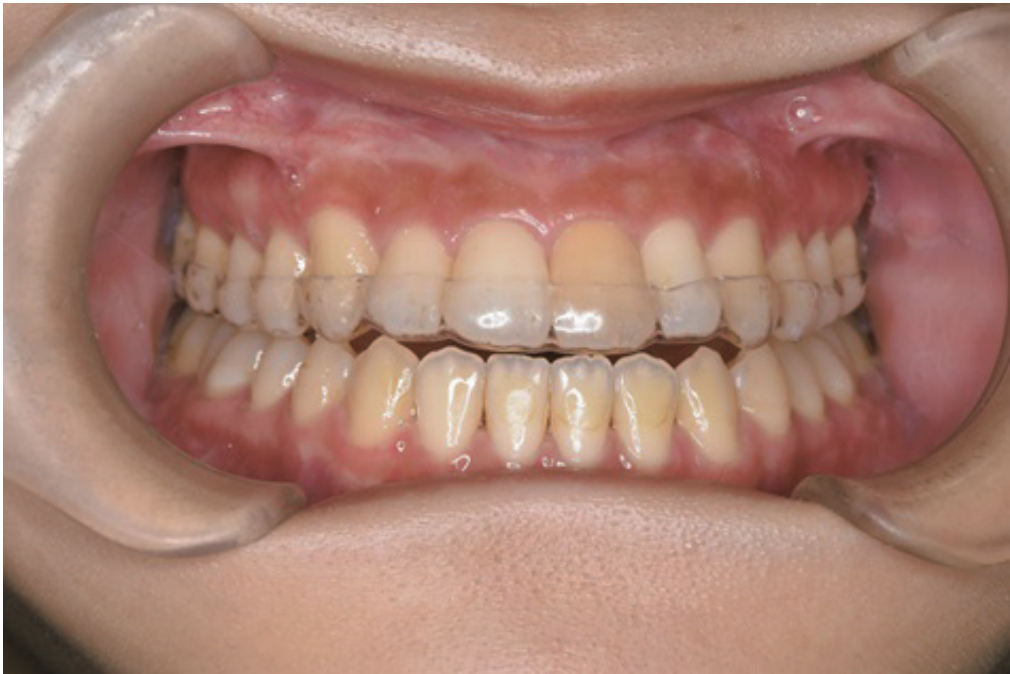(C 問題 55)


A



B





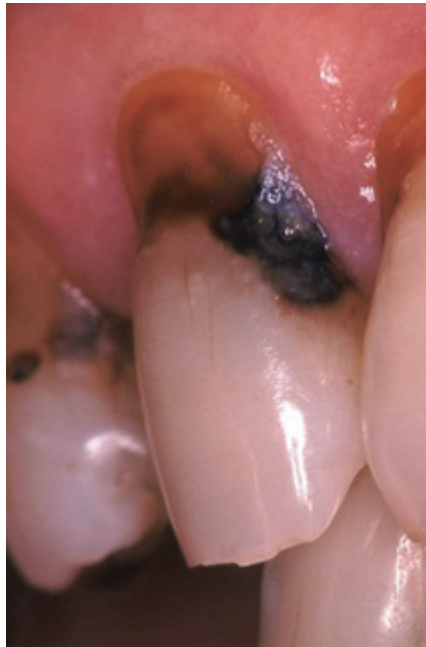





No. 24

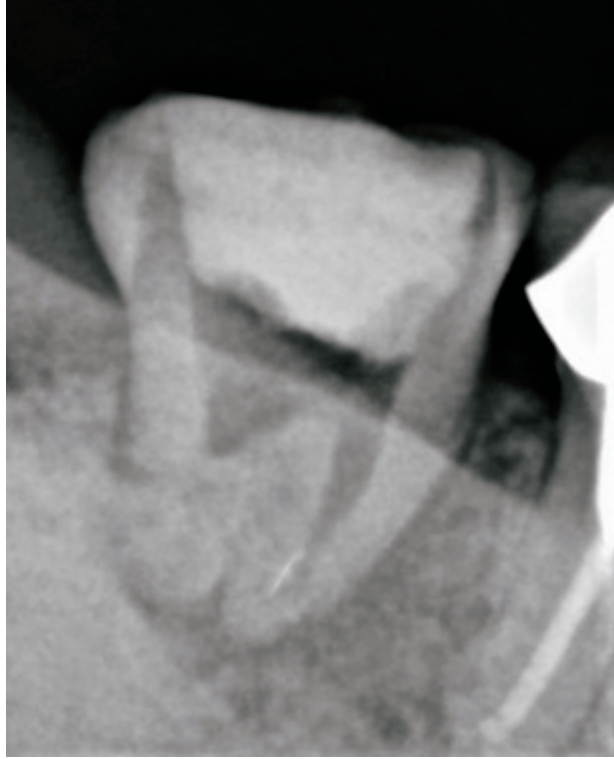(C 問題 59)



No. 25

(C 問題 62)

A

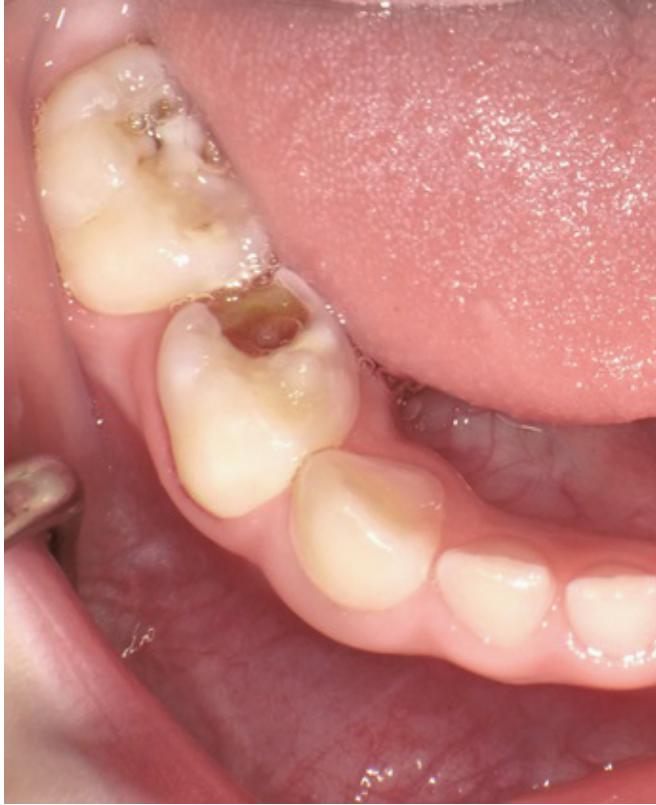

B

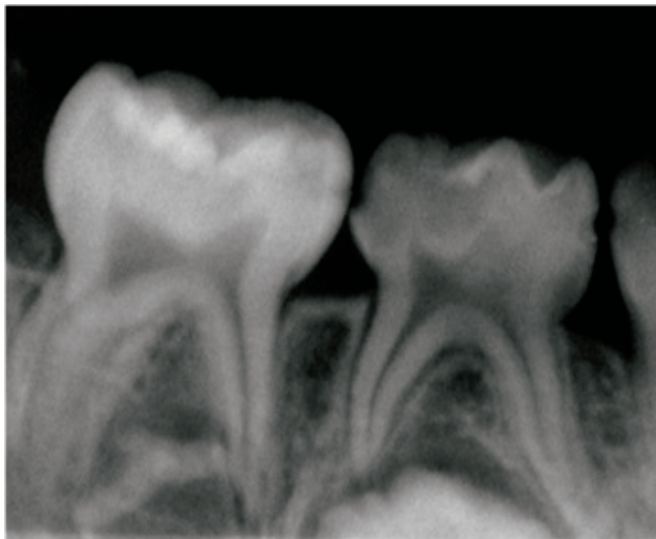


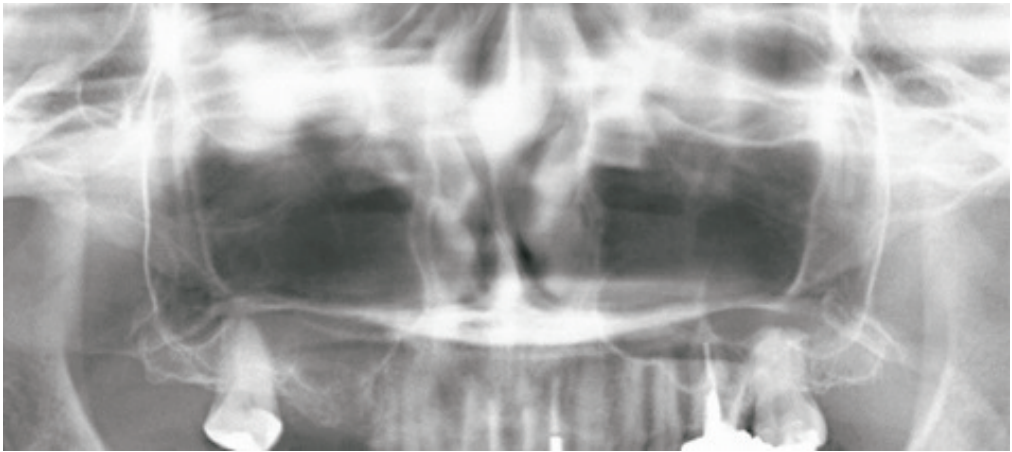
No. 26 (C 問題 63、64)

A

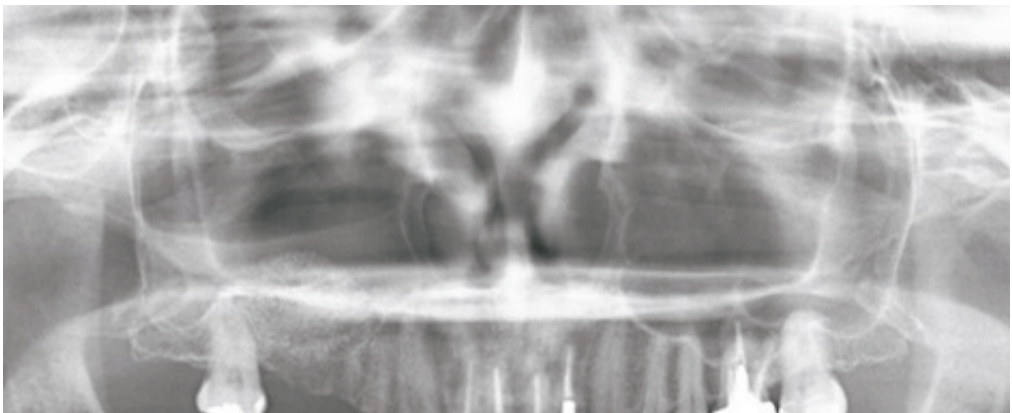


B



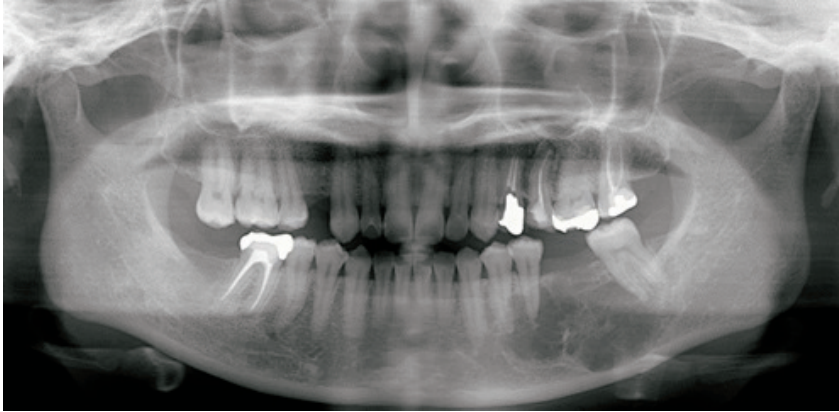


初診時

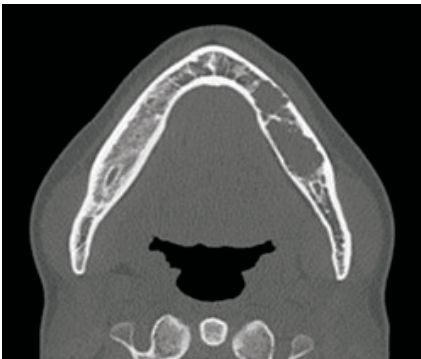

処置後

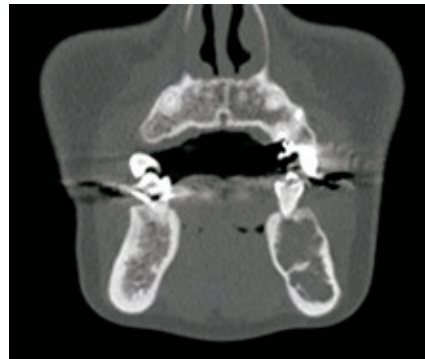
A



B

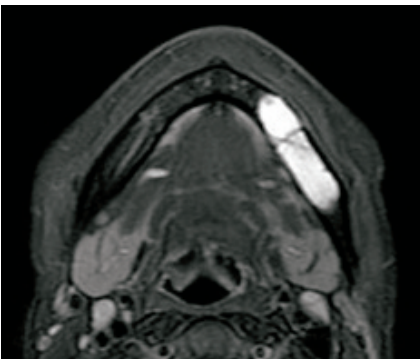


骨表示 CT 横断像

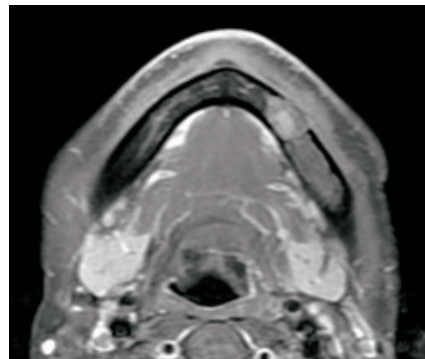


骨表示 CT 冠状断像

C

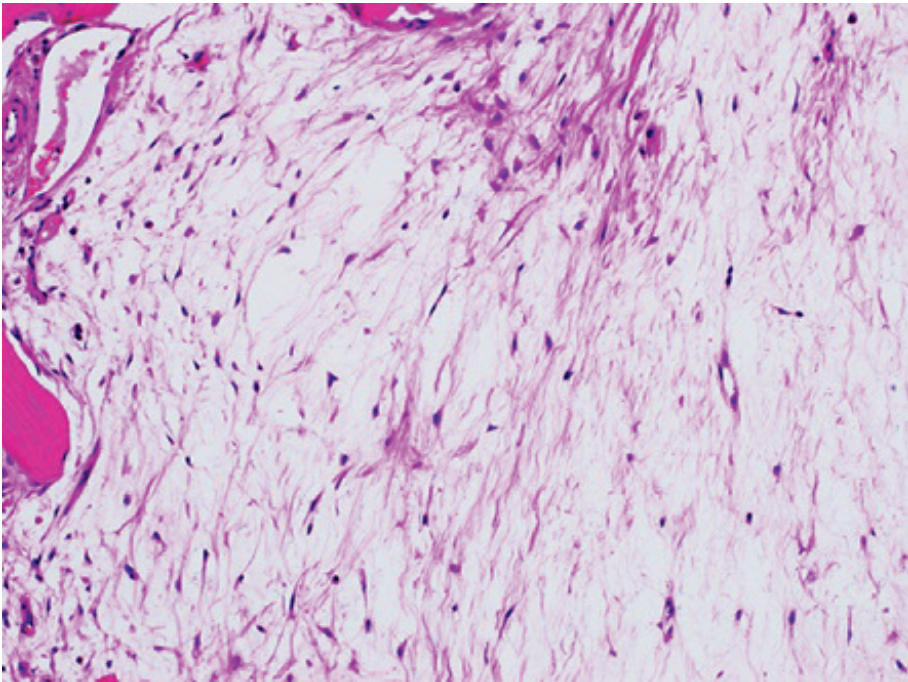
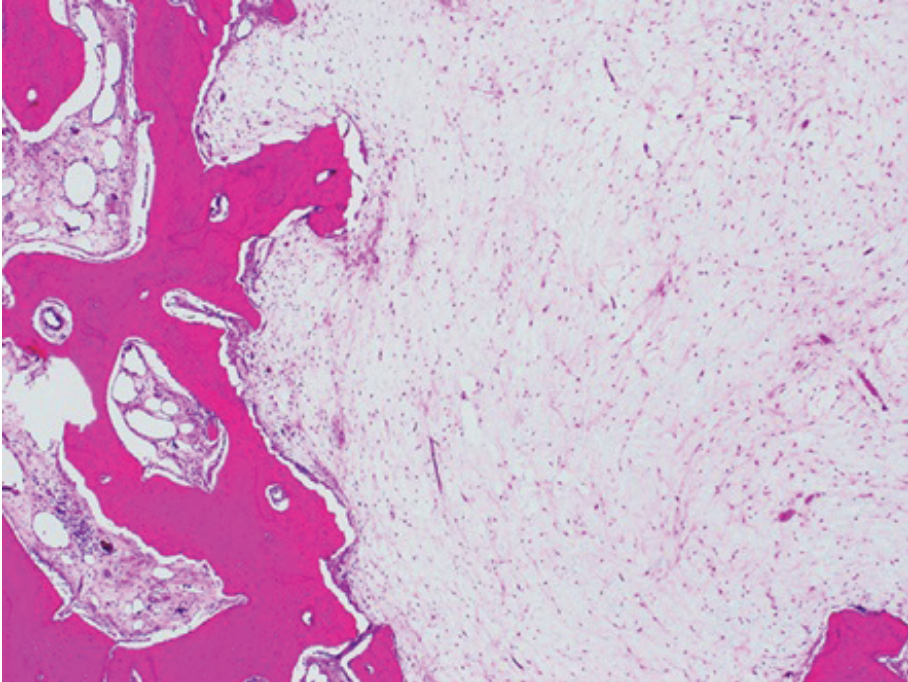


脂肪抑制 T2 強調横断像



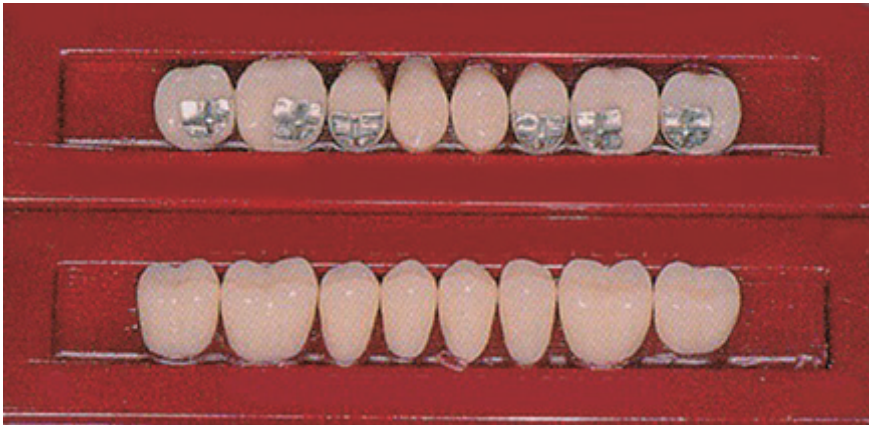脂肪抑制造影 T1 強調横断像

D

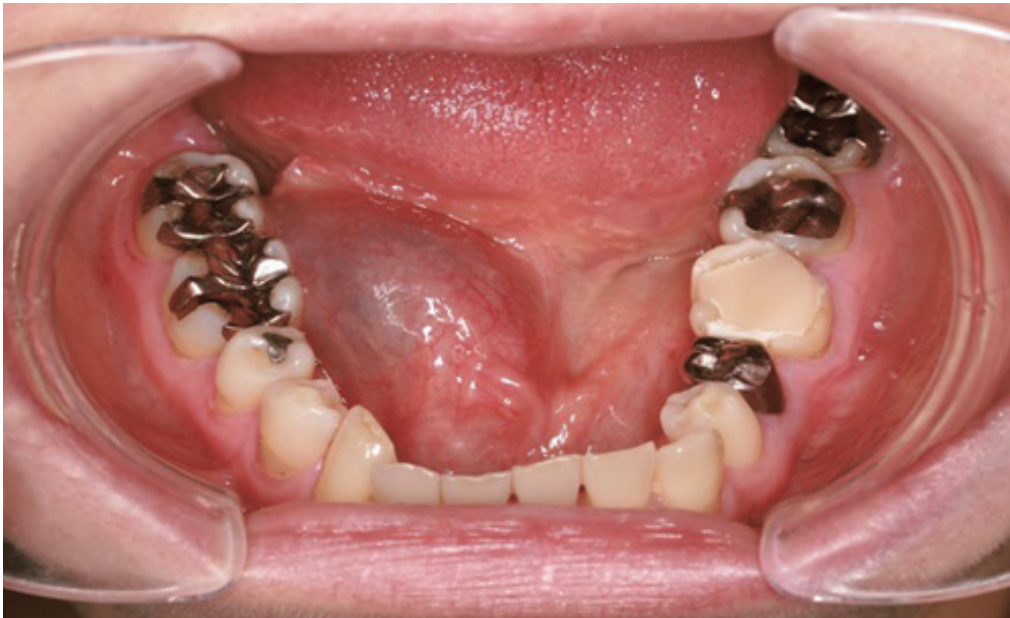

No. 29

(C 問題 68)



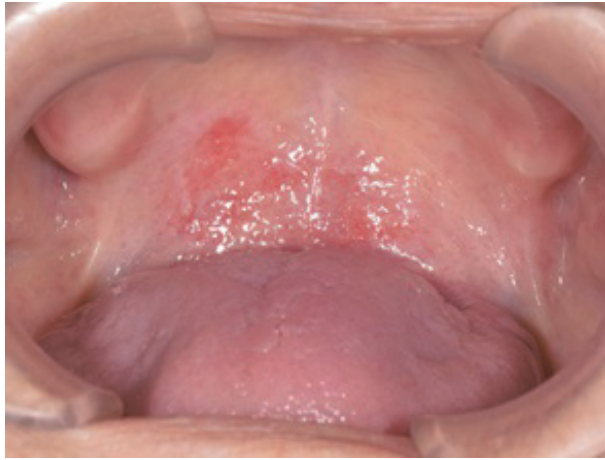



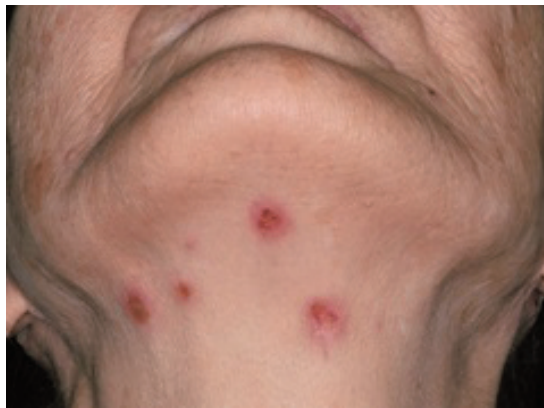No. 31

(C 問題 72)

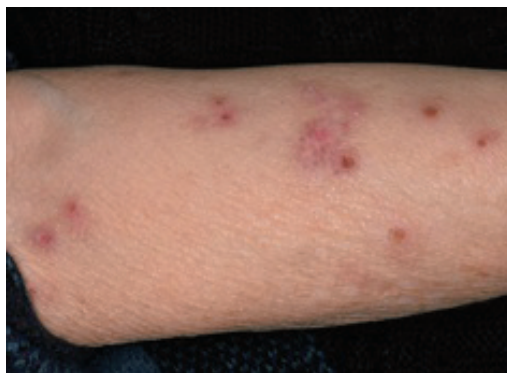A



B



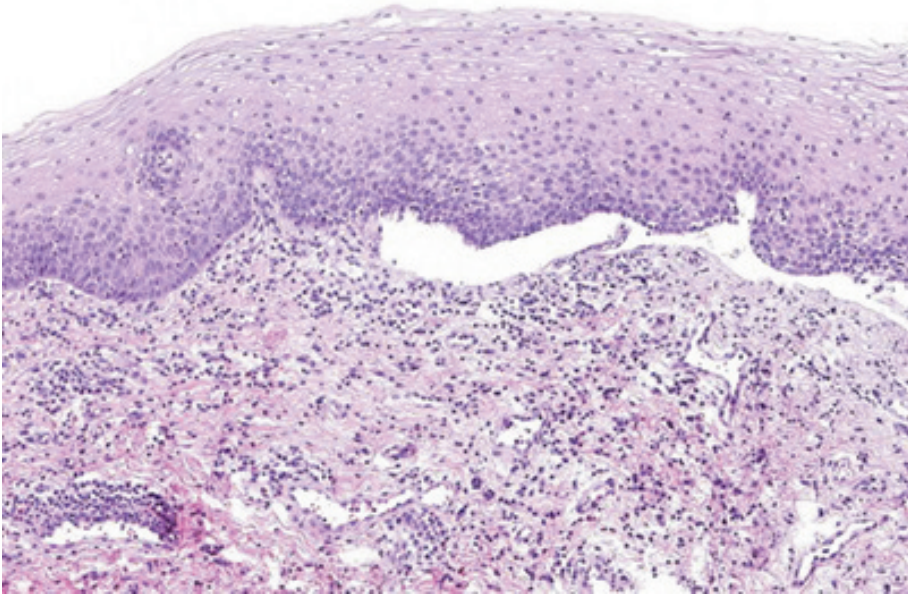
C

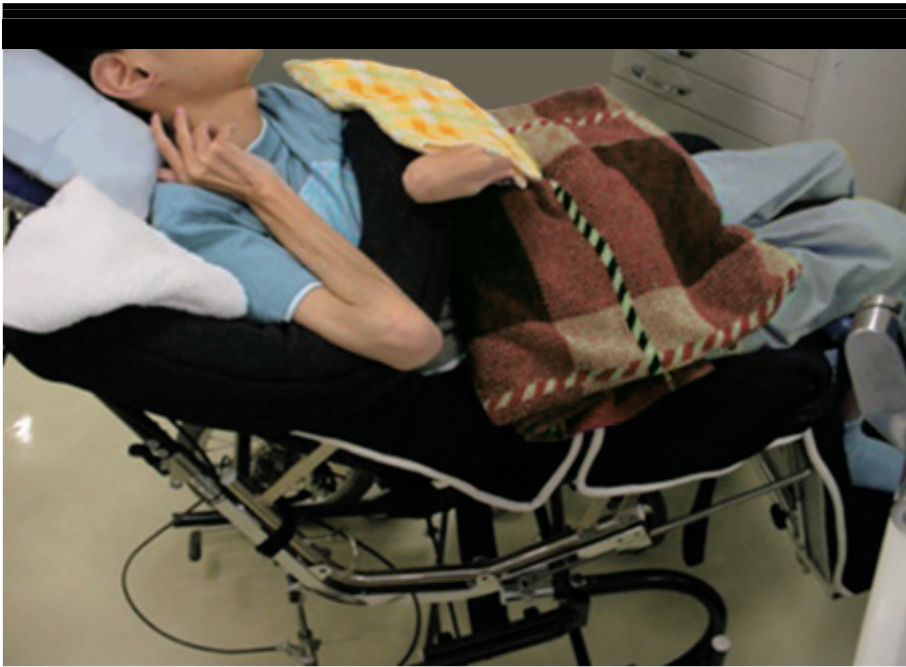


No. 31

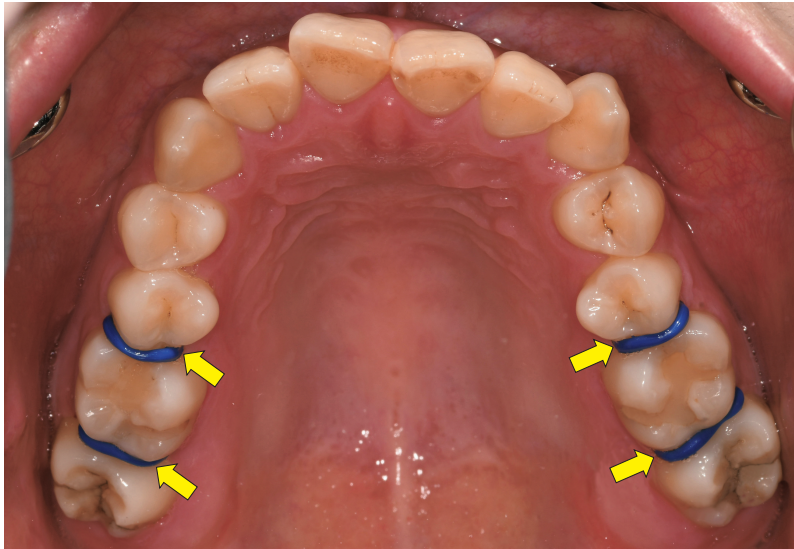
(C 問題 72)

D





A



B

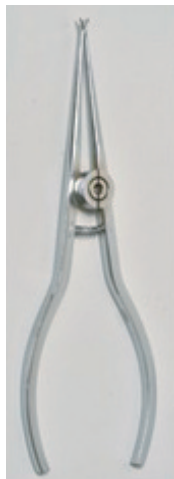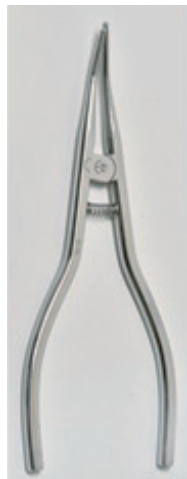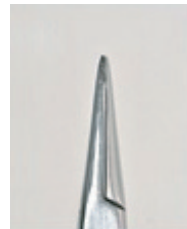
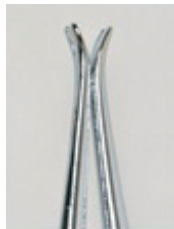ア

イ

ウ

エ

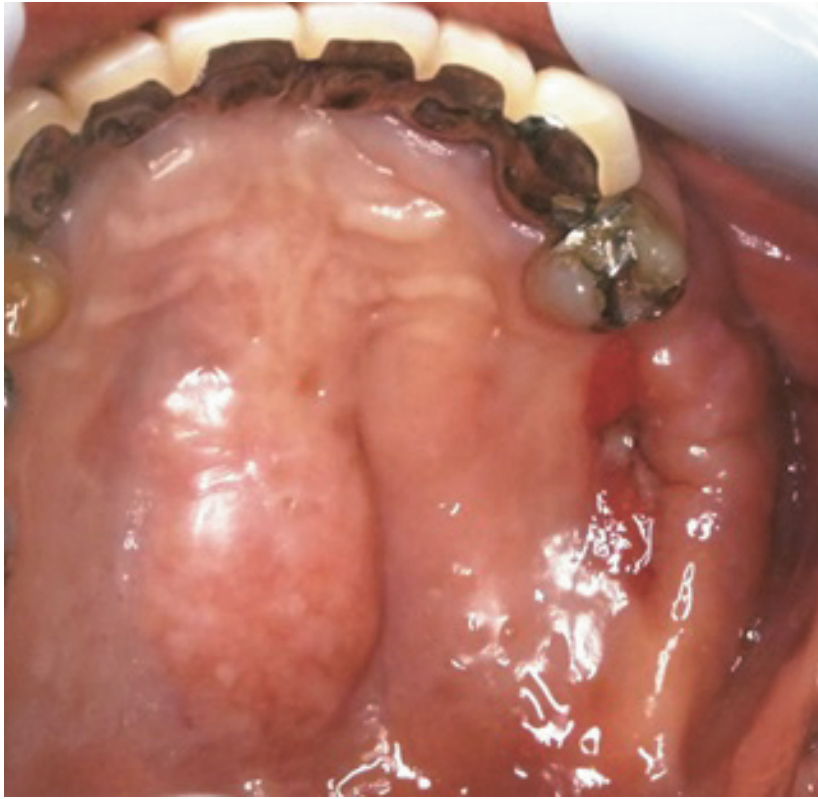オ



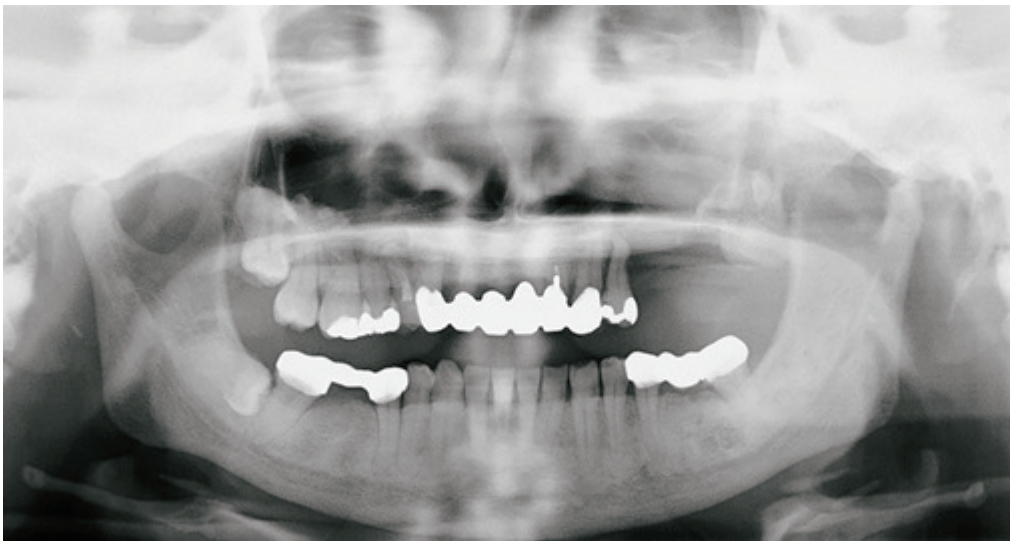No. 34

(C 問題77)

A



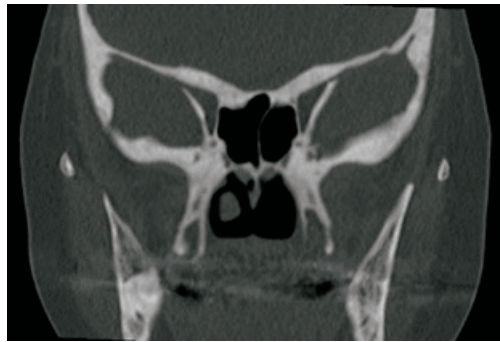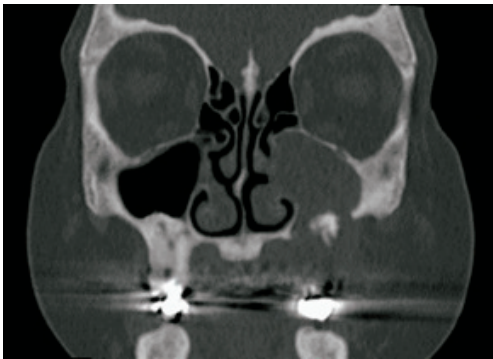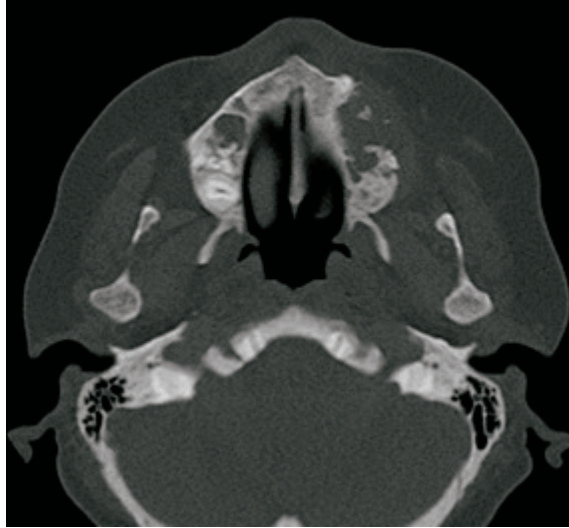
B



No. 34

(C 問題77)

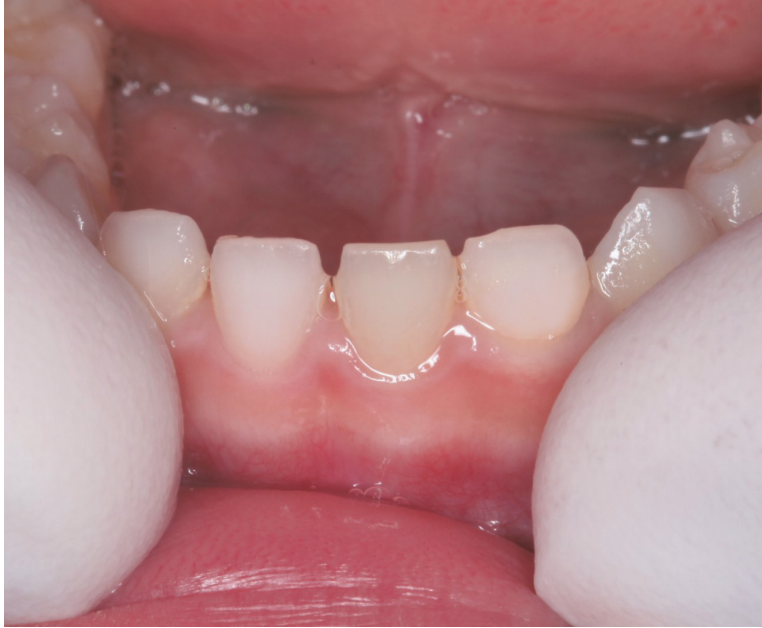C



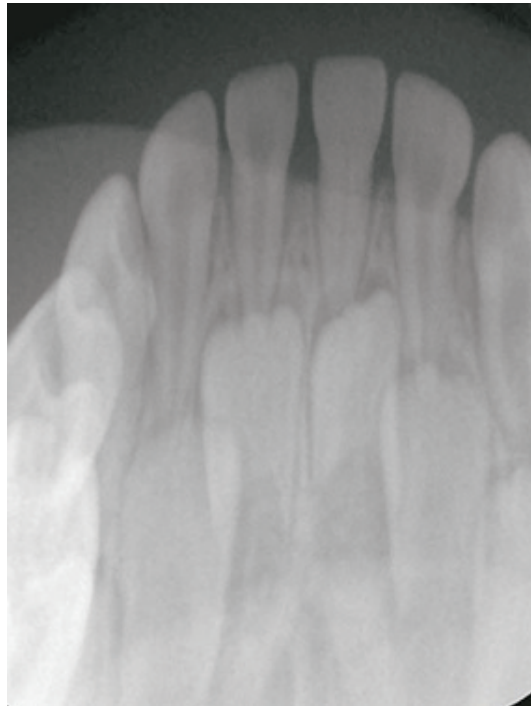
No. 35

(C 問題78)

A



B

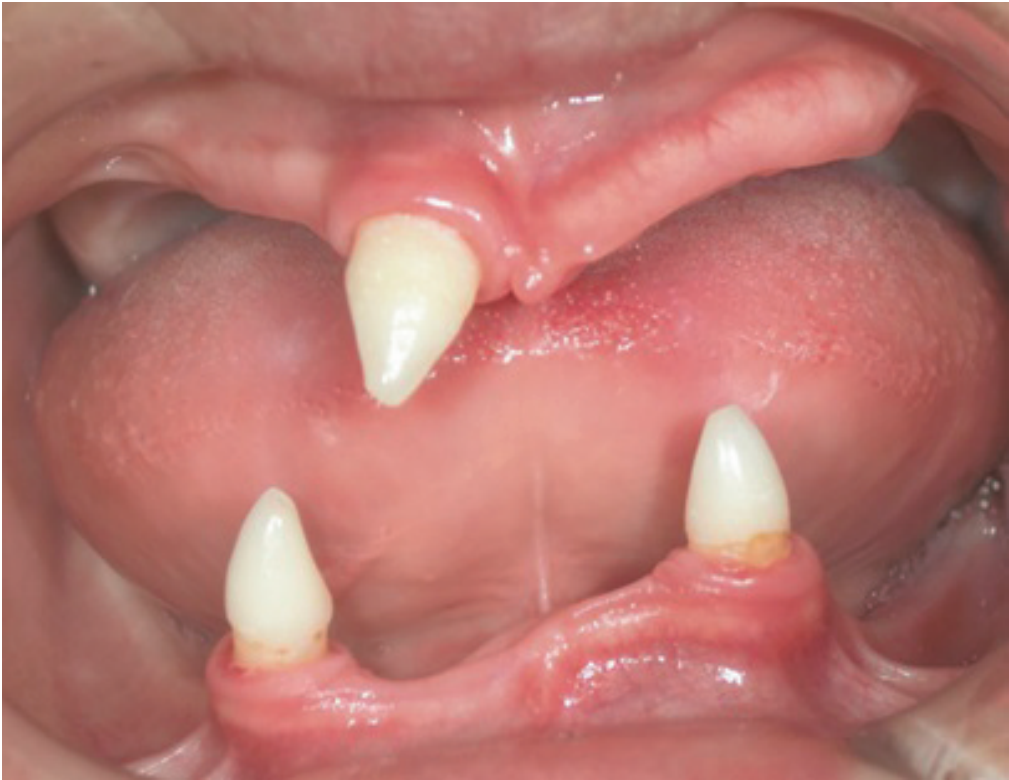



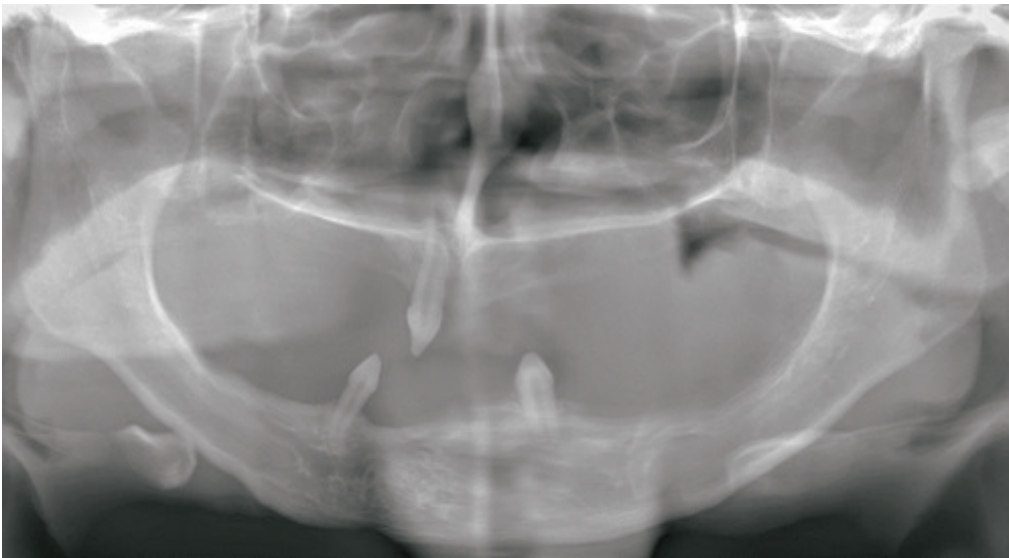
No. 36

(C 問題 80)

A



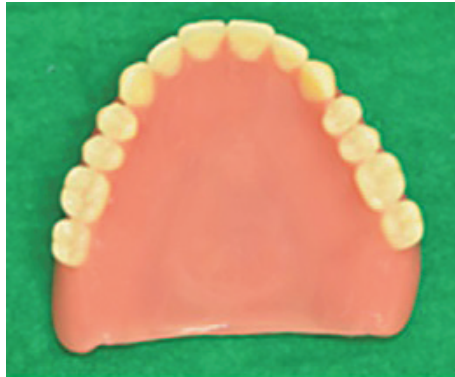B



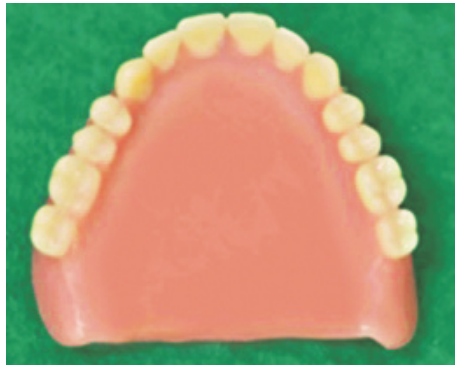No. 37

(C 問題 82)

A

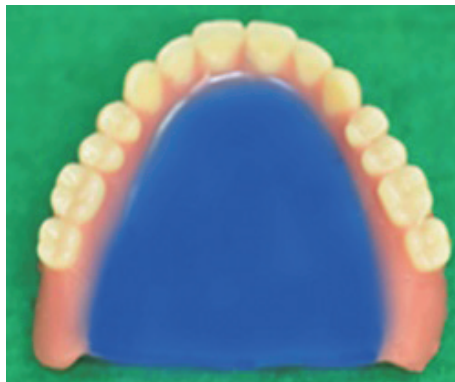


修正前



修正後

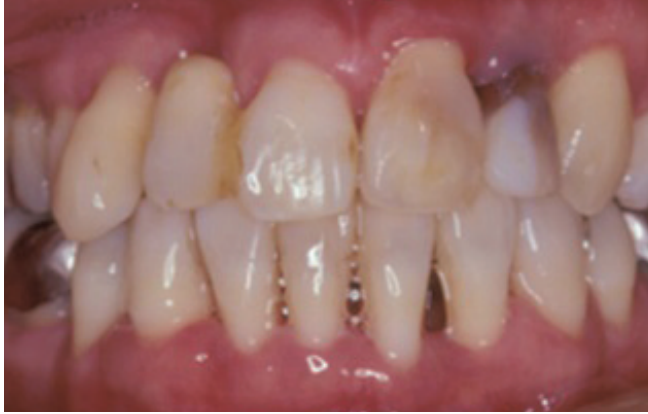B



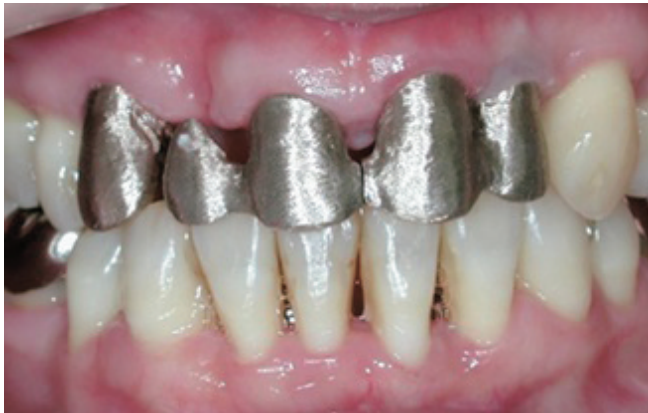No. 38

(C 問題 83)

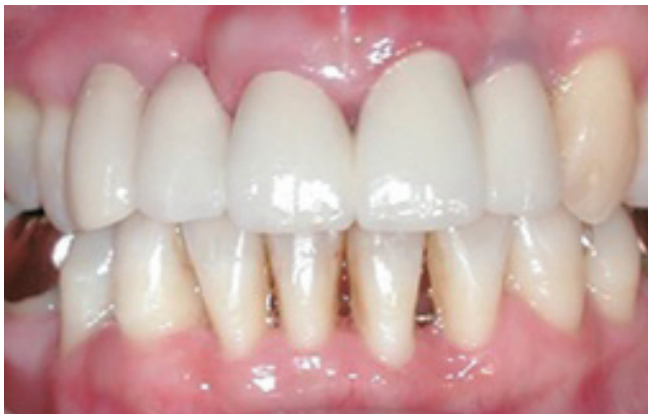A

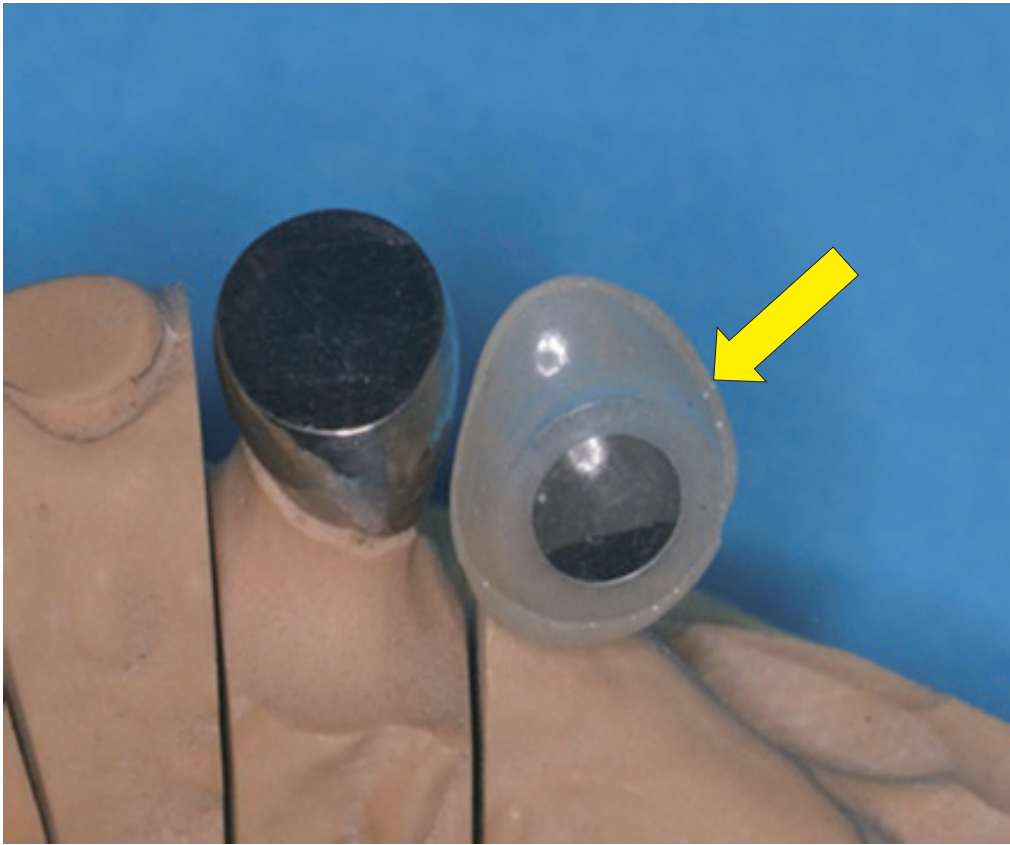


B



C



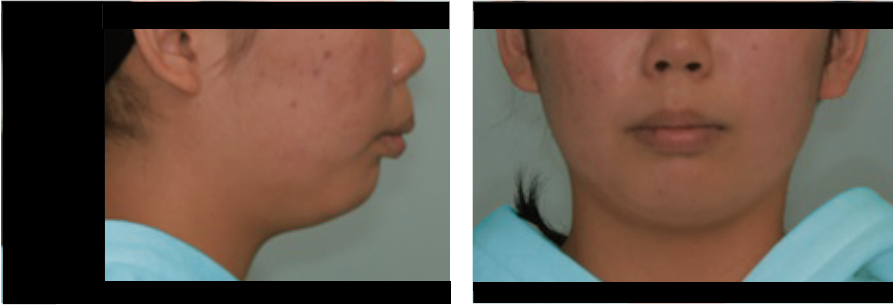


余 白

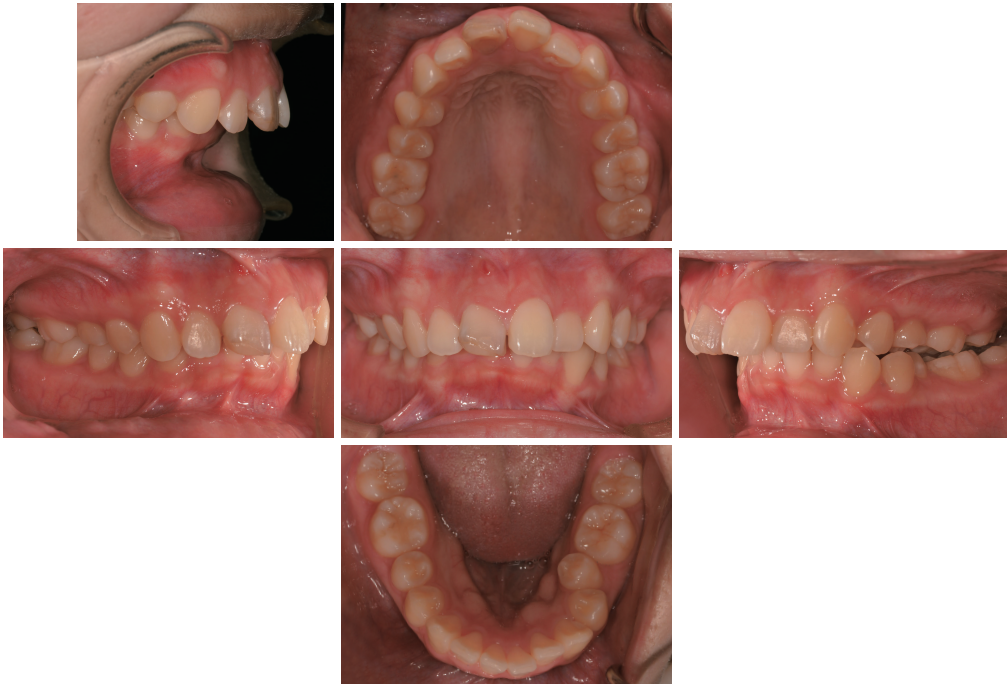No. 40

(C 問題 85)

A



B



No. 40

(C 問題 85)

C

