

資料 2 - 4

2-ビニルピリジンのラットを用いた強制経口投与による
肝中期発がん性試験報告書

試験番号 : 0826

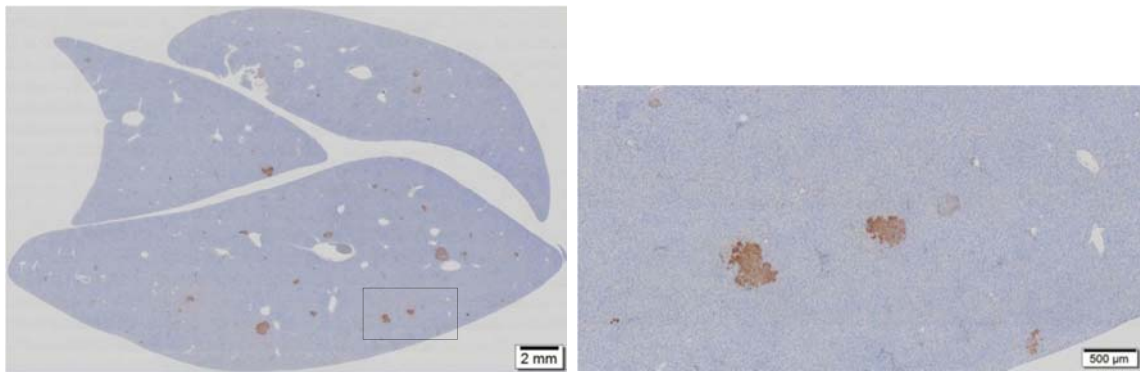
PHOTOGRAPHS

PHOTOGRAPHS

PHOTOGRAPH 1 GST-P IMMUNOHISTOCHEMICAL STAINING OF LIVER SECTIONS IN VEHICLE CONTROL GROUP

PHOTOGRAPH 2 GST-P IMMUNOHISTOCHEMICAL STAINING OF LIVER SECTIONS IN 120 mg/kg ADMINISTRATION GROUP

PHOTOGRAPH 3 GST-P IMMUNOHISTOCHEMICAL STAINING OF LIVER SECTIONS IN POSITIVE CONTROL GROUP



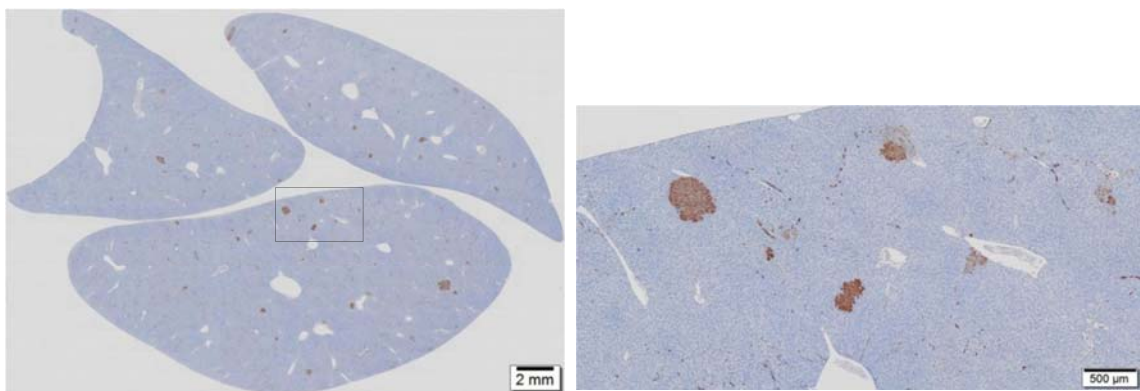
1-A

1-B

PHOTOGRAPH 1
GST-P IMMUNOHISTOCHEMICAL STAINING OF LIVER SECTIONS IN
VEHICLE CONTROL GROUP (ANIMAL NO. 1007)

1-A : Lower magnification

1-B : Higher magnification of a rectangle region in the photograph 1-A



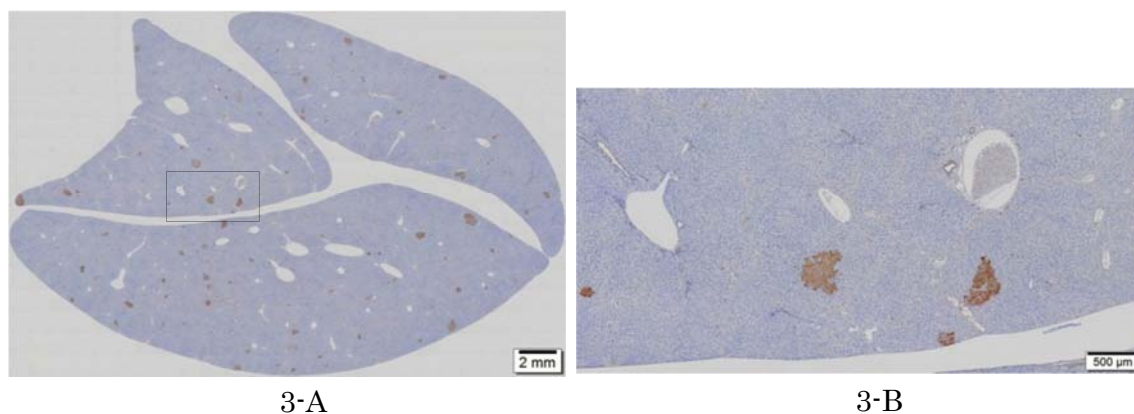
2-A

2-B

PHOTOGRAPH 2
GST-P IMMUNOHISTOCHEMICAL STAINING OF LIVER SECTIONS IN
120 mg/kg ADMINISTRATION GROUP (ANIMAL NO. 1414)

2-A : Lower magnification

2-B : Higher magnification of a rectangle region in the photograph 2-A



PHOTOGRAPH 3
GST-P IMMUNOHISTOCHEMICAL STAINING OF LIVER SECTIONS IN
POSITIVE CONTROL GROUP (ANIMAL NO. 1509)

3-A : Lower magnification

3-B : Higher magnification of a rectangle region in the photograph 3-A