

資料 2 － 7

1,3-ジブロモプロパンのラットを用いた強制経口投与による 肝中期発がん性試験報告書

試験番号：0827

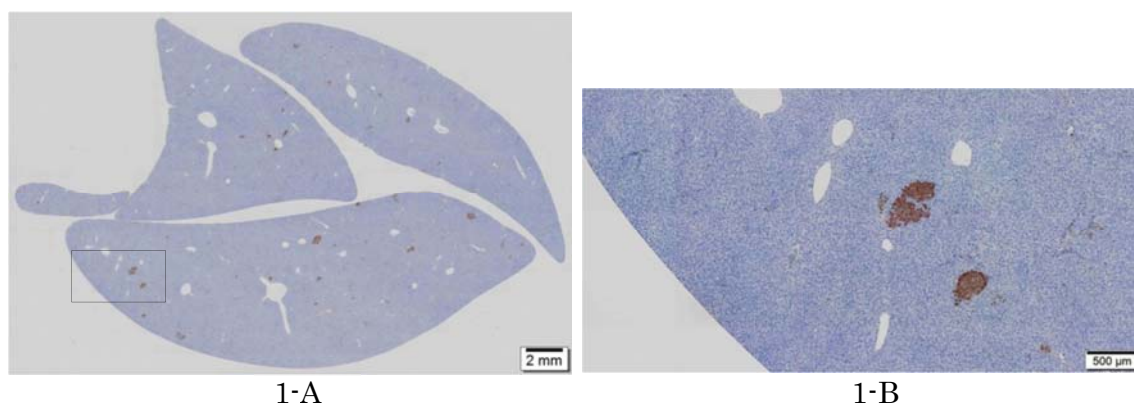
PHOTOGRAPHS

PHOTOGRAPHS

PHOTOGRAPH 1 GST-P IMMUNOHISTOCHEMICAL STAINING OF LIVER
SECTIONS IN VEHICLE CONTROL GROUP

PHOTOGRAPH 2 GST-P IMMUNOHISTOCHEMICAL STAINING OF LIVER
SECTIONS IN 150 mg/kg ADMINISTRATION GROUP

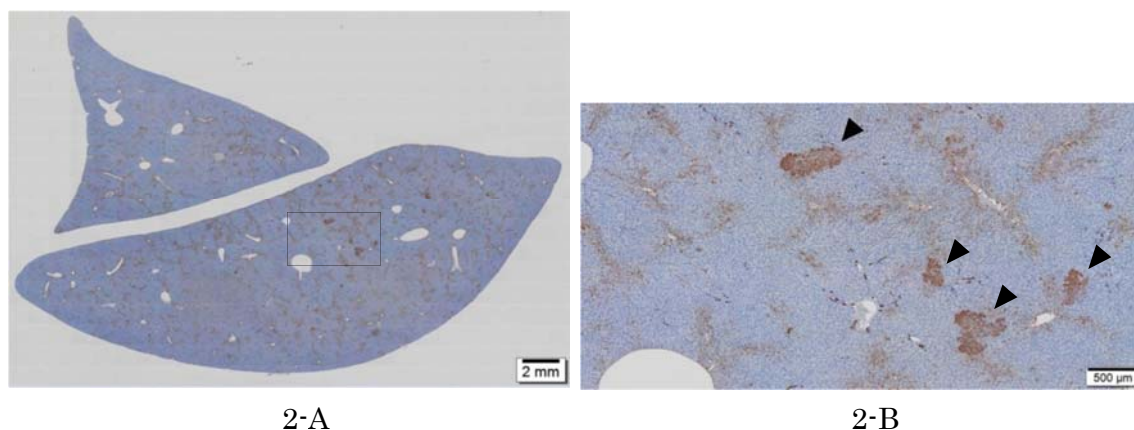
PHOTOGRAPH 3 GST-P IMMUNOHISTOCHEMICAL STAINING OF LIVER
SECTIONS IN POSITIVE CONTROL GROUP



PHOTOGRAPH 1
GST-P IMMUNOHISTOCHEMICAL STAINING OF LIVER SECTIONS IN
VEHICLE CONTROL GROUP (ANIMAL NO. 1017)

1-A : Lower magnification

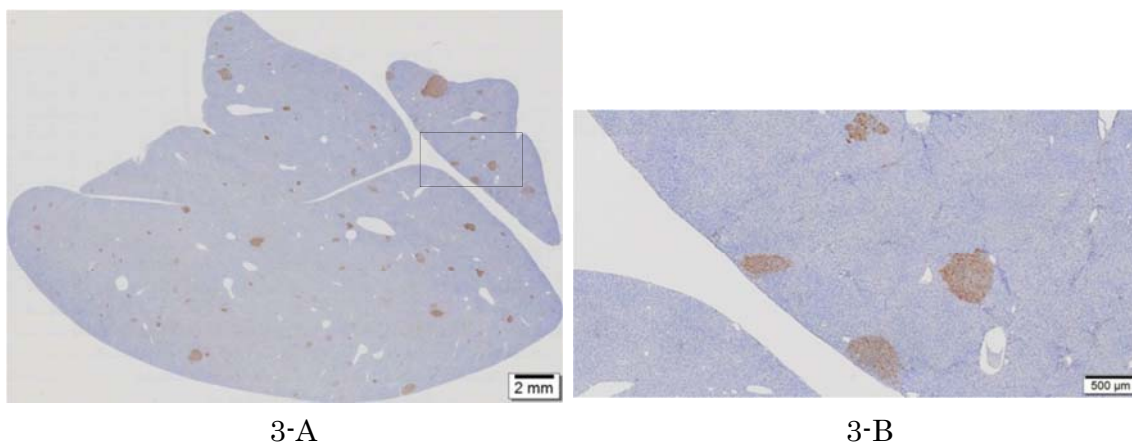
1-B : Higher magnification of a rectangle region in the photograph 1-A



PHOTOGRAPH 2
GST-P IMMUNOHISTOCHEMICAL STAINING OF LIVER SECTIONS IN
150 mg/kg ADMINISTRATION GROUP (ANIMAL NO. 1406)

2-A : Lower magnification

2-B : Higher magnification of a rectangle region in the photograph 2-A
(Arrowheads : GST-P positive foci)



PHOTOGRAPH 3
GST-P IMMUNOHISTOCHEMICAL STAINING OF LIVER SECTIONS IN
POSITIVE CONTROL GROUP (ANIMAL NO. 1516)

3-A : Lower magnification

3-B : Higher magnification of a rectangle region in the photograph 3-A