

## 資料 2 － 4

### 2-ビニルピリジンのラットを用いた強制経口投与による 肝中期発がん性試験報告書

試験番号：0826

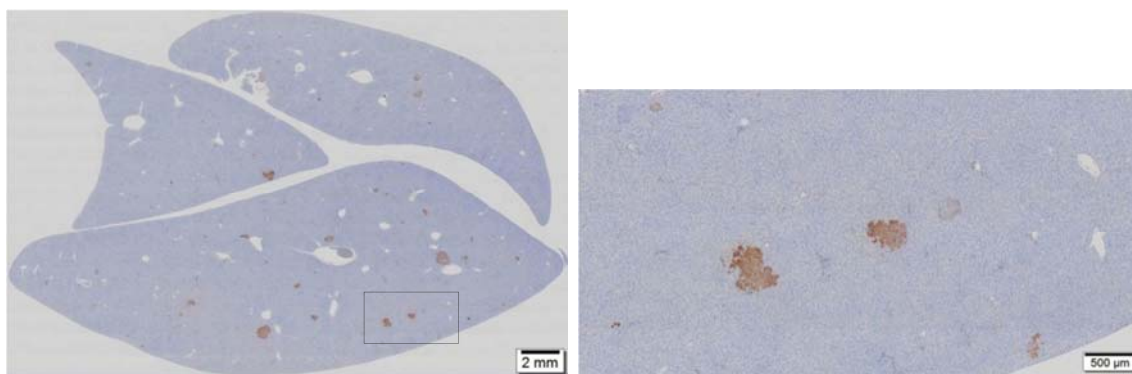
# PHOTOGRAPHS

## PHOTOGRAPHS

PHOTOGRAPH 1 GST-P IMMUNOHISTOCHEMICAL STAINING OF LIVER  
SECTIONS IN VEHICLE CONTROL GROUP

PHOTOGRAPH 2 GST-P IMMUNOHISTOCHEMICAL STAINING OF LIVER  
SECTIONS IN 120 mg/kg ADMINISTRATION GROUP

PHOTOGRAPH 3 GST-P IMMUNOHISTOCHEMICAL STAINING OF LIVER  
SECTIONS IN POSITIVE CONTROL GROUP



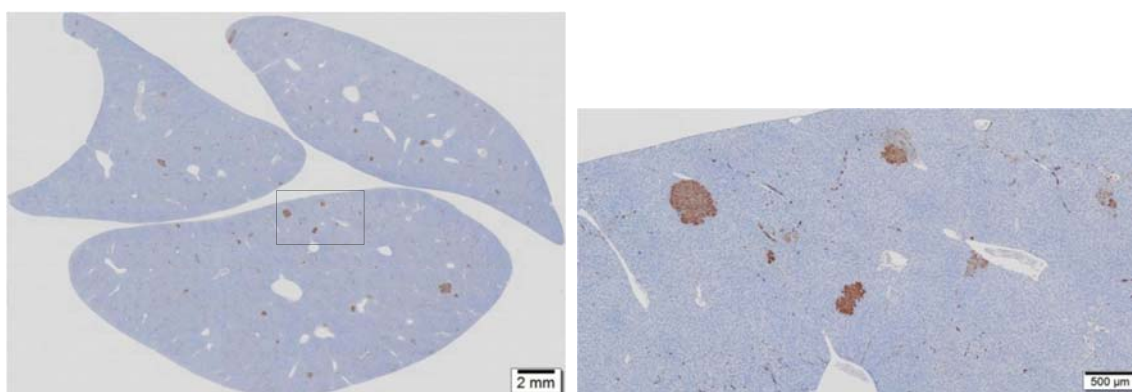
1-A

1-B

**PHOTOGRAPH 1**  
**GST-P IMMUNOHISTOCHEMICAL STAINING OF LIVER SECTIONS IN**  
**VEHICLE CONTROL GROUP (ANIMAL NO. 1007)**

1-A : Lower magnification

1-B : Higher magnification of a rectangle region in the photograph 1-A



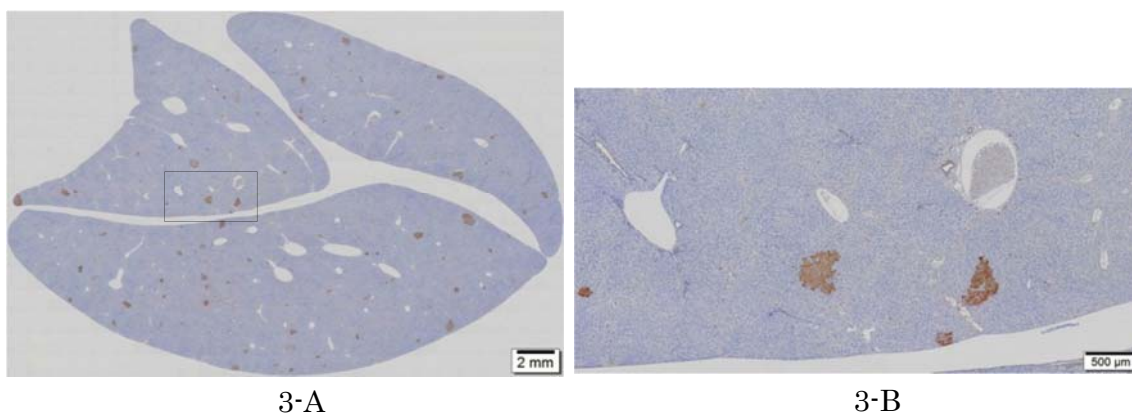
2-A

2-B

**PHOTOGRAPH 2**  
**GST-P IMMUNOHISTOCHEMICAL STAINING OF LIVER SECTIONS IN**  
**120 mg/kg ADMINISTRATION GROUP (ANIMAL NO. 1414)**

2-A : Lower magnification

2-B : Higher magnification of a rectangle region in the photograph 2-A



PHOTOGRAPH 3  
GST-P IMMUNOHISTOCHEMICAL STAINING OF LIVER SECTIONS IN  
POSITIVE CONTROL GROUP (ANIMAL NO. 1509)

3-A : Lower magnification

3-B : Higher magnification of a rectangle region in the photograph 3-A