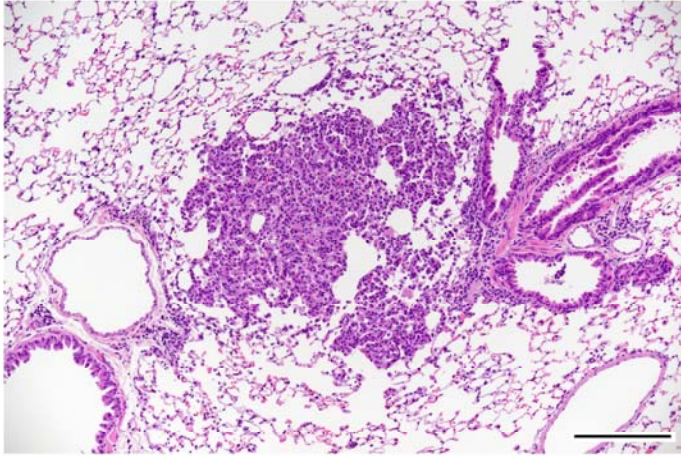


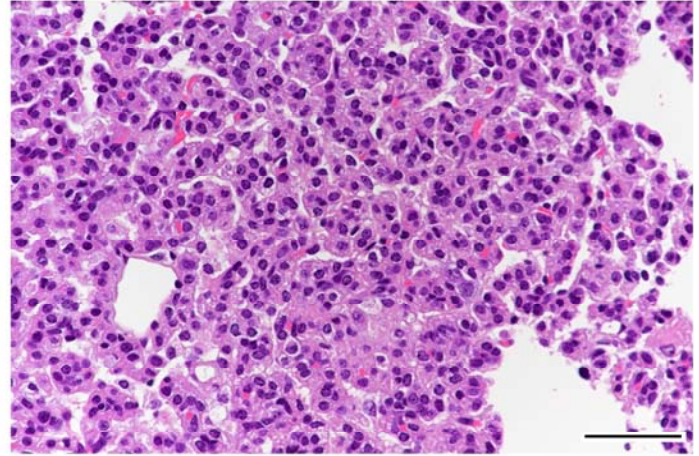
2-ブロモプロパンの rasH2 マウスを用いた
吸入による中期がん原性試験報告書

試験番号 : 0886

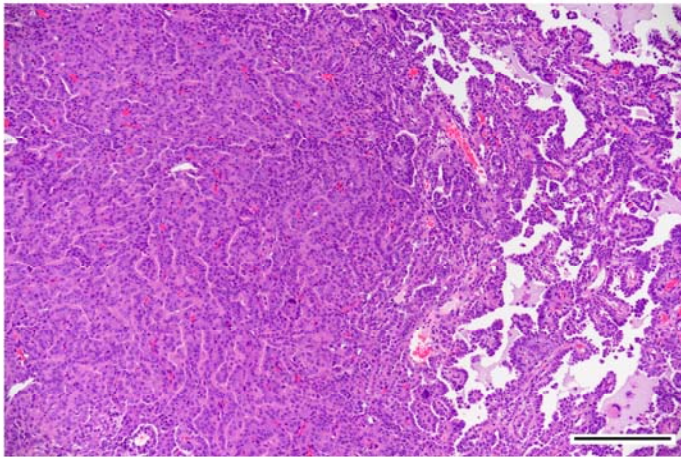
PHOTOGRAPHS



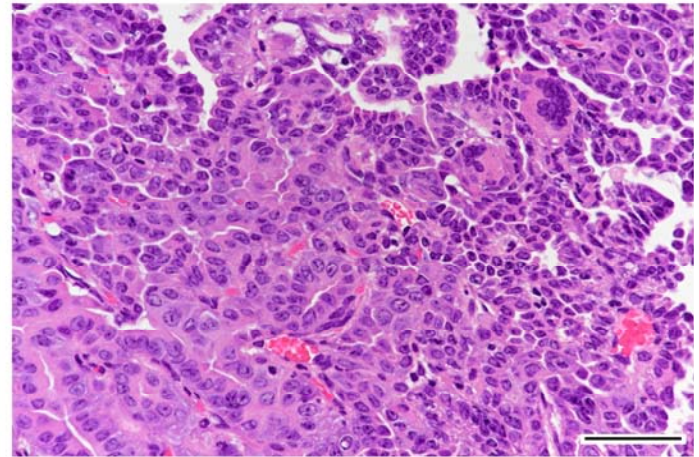
Photograph 1
Lung: Bronchiolar-alveolar adenoma
Mouse, Female, 600 ppm, Animal No. 0886-2320 (H&E)
Bar: 200 μ m



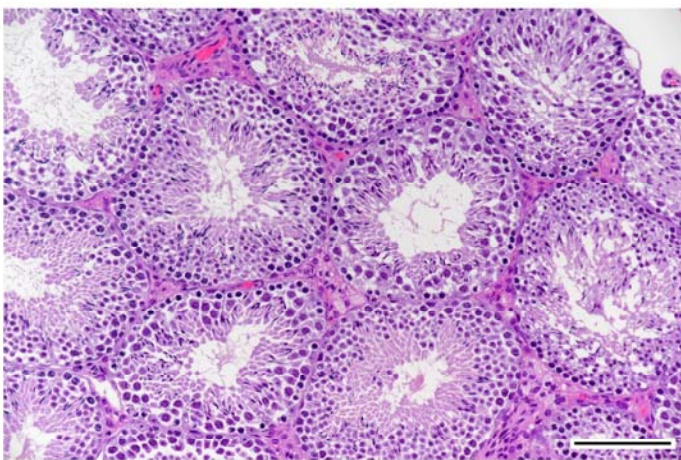
Photograph 2
High magnification of photograph 1
Bar: 50 μ m



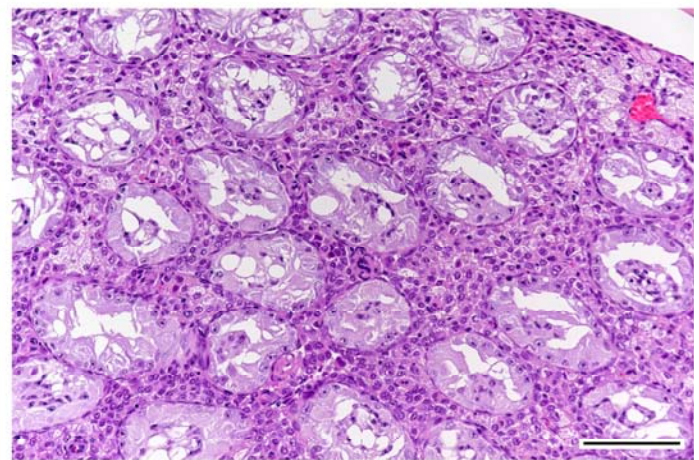
Photograph 3
Lung: Bronchiolar-alveolar carcinoma
Mouse, Female, 600 ppm, Animal No. 0886-2304 (H&E)
Bar: 200 μ m



Photograph 4
High magnification of photograph 3
Bar: 50 μ m



Photograph 5
Testis: Normal
Mouse, Male, control, Animal No. 0886-1002 (H&E)
Bar: 100 μ m



Photograph 6
Testis: Germ cell necrosis
Mouse, Male, 600 ppm, Animal No. 0886-1303 (H&E)
Bar: 100 μ m