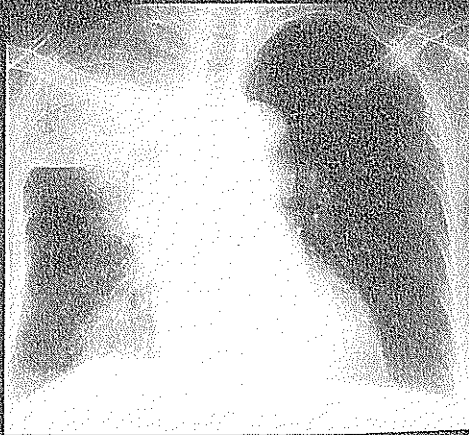
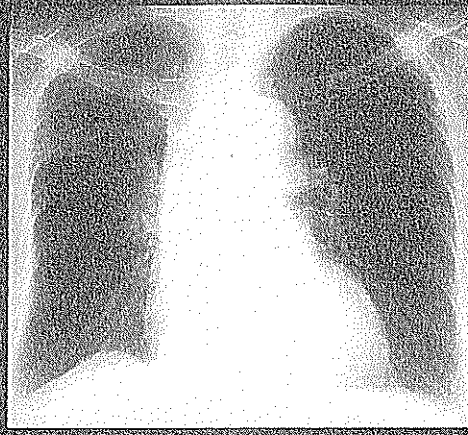


Case 76y, F, adenocarcinoma (BAC)
cT4N0M1 (PUL), stage IV, PS3



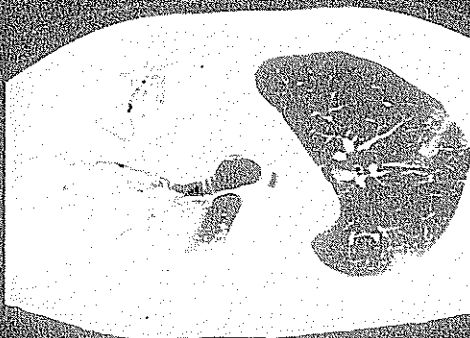Before



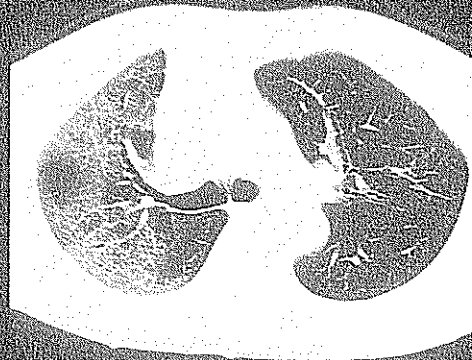After

NTOG

Case 76y, F, adenocarcinoma (BAC)
cT4N0M1 (PUL), stage IV, PS3



Before



After

NTOG