

医薬品  
医薬部外品 研究報告 調査報告書  
化粧品

識別番号・報告回数		報告日		第一報入手日 2008年7月14日	新医薬品等の区分 該当なし	厚生労働省処理欄
一般的名称	乾燥濃縮人血液凝固第Ⅷ因子		研究報告の 公表状況	Annals of Neurology 2008; 63(6): 697-708	公表国 アメリカ	
販売名 (企業名)	コンコエイト-HT (ベネシス)					
研究報告の概要	<p>&lt;目的&gt; 明確な組織病理および免疫染色所見によって特徴付けられ、また、通常のプリオン病とは異なりプロテアーゼ消化に感受性の高いプリオンたん白 (PrP) の異常なアイソフォームに関連した新規プリオン病を報告する。</p> <p>&lt;方法&gt; National Prion Disease Pathology Surveillance Centerにおいて、11名の被験者の臨床的、組織病理学および免疫組織化学的特徴、遺伝型ならびに PrP の特徴を調査した。</p> <p>&lt;結果&gt; 患者らは平均年齢 62 歳で行動的及び精神医学的症状を示し、その平均罹病期間は 20 ヶ月であった。海綿状変性のタイプ、PrP の免疫染色パターン、マイクロブラクの存在は、知られたプリオン病のものとは異なっていた。典型的なプロテアーゼ抵抗性 PrP は標準的診断では脳の新皮質に検出されなかった。異常 PrP は、濃縮すると通常のプリオン病の 16 倍低い濃度で検出された。それはプロテアーゼ抵抗性 PrP が約 4 倍低く、特徴的な電気泳動像を示した。検査した被験者は、National Prion Disease Pathology Surveillance Center によって評価された孤発性症例の約 3% である。数人の被験者は痴呆の家族歴を有したが、PrP 遺伝子のオープン・リーディング・フレームの変異は見つからなかった。</p> <p>&lt;解釈&gt; その明確な組織病理学的、PrP 免疫組織化学的、物理化学的特徴は、同じ遺伝型と併せて、以前に確認されていない、PrP が関わる疾患であることを示しており、われわれはこれをプロテアーゼ感受性プリオン病 (PSPr) と名付けた。PSPr は、プリオン病の中では稀ではなく、われわれのデータが示すよりもさらに多い可能性がある。その理由は、PSPr の症例がアルツハイマー以外の痴呆症のグループに分類されている可能性があるからである。</p>					<p>使用上の注意記載状況・ その他参考事項等</p> <p>2. 重要な基本的注意 (1) 略 1) 略 2) 略 3) 現在までに本剤の投与により変異型クロイツフェルト・ヤコブ病 (vCJD) 等が伝播したとの報告はない。しかしながら、製造工程において異常プリオンを低減し得るとの報告があるものの、理論的な vCJD 等の伝播のリスクを完全には排除できないので、投与の際には患者への説明を十分行い、治療上の必要性を十分検討の上投与すること。</p>
	報告企業の意見				今後の対応	
<p>プロテアーゼ感受性のプリオンたん白と関連した新規プリオン病に関する報告である。 これまで血漿分画製剤によってvCJD、スクレイパー及びBCWDを含むプリオン病が伝播したとの報告はない。しかしながら、万一vCJD感染者の血漿が本剤の原料に混入した場合には、製造工程においてプリオンを低減し得るとの報告があるものの、製剤から伝播する可能性を完全には否定し得ない。そのため、弊社の血漿分画製剤の製造工程におけるTSE感染性低減に関する検証実験を加速し、自社データを早期に取得し、工程評価を行い、必要に応じて工程改善を実施する予定である。</p>				<p>本報告は本剤の安全性に影響を与えないと考えるので、特段の措置はとらない。</p>		

245





# A Novel Human Disease with Abnormal Prion Protein Sensitive to Protease

Pierluigi Gambetti, MD,<sup>1</sup> Zhiqian Dong, PhD,<sup>1</sup> Jue Yuan, BA,<sup>1</sup> Xiangzhu Xiao, PhD,<sup>1</sup> Mengjie Zheng, PhD,<sup>1</sup> Amer Alsbekhleec, MD,<sup>1</sup> Rudy Castellani, MD,<sup>2</sup> Mark Cohen, MD,<sup>1</sup> Marcelo A. Barria, PhD,<sup>3</sup> D. Gonzalez-Romero, PhD,<sup>3</sup> Eirnas D. Belay, MD,<sup>4</sup> Lawrence B. Schonberger, MD, MPH,<sup>4</sup> Karen Marder, MD,<sup>5</sup> Carrie Harris, BA,<sup>1</sup> James R. Burke, MD, PhD,<sup>6</sup> Thomas Montine, MD,<sup>7</sup> Thomas Wisniewski, MD,<sup>8</sup> Dennis W. Dickson, MD,<sup>9</sup> Claudio Soto, PhD,<sup>3</sup> Christine M. Hulette, MD,<sup>10</sup> James A. Mastrianni, MD, PhD,<sup>11</sup> Qingzhong Kong, PhD,<sup>1</sup> and Wen-Quan Zou, MD, PhD<sup>1</sup>

**Objective:** To report a novel prion disease characterized by distinct histopathological and immunostaining features, and associated with an abnormal isoform of the prion protein (PrP) that, contrary to the common prion diseases, is predominantly sensitive to protease digestion.

**Methods:** Eleven subjects were investigated at the National Prion Disease Pathology Surveillance Center for clinical, histopathological, immunohistochemical, genotypical, and PrP characteristics.

**Results:** Patients presented with behavioral and psychiatric manifestations on average at 62 years, whereas mean disease duration was 20 months. The type of spongiform degeneration, the PrP immunostaining pattern, and the presence of microplaques distinguished these cases from those with known prion diseases. Typical protease-resistant PrP was undetectable in the cerebral neocortex with standard diagnostic procedures. After enrichment, abnormal PrP was detected at concentrations 16 times lower than common prion diseases; it included nearly 4 times less protease-resistant PrP, which formed a distinct electrophoretic profile. The subjects examined comprised about 3% of sporadic cases evaluated by the National Prion Disease Pathology Surveillance Center. Although several subjects had family histories of dementia, no mutations were found in the PrP gene open reading frame.

**Interpretation:** The distinct histopathological, PrP immunohistochemical, and physicochemical features, together with the homogeneous genotype, indicate that this is a previously unidentified type of disease involving the PrP, which we designated "protease-sensitive prionopathy" (or PSPr). Protease-sensitive prionopathy is not rare among prion diseases, and it may be even more prevalent than our data indicate because protease-sensitive prionopathy cases are likely also to be classified within the group of non-Alzheimer's dementias.

Ann Neurol 2008;63:697-708

Human prion diseases or transmissible spongiform encephalopathies may be sporadic, inherited, or acquired by infection.<sup>1</sup> Creutzfeldt-Jakob disease (CJD) is the most common phenotype and occurs in all three forms. In the sporadic form, CJD is classified into five subtypes, which can be readily distinguished based on clinical features, type and distribution of brain lesions, and pattern of prion protein (PrP) immunostaining.<sup>2,3</sup> Fatal insomnia, a much rarer phenotype, includes sporadic and inherited forms, and is characterized by loss of ability to sleep and preferential thalamic degeneration.<sup>4</sup> Gerstmann-Sträussler-S-

cheinker disease (GSS), the third phenotype, occurs exclusively as a heritable disease invariably associated with a mutation in the PrP gene open reading frame (ORF) and is characterized by the presence of prion amyloid plaques.<sup>4</sup>

Despite their heterogeneity, all sporadic human prion diseases described to date have been associated with abnormal PrP (commonly called PrP<sup>Sc</sup> but henceforth referred to as PrPr), which is resistant to treatment with proteases and is considered the diagnostic hallmark of these diseases.<sup>1</sup> PrPr is derived from normal or cellular PrP (PrP<sup>C</sup>) via a posttranslational tran-

From the <sup>1</sup>Institute of Pathology, Case Western Reserve University, Cleveland, OH; <sup>2</sup>Department of Pathology, University of Maryland, Baltimore, MD; <sup>3</sup>Department of Neurology, Neuroscience and Cell Biology, George and Cynthia Mitchell Center for Neurodegenerative Diseases, University of Texas Medical Branch, Galveston, TX; <sup>4</sup>Centers for Disease Control and Prevention, Atlanta, GA; <sup>5</sup>Department of Neurology, Columbia University, New York, NY; <sup>6</sup>Department of Medicine, Division of Neurology, Duke University, Durham, NC; <sup>7</sup>Harborview Medical Center, University of Washington, Seattle, WA; <sup>8</sup>Department of Neurology, New York University, New York, NY; <sup>9</sup>Department of Neuropathology, Mayo

Clinic College of Medicine, Jacksonville, FL; <sup>10</sup>Department of Pathology, Duke University, Durham, NC; and <sup>11</sup>Department of Neurology, University of Chicago, Chicago, IL.

Received Nov 5, 2007, and in revised form Apr 1, 2008. Accepted for publication Apr 4, 2008.

Address correspondence to Dr. Gambetti or Dr. Zou, Institute of Pathology, Case Western Reserve University, 2085 Adelbert Road, Cleveland, OH 44106. E-mail: pxg13@case.edu or wenquan.zou@case.edu

sition from  $\alpha$ -helical to  $\beta$ -sheet-rich conformations. PrP<sup>C</sup> and PrPr are quite different. Whereas PrP<sup>C</sup> is soluble in nondenaturing detergents and is completely digested when exposed to appropriate concentrations of proteinase K (PK), PrPr is detergent insoluble and its C-terminal region resists PK treatment.<sup>5</sup> Based on the size of their PK-resistant fragments, at least three major PrPr types are recognized, which codistribute with specific disease phenotypes: (1) PrPr type 1, which on PK treatment generates an approximately 21kDa fragment; (2) PrPr type 2, generating an approximately 19kDa fragment; and (3) PrP7-8, a PrP internal fragment of 7 to 8kDa.<sup>4-6</sup> Both PrPr types 1 and 2 have been observed associated with distinct subtypes of CJD. To date, PrP7-8 has been consistently observed only in GSS. Therefore, the conformational changes, which render PrPr pathogenic and in many but not all cases infectious, may engender different species or strains of PrPr that can be recognized based on their distinct protease-resistant fragments and by their associated clinicopathological phenotype.<sup>5,7-12</sup>

Studies mostly based on experimental models recently have shown that PK-resistant PrP (PrPr) is associated with varying quantities of a PrP isoform that, as PrPr, is detergent insoluble but sensitive to protease digestion (PrPs).<sup>11-15</sup> The relation of PrPs with PrPr and the role that PrPs plays in the pathogenesis of prion diseases remains uncertain.<sup>16-18</sup>

Here we report 11 patients with a human disease characterized by the presence of detergent-insoluble PrP that is predominantly sensitive to protease digestion and forms unusual immunohistochemical patterns. Furthermore, the small amount of PrPr present generates a distinct profile on immunoblot. Several affected patients have family histories of dementia but lack mutations in the PrP gene ORF. We refer to this condition as protease-sensitive prionopathy (PSPr). PSPr broadens the spectrum of human prion diseases and raises several important issues related to the nature of these diseases in light of their association with different PrP isoforms. Among prion diseases, PSPr is not rare. Because the presenting clinical signs often suggest the diagnosis of non-Alzheimer's dementia, PSPr may be even more prevalent than our data indicate because many PSPr cases might currently be classified within this group of dementias. Parts of this study have been presented previously.<sup>19</sup>

## Subjects and Methods

### Subjects

The 11 (10 autopsy and 1 biopsy) patients and the control subjects were referred to the National Prion Disease Pathology Surveillance Center between May 2002 and January 2006. Consent was obtained to use tissues for research, including genetic analyses.

### General Tissue Processing

Fixed and frozen brain tissues were obtained from all subjects and processed as described previously.<sup>20</sup>

### Histopathology and Immunohistochemistry

Samples obtained from up to 18 brain regions were processed as described previously.<sup>2,3</sup> Lesion profiles were constructed using semiquantitative evaluation of spongiform degeneration (SD) and astrogliosis in 12 brain regions from 6 subjects, and 4 or 5 regions from 2 subjects. SD and astrogliosis were scored (Fig. 1), and the scores from each of the brain regions were summed for each subject separately; values were averaged, and standard deviations were determined and plotted according to the brain region.<sup>2</sup> Vacuoles with larger than 4 $\mu$ m diameter were measured individually on random photomicrographs of frontal neocortex (10/subject,  $\times$ 180) using Spot software version 4.6 after calibration (Diagnostic Instruments, Sterling Heights, MI). Sections from the frontal and occipital neocortices, hippocampus, basal ganglia, thalamus, cerebellar hemisphere, and midbrain were processed for PrP immunohistochemistry with the monoclonal antibody (Mab) 3F4 or 1E4 (Cell Sciences, Canton, MA).<sup>2,20-23</sup> Selected brain regions were also immunostained with the Mabs 4G8 to amyloid  $\beta$ .<sup>24</sup>

### Electron Microscopy

Formalin-fixed postmortem brain tissue was processed for conventional electron microscopy and for PrP immunohistochemistry according to standard techniques using peroxidase-antiperoxidase Mab 3F4 to PrP.<sup>25</sup>

### Molecular Genetics

The entire PrP ORF was amplified by polymerase chain reaction using genomic DNA extracted from unfixed brain tissue or blood and the primers PrPO-F [GTTCATYATGCGAACCTTGG (Y = C + T)] and PrPO-R [CTCATCCCACKATCAGGAAG (K = T + G)]; sequencing was done directly or after cloning into plasmid pSTBlue 1 (Novagen, Madison, WI) by automated sequencing.<sup>22</sup>

### Prion Protein Characterization

#### CONVENTIONAL IMMUNOBLOT.

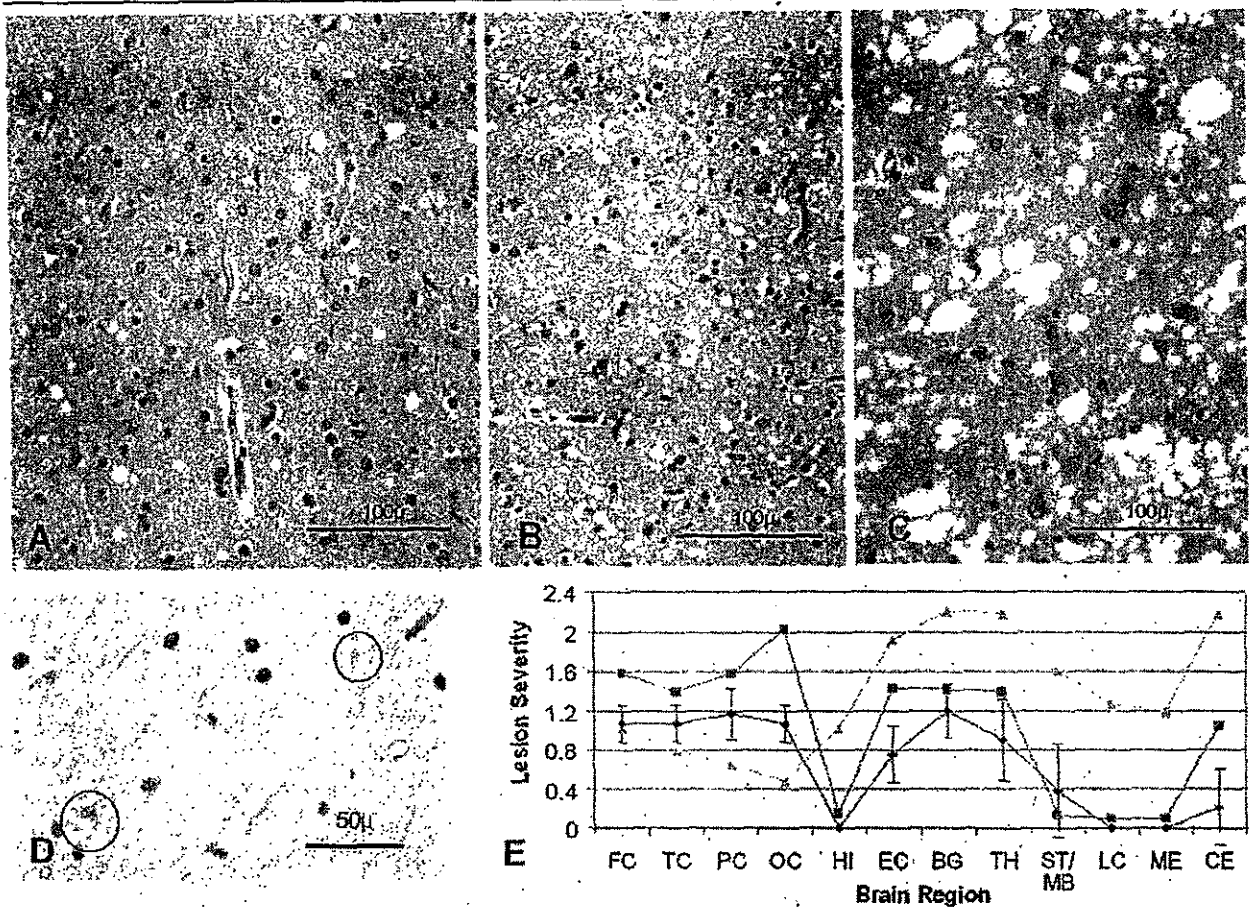
Five to 20 $\mu$ l 10% wt/vol brain homogenates with or without PK digestion (Sigma Chemical, St. Louis, MO) were loaded onto 15% Tris-HCl Criterion precast gels (Bio-Rad Laboratories, Hercules, CA) for sodium dodecyl sulfate polyacrylamide gel electrophoresis, and immunoblotted with 3F4 and 1E4 to human PrP residues 109 to 112 and 97 to 108, respectively.<sup>23</sup> PrP was deglycosylated with PNGase F (New England Biolabs, Beverly, MA) following manufacturer's instructions.

#### ENRICHMENT OF THE ABNORMAL PRION PROTEIN.

Two procedures were utilized: (1) capture of the abnormal PrP with the gene 5 protein (g5p), as described previously<sup>13,23</sup>; and (2) abnormal PrP precipitation with sodium phosphotungstate.<sup>26</sup>

#### SEDIMENTATION OF PRION PROTEIN IN SUCROSE GRADIENTS.

Brain homogenates were incubated with 2% Sarkosyl for 30 minutes on ice, loaded atop a 10 to 60% step sucrose gra-



**Fig 1.** Histopathology and lesion profile. The spongiform degeneration of protease-sensitive prionopathy (PSPr) (A) is characterized by a mixture of small and intermediate size vacuoles, whereas the vacuoles of two subtypes of sporadic Creutzfeldt-Jakob disease (CJD), sCJDMM1 (B) and sCJDMM2 (C), are mostly small (sCJDMM1) or much larger and confluent (sCJDMM2). (D) Eosinophilic microstructures surrounded by a pale halo (circle) in the cerebellar molecular layer; (A-D) Hematoxylin and eosin staining. (E) Lesion profiles of PSPr (diamonds), sCJDMM1 (squares), and sCJDVV2 (triangles). Vertical bars refer to standard deviations. In sCJDMM1 and sCJDVV2, for which data were adapted from Parchi and colleagues,<sup>2</sup> standard deviations were omitted for clarity. Spongiform degeneration was scored on a 0 to 4 scale (0 = not detectable; 1 = mild; 2 = moderate; 3 = severe; 4 = confluent); astrogliosis was scored on a 0 to 3 scale (0 = not detectable; 1 = mild; 2 = moderate; 3 = severe). FC = front cortex; TC = temporal cortex; PC = parietal cortex; OC = occipital cortex; HI = CA1 of hippocampus; EC = entorhinal cortex; BG = basal ganglia; TH = thalamus mediodorsal nucleus; MB/ST = midbrain in PSPr, substantia nigra in sCJDMM1 and sCJDVV2; LC = pons; ME = medulla; CE = cerebellar cortex.

dient and centrifuged 1 hour at 200,000g in a SW55 rotor (Beckman Coulter, Fullerton, CA).<sup>16,23,27</sup>

#### Statistics

Analyses were performed with the two-tail Student's *t* test.

#### Results

##### Clinical Features

Mean age of onset and disease duration were 62 years (range, 48–71 years) and 20 months (range, 10–60 months), respectively (Table 1). Presentation and course were dominated by neurobehavioral and psychiatric signs, with progressive motor and cognitive decline.

Seven patients were ataxic. Other consistent features included absence of periodic complexes on the electroencephalogram and nondiagnostic 14-3-3 protein test in the cerebrospinal fluid. Magnetic resonance imaging showed diffuse atrophy without restricted diffusion signals in all 10 patients examined. No subject had known history of prion exposure; probable familial occurrence of dementia was reported in 6 of 10 investigated patients (see Table 1).

##### Neurohistopathology

SD and astrogliosis of moderate severity were present in the cerebral cortex, basal ganglia, and thalamus of

**Table 1. Clinical Findings**

Case No.	Sex	Age (yr)	Disease Duration (mo)	Symptoms at Onset	Symptoms during Illness Evolution	EEG	MRI Atrophy/Diffusion	Family History of Dementia	Other Information
1	M	69	60	Behavioral and mood swings, psychosis (patient diagnosed with bipolar illness)	Dementia, aphasia, ataxia, and seizure	Slowing right > left	+/-	Mother died of dementia at age 70	(1) Right hemispheric hypoperfusion on SPECT study; (2) CSF 14-3-3 (not performed)
2	F	71	33	Depression and dementia	Dementia, ataxia, and Parkinsonism	Normal	+/-	Mother with dementia	CSF 14-3-3 (not performed)
3	M	70	12	Dementia and apathy	Aphasia, Parkinsonism, hyperreflexia, and prominent frontal release signs	Normal	+/-	Father with dementia at age 60	(1) Negative CSF 14-3-3; (2) increased CSF proteins 175mg/dl without cells
4	M	50	7 (died in a fall)	Dementia and mood swings	Psychosis, aphasia, patient fell and died of subdural hematoma	Diffuse slowing	NA	NA	Ambiguous CSF 14-3-3
5	F	67	11	Dementia and aphasia	Ataxia and depression	Not performed	+/-	Dementia in a paternal aunt and sister died of dementia at age 69	CSF 14-3-3 (not performed)
6	M	60	13	Dementia	Ataxia, psychosis, and incontinence	NA	+/-	No family history of dementia	CSF 14-3-3 (not performed)
7	F	48	17	Dementia, emotional lability, and outbursts	Motor decline	Diffuse slowing	+/-	Mother with early dementia at age 60	(1) Negative CSF 14-3-3; (2) patient had VP shunt without response
8	F	64	10	Dementia, depression, and psychosis	Ataxia, Parkinsonism, and tremor	Diffuse slowing	+/-	Mother with dementia	Negative CSF 14-3-3
9	M	63	23 (patient alive)	Dementia, personality and behavioral changes	Motor decline, Parkinsonism, and psychosis	Diffuse slowing	+/-	Mother died at age 83 with mild dementia	(1) Global hypoperfusion on SPECT study; (2) negative CSF 14-3-3; (3) increased CSF protein 126mg/dl without cells
10	F	68	17	Insomnia, tremor, and slurred speech	Dementia, ataxia, worsening depression with psychosis and agitation, hyperreflexia	Diffuse slowing	+/-	No family history of dementia	History of bipolar illness with suicidal attempts
11	M	52	13	Decreased verbal output, and progressive motor decline	Dementia, ataxia, and Parkinsonism	Normal	+/-	No family history of dementia	NA

Average disease duration ( $20.4 \pm 15.4$ ) excludes patients #4, who died of subdural hematoma caused by a fall, and #9, still alive at last report. The neurobehavioral and psychiatric manifestations included insomnia, apathy, personality changes, mood swings, emotional outburst, depression, and psychosis. Plus and minus signs, respectively, indicate the presence and absence of atrophy or restricted diffusion signals on brain magnetic resonance imaging (MRI); EEG = electroencephalography; SPECT = single-photon emission computerized tomography; CSF = cerebrospinal fluid; NA = not available; VP = ventriculoperitoneal.

the PSPr cases without severe neuronal loss. SD comprised a mixture of fine vacuoles, comparable with those seen in sCJDMM1 (the most common sCJD subtype), and slightly larger vacuoles that resulted in a mean vacuolar diameter greater than that of sCJDMM1 ( $7.8 \pm 2.7$  vs  $5.8 \pm 1.2 \mu\text{m}$ ). But the "larger" vacuoles clearly were smaller than the "coarse" vacuoles characteristic of sCJDMM2 (see Figs 1A-C).<sup>2,3</sup> The hippocampal pyramidal cell layer appeared unaffected; the molecular layer of the den-

tate gyrus and the stratum lacunosum moleculare showed mild SD, which extended into the subiculum and the entorhinal and inferior temporal neocortices. No kuru plaques or multicore plaques were detected. In some subjects, structures suggestive of microplaques were observed in the molecular layer of the cerebellum (see Fig 1D). Lesion profiling identified the cerebral neocortex, basal ganglia, and thalamus as the regions most severely affected, whereas the brainstem and cerebellum were apparently spared (see Fig