

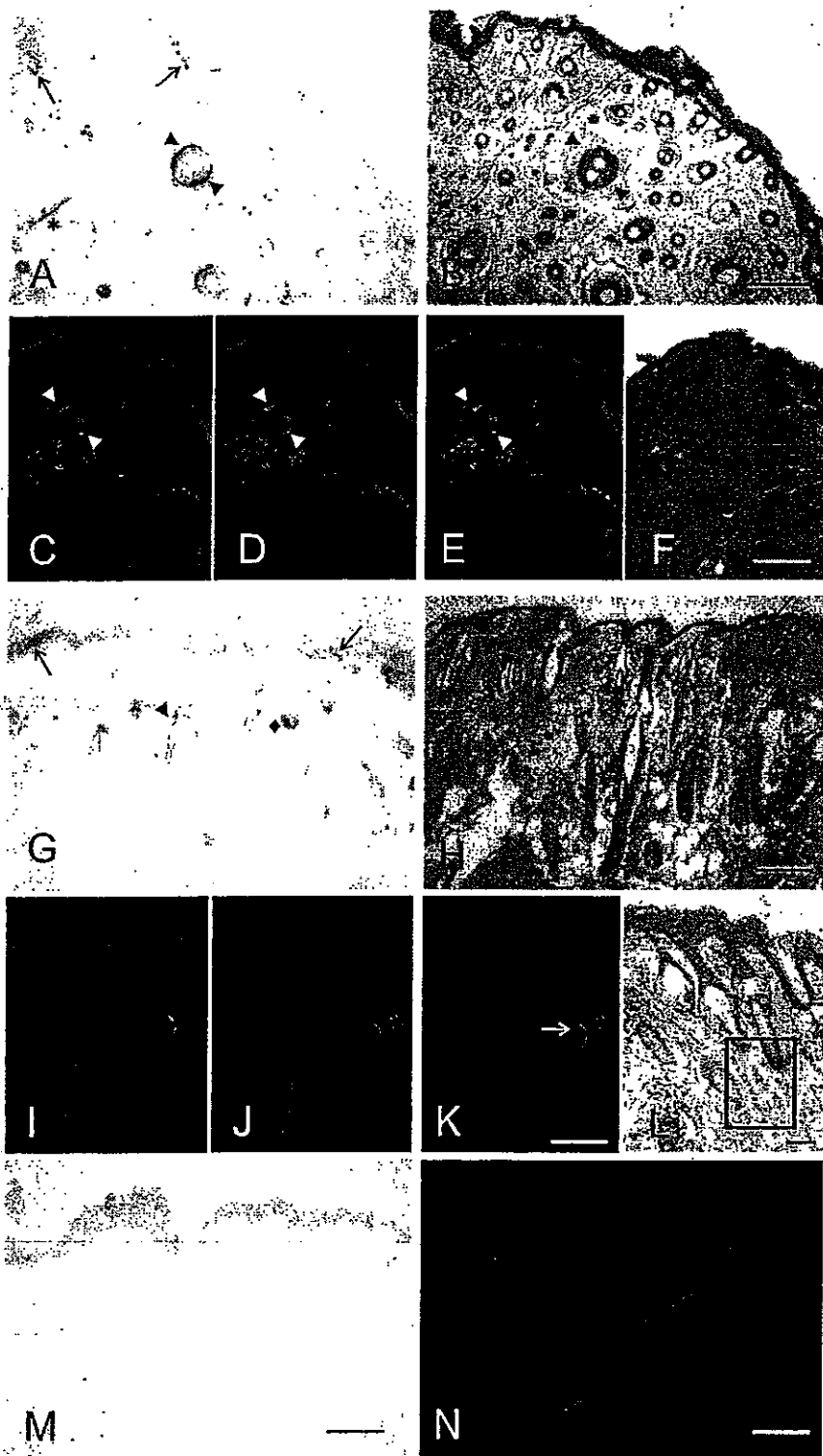Figure 2. Location of PrP^{Sc} within the Skin of Hamsters Orally Infected with Scrapie

(A–H) Topographical localisation of PrP^{Sc} in sections of skin samples from the snout (A and B) and the forelimb (G and H); (A and G) PET blots, (B and H) H&E staining. PrP^{Sc} was detected in free nerve endings of the subepidermal plexus on the border of the epidermis to the dermis ([A], [B], [G], and [H], arrows), in fibres of the subepidermal, the deep cutaneous and the subcutaneous plexus, in circular and longitudinal fibres of the follicular neural network of the hair ([A], [B], and [G], arrowheads), in the hair follicle isthmus ([G]; rhombus), and in small intradermal striated fibres of mimic muscles ([A and B], asterisks).

(C–F) Visualisation of PrP^{Sc} and nerve fibres in the neural network of hair follicles by fluorescence microscopy (skin sample from the abdomen). Co-localisation of PrP^{Sc} (C) with nerve fibres labelled by using an anti-S-100 protein antibody against Schwann cells (D). (E) Merged figure from micrographs (C and D). (F) Adjacent section to (C), stained with H&E.

(I–K) Visualisation of PrP^{Sc} and nerve fibres in the cutaneous plexus by fluorescence microscopy (skin sample from the snout). Co-localisation of PrP^{Sc} (I) with nerve fibres labelled by using the anti-neurofilament antibody SMI 31 (J). (K) Merged figure from micrographs (I and J). (L) Adjacent section to (I), stained with H&E. The box indicates the region used for the immunofluorescence stainings in (I–K). (M and N) Control skin samples from the forelimb of a hamster perorally mock-challenged with normal hamster brain homogenate; PET blot (M) and fluorescence microscopy for PrP and neurofilament (N). Scale bars = 200 μ m for (B, F, H, and M), 50 μ m for (K and L), and 25 μ m for (N). Same scale bars as displayed in (B), (F), (H), and (K) apply to (A), (C–E), (G), and (I and J), respectively.
doi:10.1371/journal.ppat.0030066.g002

antibodies binding to neurofilament or Schwann cells [20,21]. By using an anti-S-100 protein antibody detecting Schwann cells, a co-localisation of PrP^{Sc} with nerve fibres of the follicular neuronal network of hairs was observed (Figure 2C–2E, arrowheads). By antibody-labelling of neurofilament, nerve fibres of the cutaneous plexus were found to display a co-localisation with PrP^{Sc} (Figure 2I–2K; for topological orientation, see Figure 2L). Occasionally, we observed PrP^{Sc} deposition in nerve-like structures of the subepidermal plexus showing no immunostaining for neurofilament (not shown). This may have resulted from infection of nerve fibres that do not contain neurofilament [20], or, alternatively, from PrP^{Sc} deposition in Schwann cells rather than in the neurite itself [22]. Control skin samples from the forelimb of a

hamster perorally mock-challenged with normal hamster brain homogenate were found negative for PrP^{Sc} by PET blotting and fluorescence microscopy (Figure 2M and 2N).

Accumulation of PrP^{Sc} in the Skin Shows No Dependence on the Route of Infection and Lymphotropic Spread

In order to examine whether accumulation of PrP^{Sc} in the skin depends on the mode of infection and spreading pathways other than the nervous system, skin specimens from the forelimb and hindlimb of terminally ill hamsters challenged with 263K scrapie agent by different routes were analyzed using the same analytical approach as described above for the time-course study. The following modes of inoculation were compared: oral (p.o.) infection with scrapie brain homogenate (Figure 3A, lanes 4 and 5), intracerebral (i.c.) infection with scrapie brain homogenate (Figure 3A, lanes 6 and 7), i.c. infection by implantation of steel wires (s.w.) contaminated with scrapie agent (Figure 3A, lanes 8 and 9), and peripheral foot pad (f.p.) infection with scrapie brain homogenate (Figure 3A, lanes 10 and 11). PrP^{Sc} could be detected in all analyzed skin specimens from hamsters at the terminal stage of scrapie independently of the route of infection. Amounts of PrP^{Sc} in skin tissue were about 5,000- to 10,000-fold lower than those found in brain, as estimated from positive controls of skin samples from orally mock-infected hamsters that were spiked with 1×10^{-6} g, 5×10^{-6} g, or 1×10^{-5} g of homogenized 263K scrapie hamster brain from terminally ill donors before extraction (Figure 3A, lanes 1–3). PrP^{Sc} was consistently absent in skin specimens from mock-infected hamsters, which served as negative controls (Figure 3A, lanes 12 and 13).

The employed routes of inoculation were found to produce substantial differences in the extent of lymphotropic spread of agent. In orally or intracerebrally challenged hamsters, spleens (Figure 3B, lanes 2 and 4), mesenteric lymph nodes (Figure 3B, lanes 6 and 8) and retropharyngeal lymph nodes (not shown) consistently showed PrP^{Sc} deposition, whereas in five out of six hamsters infected by implantation of contaminated s.w., no PrP^{Sc} could be found in the examined spleens and lymph node specimens (Figure 3B, lanes 3 and 7). Only one of the s.w.-infected animals displayed a weak Western blot signal for PrP^{Sc} in the spleen (not shown). Thus, in comparison to the i.c. or p.o. route of inoculation, lymphotropic spread was much less pronounced—or even undetectable—following infection of hamsters by i.c. implantation of 263K-contaminated s.w. However, despite this marked discrepancy, the intensity of skin-associated deposits of PrP^{Sc} found in s.w.-infected hamsters did not show significant differences from that observed for p.o.- or i.c.-challenged animals upon Western blotting (Figure 3A, lines 8 and 9 versus lines 4–7). To determine whether the route of administration of PrP^{Sc} influences the topographical distribution of disease-associated prion protein in the skin, we investigated samples from hamsters infected with 263K-

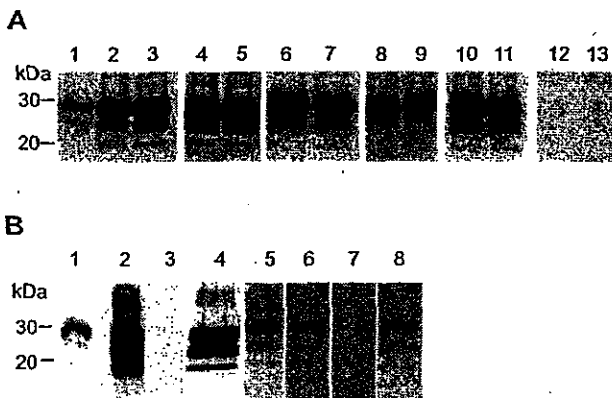


Figure 3. PrP^{Sc} Routing to the Skin and to Components of the Lymphoreticular System of Hamsters Challenged via Different Routes with 263K Scrapie Agent

(A) Western blot detection of PrP^{Sc} in skin specimens from terminally ill scrapie hamsters. Lanes 1, 2, and 3: skin samples from orally mock-infected control hamsters, spiked before extraction with 1×10^{-6} g, 5×10^{-6} g, or 1×10^{-5} g of brain homogenate from terminally ill 263K hamsters. Lanes 4 and 5: skin samples from hindlimbs and forelimbs of hamsters orally infected with scrapie brain homogenate. Lanes 6 and 7: skin samples from hindlimbs and forelimbs of hamsters intracerebrally infected with scrapie brain homogenate. Lanes 8 and 9: skin samples from hindlimbs and forelimbs of hamsters infected by implantation of s.w. contaminated with scrapie agent. Lanes 10 and 11: skin samples from hindlimbs and forelimbs of hamsters infected peripherally by f.p. inoculation of scrapie brain homogenate. Lanes 12 and 13: skin samples from hindlimbs and forelimbs of hamsters orally mock-infected with normal brain homogenate. Amounts of tissue represented in lanes: 1, 53 mg; 2, 58 mg; 3, 68 mg; 4, 68 mg; 5, 75 mg; 6, 78 mg; 7, 64 mg; 8, 69 mg; 9, 60 mg; 10, 62 mg; 11, 73 mg; 12, 61 mg; 13, 58 mg.

(B) Western blot detection of PrP^{Sc} in spleens and selected lymph nodes from terminally ill scrapie hamsters. Lanes 1 and 5: proteinase K-digested brain homogenate from terminally ill scrapie hamsters, containing 1×10^{-7} g brain tissue. Lanes 2–4: spleen samples from p.o.- (2), s.w.- (3) and i.c.-infected (4) hamsters. Lanes 6–8: mesenteric lymph node samples from p.o.- (6), s.w.- (7) and i.c.-infected (8) hamsters. Amounts of tissue represented in lanes: 2, 40 mg; 3, 45 mg; 4, 41 mg; 6, 6 mg; 7, 8 mg; 8, 6 mg.

doi:10.1371/journal.ppat.0030066.g003

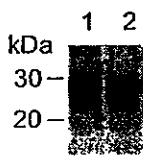


Figure 4. Western Blot Detection of PrP27–30 in Skin Specimens of Hamsters Intracerebrally Challenged with BSE-H Agent

Lanes 1 and 2: skin samples from hindlimb and forelimb of a BSE-infected hamster. Amounts of tissue represented in lanes: 1, 43 mg; 2, 58 mg. doi:10.1371/journal.ppat.0030066.g004

contaminated s.w. at the clinical disease stage using the PET blot method. This revealed that the morphological distribution pattern of PrP^{Sc} in the skin of s.w.-infected animals was identical to that found in orally infected hamsters (not shown).

BSE-Associated PrP^{Sc} in the Skin

To test whether not only scrapie-associated PrP^{Sc} but also BSE-associated PrP^{Sc} accumulates in the skin, hamsters were intracerebrally infected with a hamster-adapted BSE (BSE-H) agent and sacrificed at the end stage of disease. All analyzed skin specimens from forelimbs and hindlimbs of five donor animals showed substantial amounts of BSE-associated PrP27–30 (Figure 4, lanes 1 and 2). Thus, following i.c. infection, the targeting of BSE-H agent to the skin, as probed by Western blotting, did not show discernible differences compared to that observed for 263K scrapie.

PrP^{Sc} in Skin Tissue of Sheep Naturally Infected with Scrapie

In a follow-up proof-of-concept study, which aimed to validate and expand our findings from the hamster experiments, five sheep naturally infected with scrapie in the field were analyzed for the presence of PrP^{Sc} in skin specimens from different body regions (head, snout, hindlimb, forelimb, perianal, axillar, and inguinal). PrP^{Sc} was visualized by Western blotting after extraction in the form of PrP27–30 from tissue samples using the anti-ovine PrP monoclonal antibodies ICSM-18 or P4. Positive specimens were found in two out of the five tested sheep: In sheep Sc3, PrP27–30 was present in a sample from the inguinal region (Figure 5, lane 5). Sheep Sc5 showed PrP27–30 in a sample from the perianal region, which was a scratching site of this animal (Figure 5, lane 6). For control purposes, a deglycosylation of a PrP27–30 extract from the same skin region of this animal was performed (Figure 5, lane 7). Furthermore, a skin sample from the snout was found positive for PrP27–30 in animal Sc5 upon detection with the ICSM-18 antibody (Figure 5, lane 8) and the anti-PrP antibody P4 (Figure 5, lane 9). All other analyzed skin specimens of the five sheep did not show specific Western blot signals for PrP27–30. Specimens from the same skin regions of four uninfected sheep served as controls and consistently produced negative results (Figure 5, lanes 10–12).

Discussion

In this study we have shown that the skin provides a reservoir for PrP^{Sc}, the biochemical marker of prion infectivity, in five different hamster TSE models, independ-

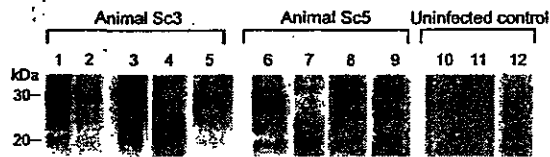


Figure 5. PrP^{Sc} in Skin Samples from Different Body Areas of Sheep Naturally Infected with Scrapie

Western blot detection of PrP27–30, the protease-resistant core of PrP^{Sc}, using the anti-PrP antibodies ICSM-18 (lanes 1–8, 10–12) and P4 (lane 9). Samples are from sheep Sc3 (lanes 1–5), sheep Sc5 (lanes 6–9), and from an uninfected control sheep. Lanes 1 and 2: different amounts of brain homogenate (0.5 mg/lane and 0.1 mg/lane of midbrain tissue, respectively) from sheep Sc3. Lane 3: tonsil sample. Lane 4: tonsil sample after deglycosylation with PNGaseF. Lane 5: skin sample from the inguinal region. Lane 6: skin sample from the perianal region (scratching area). Lane 7: skin sample from the same region as in lane 6 after deglycosylation with PNGaseF. Lane 8: skin sample from the snout. Lane 9: skin sample from the same region as in lane 8, but detected with the antibody P4. Lanes 10–12: negative controls of skin samples from different body regions of an uninfected sheep. Amounts of tissue represented in lanes: 1, 0.5 mg; 2, 0.1 mg; 3, 7 mg; 4, 2 mg; 5, 88 mg; 6, 89 mg; 7, 23 mg; 8, 90 mg; 9, 92 mg; 10, 80 mg; 11, 87 mg; 12, 94 mg. doi:10.1371/journal.ppat.0030066.g005

ently of whether the animals were challenged with scrapie via the p.o., i.c., or f.p. route, cerebral implantation of scrapie-contaminated s.w., or i.c. inoculation of a hamster-adapted BSE agent. Furthermore, PrP^{Sc} could be demonstrated for the first time in skin specimens from sheep naturally infected with scrapie, though in a limited number of sites investigated and at low amounts. In a time-course study using hamsters fed with scrapie agent, we were able to detect PrP^{Sc} in the skin before the onset of clinical symptoms, but the bulk of skin-associated PrP^{Sc} accumulated in the clinical phase of the disease. From our Western blot findings, the final concentration of PrP^{Sc} in the skin of hamsters seems to be approximately 5,000–10,000 times lower than that found in the brain. This would correspond to an infectivity titre of $\sim 1 \times 10^5$ to 2×10^5 50% i.c. infective doses (ID_{50,i.c.}) per gram of skin tissue. A similar infectivity titre was previously estimated from Western blot findings for skeletal muscle tissue of clinically ill hamsters perorally challenged with 263K scrapie [23].

Pathophysiology of PrP^{Sc} Deposition in the Skin

Our immunohistochemical and PET blot studies, performed on skin specimens from hamsters orally infected with scrapie in order to elucidate the topographical location of PrP^{Sc} in the skin, revealed PrP^{Sc} in small nerve fibres within the dermis but not in keratinocytes. Keratinocytes have been shown to express PrP^C [24,25], and it remains to be established in future studies why this cell type—other than, for example, myocytes—does not support a detectable formation of PrP^{Sc}. Irrespective of this uncertainty, the topographical dermal location of PrP^{Sc}, which is essentially restricted to neural structures together with the late occurrence of the PrP^{Sc} in the skin, point to an invasion via centrifugal spread of infection along peripheral nerves. The time-course of PrP^{Sc} accumulation in the skin, and the putative neural spreading pathways used by prions to target this organ, are strongly reminiscent of what has been previously observed for muscle tissue in the same animal model [11]. In order to further examine whether pathways other than the nervous system may be involved in the spread

of prions to the skin, a group of hamsters was intracerebrally infected by implantation of s.w. contaminated with scrapie agent. In this experimental paradigm, lymphotropic spread of scrapie agent through the body, as evidenced by testing the spleen and selected lymph nodes for PrP^{Sc}, was not detectable in five out of six animals. Only in the spleen of one hamster from the s.w. group was a weak signal for PrP^{Sc} found. This is indicative of a splenic infection, which occurred only relatively late in the incubation period, possibly via the peripheral nervous system. Despite the striking absence of detectable lymphotropic spread in s.w.-infected hamsters, these animals produced a practically indistinguishable skin-associated accumulation of PrP^{Sc} from that observed for p.o.- or i.c.-challenged hamsters. Thus, propagation of infection to the skin did not show a crucial dependence on lymphotropic spreading pathways. Whether a blood-borne dissemination of agent contributes to the PrP^{Sc} contamination of skin additionally to neurally mediated invasion remains to be established.

Skin-Associated PrP^{Sc} Deposition in Sheep Naturally Infected with Scrapie

The Western blot examination of skin specimens from five sheep clinically affected with natural scrapie in the field revealed the presence of PrP^{Sc} in a sample from the inguinal region of one animal, and in two samples from the snout and perianal region of another sheep. The perianal region was a scratching site of this animal but did not show macroscopically visible skin alterations. Although the exact anatomical location of skin-associated PrP^{Sc} in ovine scrapie remains to be determined, our findings clearly demonstrate that the skin of sheep naturally infected with scrapie can provide a reservoir for prions at least at late stages of incubation. The results with skin samples from scrapie-infected sheep are in good accordance with the Western blot findings in hamsters, and the anatomical organisation of hamster and sheep skin shows considerable similarities. However, because of possible anatomical differences, histological findings in hamsters cannot be extended directly to sheep without further immunohistochemical and/or PET blot examinations in ovines. Also, for a more precise assessment of potential risks possibly emanating from prions in the skin of scrapie-infected sheep, multiple tissue sites and larger numbers of animals, including those pre-clinically incubating the disease, and random case control studies are required.

Our findings raise the question of whether prions present in specific components of the skin such as peripheral nerve fibres may be involved in the natural transmission of scrapie. Dissemination of infectivity from the skin into the environment could theoretically take place at skin lesions such as scrapie-induced chafing sites and other wounds or ulcers, and vectors found to be able to harbour infectivity (e.g., mites [26] or larvae and pupae [27]) may possibly take up prions from the skin of affected sheep. In this context, it has to be noted that inflammatory processes [25,28] may enhance the load of prions in infected skin regions, and that an increase of cellular prion protein expression was observed in keratinocytes of human patients with inflammatory skin diseases [24]. Furthermore, practises of sheep shearing may account for transmission of scrapie from reservoirs in the skin. Shearing causes skin wounds in up to a third of the sheared animals, and the skin may not only provide a reservoir of prions but

also an efficient portal of entry for scrapie agent into the body [29,30]. However, previous studies on the presence of infectivity in which various tissues from scrapie-infected sheep or goats were tested did not point to the skin as a highly relevant reservoir of prions in small ruminants [31]. Furthermore, a substantial body of evidence suggests that many, if not the majority of cases of ovine scrapie, are caused by peroral uptake of TSE agents and subsequent invasion of the organism via the alimentary tract [32–35]. Contaminated placenta [31,36], saliva (as recently reported in the context of CWD) [37], or possibly feces or urine [38] appear to provide more relevant candidate sources of infection than the skin in the horizontal or vertical transmission of scrapie. Thus, whether and to what degree the skin plays a role in the spread of contagious scrapie in the field, and whether BSE-infected cattle, CWD-infected deer or vCJD-infected humans may also accumulate PrP^{Sc} in the skin, remains to be established in future studies.

Materials and Methods

Experiments in laboratory animals. All animal experiments were performed in accordance with European and German legal and ethical regulations and approved by the responsible review boards and authorities.

p.o. infection with scrapie brain homogenate. Outbred Syrian hamsters were fed individual food pellets doused with 100 μ l of a 10% (w/v) hamster brain homogenate (corresponding to 10 mg of tissue) from terminally ill 263K scrapie-infected donors or uninfected controls as previously described [11]. Scrapie-infected animals were humanely sacrificed by exposure to CO₂ at 70 dpi (n=5), 100 dpi (n=5), and 130 dpi (n=5), at the onset of at least two clinical signs for scrapie such as tremor of head or whole body, incoordination of gait, or difficulty in rising up from a supine position (n=5; 138 dpi, 138 dpi, 139 dpi, 142 dpi, and 146 dpi), and at the terminal stage of disease (n=5; 157 dpi, 158 dpi, 165 dpi, 169 dpi, and 171 dpi). Control animals, i.e., mock-challenged age-matched hamsters (three for each time-point), were sacrificed at corresponding time points.

i.c. infection with scrapie brain homogenate. Five outbred Syrian hamsters were intracerebrally infected with 50 μ l aliquots of 1% (w/v) hamster brain homogenates in Tris-buffered saline (TBS) 10 mM Tris HCl, 133 mM NaCl (pH 7.4) from terminally ill donors challenged with 263K or BSE-H agent, or from uninfected control hamsters. The BSE-H agent was isolated in our laboratory after one passage of BSE agent from cattle in mice and subsequent transmission to hamsters [39]. The recipients (n=5 for 263K, n=6 for BSE-H) were humanely sacrificed at the end stage of clinical disease at the following dpi: 263K—83, 84, 87, 90, and 93 dpi; BSE-H—296, 296, 300, 310, 317, and 324 dpi.

i.c. infection by implantation of s.w. contaminated with scrapie agent. s.w. contaminated with 10% (w/v) brain homogenate from 263K scrapie hamsters were prepared as previously described [40] and intracerebrally implanted under anesthesia into reporter animals using a stereotaxic apparatus (K. Lemmer, M. Mielke, G. Pauli, and M. Beekes, unpublished data). Animals (n=4) were humanely sacrificed at the terminal stage of scrapie at the following dpi: 91, 91, 91, and 106.

f.p. infections with scrapie brain homogenate. Outbred Syrian hamsters were challenged peripherally via the f.p. as described elsewhere [41] by inoculation of 50 μ l of 1% (w/v) hamster brain homogenates in TBS from terminally ill 263K scrapie hamsters. Sacrification was performed humanely at the terminal stage of disease at the following dpi (n=4): 117, 117, 131, and 147.

Sample preparations. *Preparation of hamster tissue samples for Western blot analyses.* After sacrifice, skin specimens from different regions of the body were dissected and the fur was removed by shaving. The skin specimens consisted of epidermis, dermis, and subcutis. All samples were cut into small pieces and stored at -80 °C until examination. The mass of the skin samples used for Western blot analyses ranged from approximately 40 to 100 mg. Instruments used for the preparation of samples were carefully cleaned after removal and processing of each specimen in order to avoid cross-contamination. Skin samples from the hindlimb, forelimb, head, back, and abdomen were taken from p.o.- and s.w.-infected animals. From the hamsters i.c.- or f.p.-inoculated with 263K scrapie and the animals i.c.-



The aliquots were digested using PNCase F (New England Biolabs, extracted pellets were dissolved in 20 μ l of a bidet and one fourth of was prepared as outlined previously [23]. For deglycosylation [23], brains, used as P1P27-30 reference in the Western blotting analyses. Proteinase K-digested homogenate from 263K scrapie hamster tissue homogenates following a previously published protocol [23]. Subsequently, P1P27 was extracted in the form of P1P27-30 from the pellet consisting of cell debris and the rest of the fat was removed. The supernatant was carefully transferred to a new cup, whereas 500g. The supernatant was centrifuged for 3 min at 500g. After ultrasonication to disrupt prior to collagenase digestion. After ultrasonication to disrupt from i.c.-infected donors containing approximately 0.5 ng of P1P27 [3] (v) 263K scrapie hamster brain homogenate (i.e., 5 μ g of brain tissue) mock-infected control donors was spiked by adding 5 μ l of a 0.1% (w/ http://www.roche.com). For positive controls, skin tissue from orally TBS containing 2 mM CaCl₂ and 0.25% (w/v) collagenase A (Roche, 741) and incubated in a rocking device at 37 °C for 4 h in 900 μ l of were washed three times in TBS (10 mM Tris HCl, 135 mM NaCl [pH Western blot examinations. For Western blot analyses, samples prevalent genotypes in scrapie-affected sheep. However, that ARQ/ARQ and AHQ/ARQ do not provide the most selection when used for further breeding. It has to be noted, that genetically have little resistance to scrapie and will need careful ARQ and AHQ/ARQ belong to risk group 3, which refers to "sheep the National Scrapie Plan for Great Britain [42], the genotypes ARQ/ codons 156, 154, and 171 of the prion protein gene, four of them the tonsils from all scrapie sheep (not shown). At the polymorphic cerebellum. Apart from animal S4, P1P27 could also be detected in international des Epizooties standards by histopathology and by immunohistochemical detection of P1P27 in the brain stem and present. The diagnosis of scrapie was confirmed according to Office legs over the carpal and tarsal joints where the straight coat becomes woolly. In all scrapie-infected animals, a marked weight loss was due to scrubbing their coat. They also nibbled off their fleece on the years as determined by their dental status and showed loss of wool four scrapie-free control sheep. All scrapie cases were older than 4 in this study originated from five scrapie cases (Table 1, S1-S5) and an index scrapie case in the respective flock. The samples analysed autopsies of cohort animals that were eradicated after identification samples from field cases of ovine scrapie were collected during

Sample preparation from sheep naturally infected with scrapie. Skin and a subset was stained with haematoxylin and eosin (H&E). 48 h and embedded in paraffin. Sections were placed on glass slides isopropanol, 30% dichloromethane, and 10% acetic acid for up to hydride (4% [w/v] in PBS) or Carnoy's solution containing 60% petal or s.w. infection and from age-matched perovally mock-infected control sacrificed at corresponding time-points. The speci- from hamsters that developed terminal symptoms of scrapie after and location of P1P27 in the skin, specimens from the head, the snout, the abdomen, and the foreleg were collected. Samples were taken

Table 1. Scrapie-Infected Sheep Tested for P1P27 in the Skin

Animal	Genotype ^a	Age ^b	P1P27 in Brainstem	P1P27 in Cerebellum
S1	ARQ/ARQ	> 4 years	Yes	Yes
S2	ARQ/ARQ	> 4 years	Yes	Yes
S3	ARQ/ARQ	> 4 years	Yes	Yes
S4	AHQ/ARQ	> 4 years	Yes	Yes
S5	ARQ/ARQ	> 4 years	Yes	Yes

^aThe genotype is specified for the polymorphic codons 136, 154, and 171 of the ovine prion protein gene.
^bAge was determined by the dental status of the animals.
doi:10.1371/journal.ppat.0030066.t001

forelimb and hindlimb. inoculated with BSE-H agent, skin samples were dissected from the

immunohistochemical examinations. Frozen tissue sections as well as Carnoy-fixed sections of about 4 μ m were postfixed in paraf- maldialdehyde (4% [w/v] in PBS) for 1 h and washed in tap water to avoid pigment deposition. Antigen retrieval was done using 4 M guanidine hydrochloride for 25 min and by microwaving five times for 3 min at 700 watts in 1 M citric acid at pH 6.0. After blocking with 0.2% casein in TBST, the primary antibody 3F4 (diluted 1:200) was used for P1P27 detection. Antibodies against S-100 protein (rabbit polyclonal, 1:200 in PBS; Dako) and neurofilament (SMI31 mouse monoclonal IgG1, 1:20,000 in PBS; Sternberger Monoclonals, http://www.crpinc.com) were applied to detect small nerve fibres. As secondary antibody, a HRP-conjugated goat anti-mouse IgG1 antibody (1:400 in PBS; Dianova, http://www.dianova.de) was used for detecting the antibody HRP-conjugated goat anti-rabbit antibody (EnVision, Dako). For 3F4 double-staining, we used a biotinylated goat anti-mouse IgG2a antibody (1:400 in PBS; Dianova) or a goat anti-mouse IgG antibody without restriction to Ig-subclasses (1:100; Dako). Visualization of the different epitopes was performed using Cy3-conjugated streptavidin (green fluorescence, 1:500; Dianova) and a Cy5-conjugated goat anti-HRP antibody (red fluorescence, 1:100; Dianova). Slides were examined on an Olympus fluorescent microscope using analysis software, and Adobe Photoshop software was used for picture processing.

Acknowledgments

The skillful technical assistance of Marton Jönck, Andrea Männel, veterinary infectological aspects and the helpful discussion of Gensundheit, and the European Network of Excellence "NeuroPrion" for their sustained support. Author contributions. AT and MB conceived and designed the experiments. AT, WSS, AW, WW, BB, CK, and MB performed the experiments. AT, WSS, AW, WW, BB, CK, and MB wrote the paper. Funding. This work was supported in part by grants from the European Union (QLG3-CT-2002-81030, Food-CT-2004-506579), and the Volkswagen Foundation (ZN 1294). Competing interests. The authors have declared that no competing interests exist.

http://www.neb.com) according to the instructions of the manufacturer prior to Western blotting. Sodium dodecyl sulfate-polyacrylamide gel electrophoresis (SDS-PAGE) and Western blot analyses of samples from hamsters were performed elsewhere [23]. Western blot testing for P1P27 in skin samples from scrapie-infected sheep was similarly performed using the primary antibodies ICSM-18 and P4 to label the ovine prion protein. P1P27 signals were visualized on an X-OMAT AR (Kodak, http://www.kodak.com) film. Films were exposed for 5–30 min.

PET blot examinations. The PET blot detection of proteinase K-resistant PrP deposits in sections of skin samples was performed on parafomaldehyde- and Carnoy-fixed specimens. For PET blot examinations of skin tissue, modifications of the original protocol [43] were necessary to remove connective tissue. After prewashing blots with TBST (10 mM TrisHCl [pH 7.8], 100 mM NaCl, 0.05% [w/v] Tween 20), sections were digested with 1.5 mg/ml collagenase A (Roche) in a buffer containing 10 mM TrisHCl (pH 7.8), 100 mM NaCl, 100 mM CaCl₂, and 0.1% (w/v) Brij 35 for 30 min at 60 °C, followed by digestion using 250 μ g/ml proteinase K (Roche) in PK digestion buffer (10 mM TrisHCl [pH 7.8], 100 mM NaCl, 0.1% Brij 35) for 8 h at 55 °C. After this step, the membrane-attached proteins were fixed to the membrane. The proteins on the membranes were denatured with 3 M guanidine isothiocyanate in 10 mM TrisHCl (pH 7.8) for 20 min. Immunodetection was performed after preincubation in blocking solution (0.2% [w/v] casein in TBST) for 30 min. The monoclonal antibody 3F4 (1:44), diluted 1:3,000) was used as primary antibody and an alkaline phosphatase-coupled rabbit anti-mouse secondary antibody (Dako, http://www.dako.com) at a dilution of 1:500 as well as NBT/BCIP. Blots were examined using an Olympus dissecting microscope.

P1P27 in the Skin

References

- Prusiner SB (1998) Prions. *Proc Natl Acad Sci U S A* 95: 13363–13368.
- Beekes M, McBride P (2007) The spread of prions through the body in naturally acquired transmissible spongiform encephalopathies. *FEBS J* 274: 588–605.
- Beekes M, Baldauf E, Diringer H (1996) Sequential appearance and accumulation of pathognomonic markers in the central nervous system of hamsters orally infected with scrapie. *J Gen Virol* 77: 1925–1934.
- van Keulen LJ, Vromans ME, van Zijderfeld FG (2002) Early and late pathogenesis of natural scrapie infection in sheep. *APMIS* 110: 23–32.
- Ironside JW (2000) Pathology of variant Creutzfeldt-Jakob disease. *Arch Virol Suppl*: 143–151.
- Wadsworth JD, Joiner S, Hill AF, Campbell TA, Desbruslais M, et al. (2001) Tissue-distribution of protease resistant prion protein in variant Creutzfeldt-Jakob disease using a highly sensitive immunoblotting assay. *Lancet* 358: 171–180.
- Mabbott NA, MacPherson GG (2006) Prions and their lethal journey to the brain. *Nat Rev Microbiol* 4: 201–211.
- Bruce ME, Will RG, Ironside JW, McConnell I, Drummond D, et al. (1997) Transmissions to mice indicate that 'new variant' CJD is caused by the BSE agent. *Nature* 389: 498–501.
- McBride PA, Schulz-Schaeffer WJ, Donaldson M, Bruce M, Diringer H, et al. (2001) Early spread of scrapie from the gastrointestinal tract to the central nervous system involves autonomic fibers of the splanchnic and vagus nerves. *J Virol* 75: 9320–9327.
- Beekes M, McBride PA, Baldauf E (1998) Cerebral targeting indicates vagal spread of infection in hamsters fed with scrapie. *J Gen Virol* 79: 601–607.
- Thomzig A, Schulz-Schaeffer W, Kratzel C, Mai J, Beekes M (2004) Preclinical deposition of pathological prion protein PrP^{Sc} in muscles of hamsters orally exposed to scrapie. *J Clin Invest* 113: 1465–1472.
- Andréoletti O, Simon S, Lacroux C, Morel N, Tabouret G, et al. (2004) PrP^{Sc} accumulation in myocytes from sheep incubating natural scrapie. *Nat Med* 10: 591–593.
- Peden AH, Ritchie DL, Head MW, Ironside JW (2006) Detection and localization of PrP^{Sc} in the skeletal muscle of patients with variant, iatrogenic, and sporadic forms of Creutzfeldt-Jakob disease. *Am J Pathol* 168: 927–935.
- Herzog C, Riviere J, Lescoeur-Etcheagaray N, Charbonnier A, Leblanc V, et al. (2005) PrP^{Sc} distribution in a primate model of variant, sporadic, and iatrogenic Creutzfeldt-Jakob disease. *J Virol* 79: 14339–14345.
- Paus R, Peters EM, Eichmüller S, Botchkarev VA (1997) Neural mechanisms of hair growth control. *J Invest Dermatol Symp Proc* 2: 61–68.
- Zanusso G, Ferrari S, Cardone F, Zampieri P, Gelati M, et al. (2003) Detection of pathologic prion protein in the olfactory epithelium in sporadic Creutzfeldt-Jakob disease. *N Engl J Med* 348: 711–719.
- Gonzalez L, Jeffrey M, Siso S, Martin S, Bellworthy SJ, et al. (2005) Diagnosis of preclinical scrapie in samples of rectal mucosa. *Vet Rec* 156: 846–847.
- Cunningham AA, Kirkwood JK, Dawson M, Spencer YI, Green RB, et al. (2004) Bovine spongiform encephalopathy infectivity in greater kudu (*Tragelaphus strepsiceros*). *Emerg Infect Dis* 10: 1044–1049.
- Safar J, Wille H, Itri V, Groth D, Serban H, Torchia M, Cohen FE, Prusiner SB (1998) Eight prion strains have PrP^{Sc} molecules with different conformations. *Nat Med* 4: 1157–1165.
- Lauria G, Borgna M, Morbin M, Lombardi R, Mazzoleni G, et al. (2004) Tubule and neurofilament immunoreactivity in human hairy skin: Markers for intraepidermal nerve fibers. *Muscle Nerve* 30: 310–316.
- Botchkarev VA, Eichmüller S, Johansson O, Paus R (1997) Hair cycle-dependent plasticity of skin and hair follicle innervation in normal murine skin. *J Comp Neurol* 386: 379–395.
- Herzog C, Sales N, Etcheagaray N, Charbonnier A, Freire S, Dormont D, Deslys JP, Lasmezas CI (2004) Tissue distribution of bovine spongiform encephalopathy agent in primates after intravenous or oral infection. *Lancet* 363: 422–428.
- Thomzig A, Kratzel C, Lenz G, Krüger D, Beekes M (2003) Widespread PrP^{Sc} accumulation in muscles of hamsters orally infected with scrapie. *EMBO Rep* 4: 530–533.
- Pammer J, Weninger W, Tschachler E (1998) Human keratinocytes express cellular prion-related protein in vitro and during inflammatory skin diseases. *Am J Pathol* 153: 1353–1358.
- Pammer J, Tschachler E (2002) A possible role of keratinocytes of skin and mucous membranes in prion propagation and transmission. *J Invest Dermatol Symp Proc* 7: 59–63.
- Wisniewski HM, Sigurdarson S, Rubenstein R, Kascsak RJ, Carp RI (1996) Mites as vectors for scrapie. *Lancet* 347: 1114.
- Post K, Riesner D, Walldorf V, Mehlhorn H (1999) Fly larvae and pupae as vectors for scrapie. *Lancet* 354: 1969–1970.
- Heikenwalder M, Zeller N, Seeger H, Prinz M, Klohn PC, et al. (2005) Chronic lymphocytic inflammation specifies the organ tropism of prions. *Science* 307: 1107–1110.
- Taylor DM, McConnell I, Fraser H (1996) Scrapie infection can be established readily through skin scarification in immunocompetent but not immunodeficient mice. *J Gen Virol* 77: 1595–1599.
- Mohan J, Brown KL, Faruhat CF, Bruce ME, Mabbott NA (2004) Scrapie transmission following exposure through the skin is dependent on follicular dendritic cells in lymphoid tissues. *J Dermatol Sci* 35: 101–111.
- World Health Organization (2006) Annex 1. In: Guidelines on tissue infectivity distribution in transmissible spongiform encephalopathies. Geneva: WHO Press. pp. 22–32.
- Pattison IH, Hoare MN, Jebbett JN, Watson WA (1974) Further observations on the production of scrapie in sheep by oral dosing with foetal membranes from scrapie-affected sheep. *Br Vet J* 130: lxxv–lxxvii.
- Hadlow WJ, Kennedy RC, Race RE (1982) Natural infection of Suffolk sheep with scrapie virus. *J Infect Dis* 146: 657–664.
- Andreoletti O, Berthon P, Marc D, Sarradin P, Grosclaude J, van KL, Schelcher F, Eisen JM, Lantier F (2000) Early accumulation of PrP^{Sc} in gut-associated lymphoid and nervous tissues of susceptible sheep from a Romanov flock with natural scrapie. *J Gen Virol* 81: 3115–3126.
- van Keulen LJ, Schreuder BE, Vromans ME, Langeveld JP, Smits MA (2000) Pathogenesis of natural scrapie in sheep. *Arch Virol Suppl* 145: 57–71.
- Race R, Jenny A, Sutton D (1998) Scrapie infectivity and proteinase K-resistant prion protein in sheep placenta, brain, spleen, and lymph node: Implications for transmission and antemortem diagnosis. *J Infect Dis* 178: 949–953.
- Mathison CK, Powers JC, Dahmes SJ, Osborn DA, Miller KV, et al. (2006) Infectious prions in the saliva and blood of deer with chronic wasting disease. *Science* 314: 133–136.
- Siso S, Gonzalez L, Jeffrey M, Martin S, Chianini F, et al. (2006) Prion protein in kidneys of scrapie-infected sheep. *Vet Rec* 159: 327–328.
- Thomzig A, Spassov S, Friedrich M, Naumann D, Beekes M (2004) Discriminating scrapie and bovine spongiform encephalopathy isolates by infrared spectroscopy of pathological prion protein. *J Biol Chem* 279: 33847–33854.
- Lemmer K, Mielke M, Pauli C, Beekes M (2004) Decontamination of surgical instruments from prion proteins: In vitro studies on the detachment, destabilization and degradation of PrP^{Sc} bound to steel surfaces. *J Gen Virol* 85: 3805–3816.
- Kratzel C, Mai J, Madela K, Beekes M, Krüger D (2007) Propagation of scrapie in peripheral nerves after footpad infection in normal and neurotoxin exposed hamsters. *Vet Res* 38: 127–99.
- Department for Environment Food and Rural Affairs (2005) Annex B. editor In: National scrapie plan for Great Britain. Available: <http://www.defra.gov.uk/corporate/regulatory/health/insp/insp76.pdf>. Accessed 23 April 2007.
- Schulz-Schaeffer WJ, Tschöke S, Kranefuss N, Dröse W, Hause-Reitner D, et al. (2000) The paraffin-embedded tissue blot detects PrP^{Sc} early in the incubation time in prion diseases. *Am J Pathol* 156: 51–56.
- Kascsak RJ, Rubenstein R, Merz PA, Tonna-DeMasi M, Fersko R, et al. (1987) Mouse polyclonal and monoclonal antibody to scrapie-associated fibril proteins. *J Virol* 61: 3688–3693.

