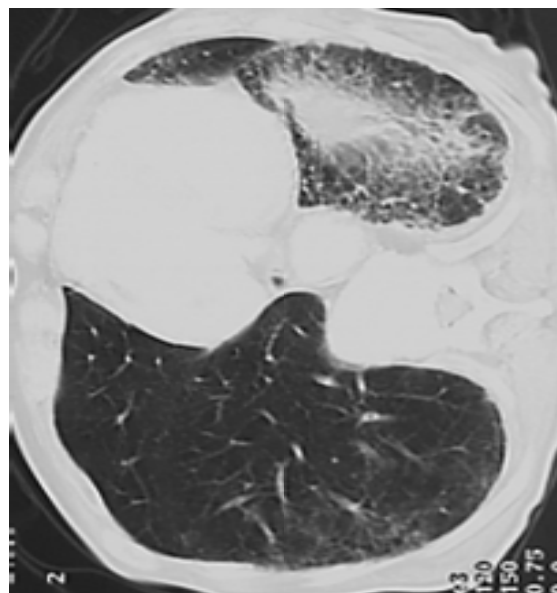
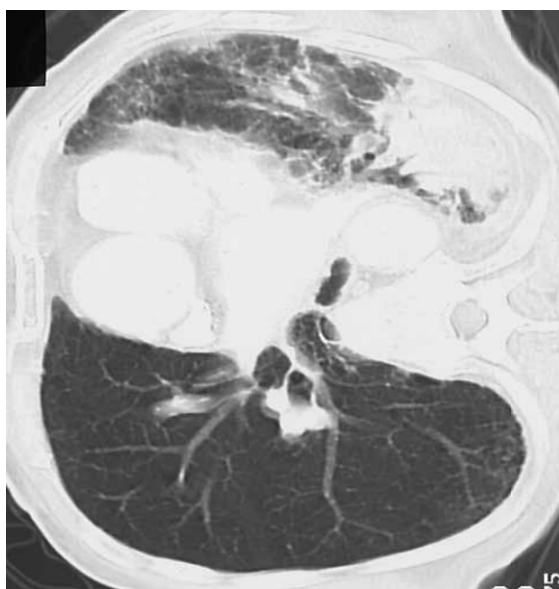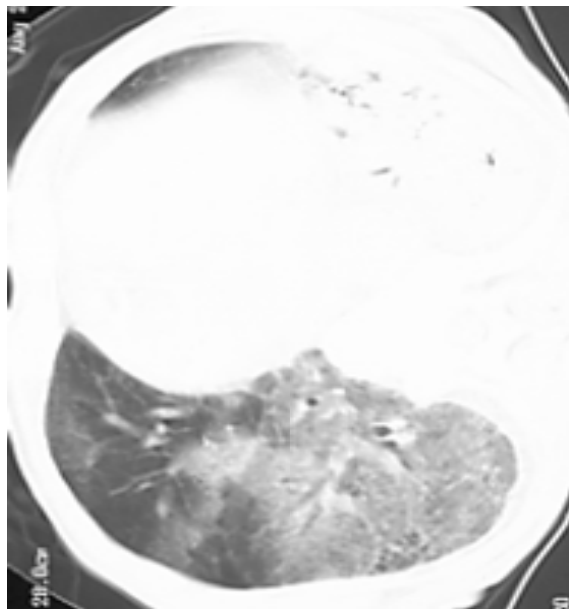
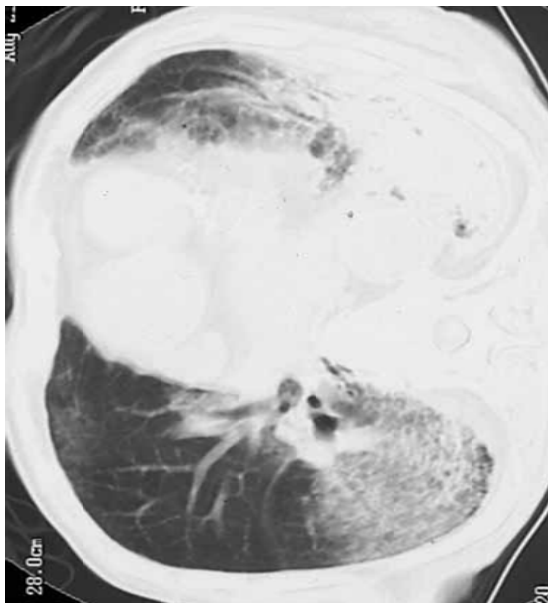


図2. 症例1の胸部CT所見



(A) ゲフィチニブ投与前



(B) ゲフィチニブ投与20日後