

舌：扁平上皮がん

(Squamous cell
carcinoma)

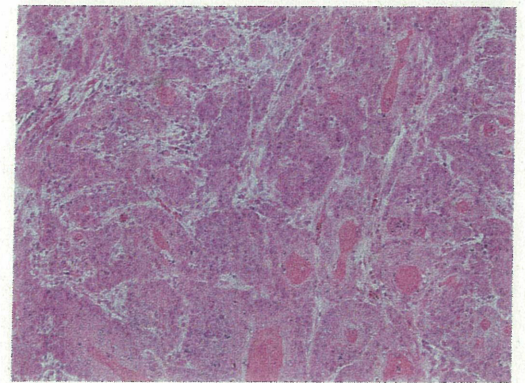
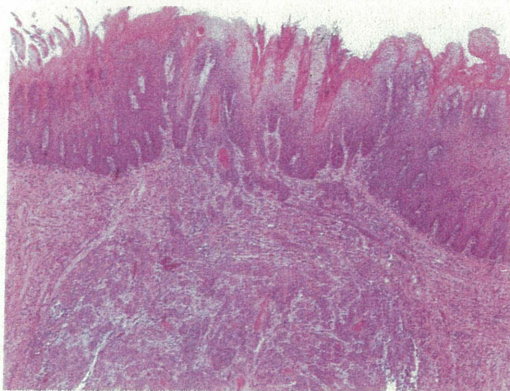
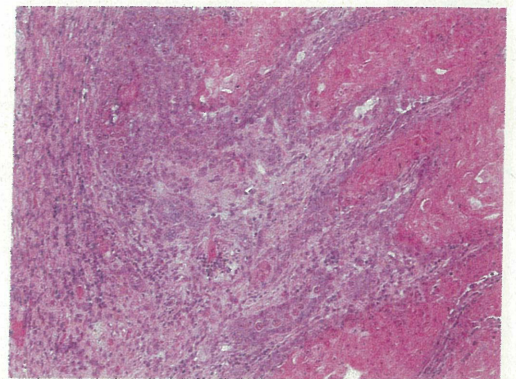
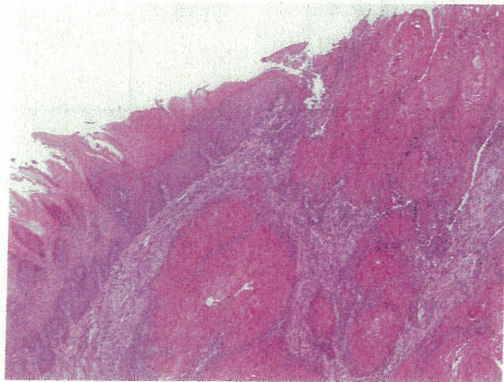


図3. 4NQO+5.5%“DAG”投与群 (Tgラット雄)