

109

B

別 冊



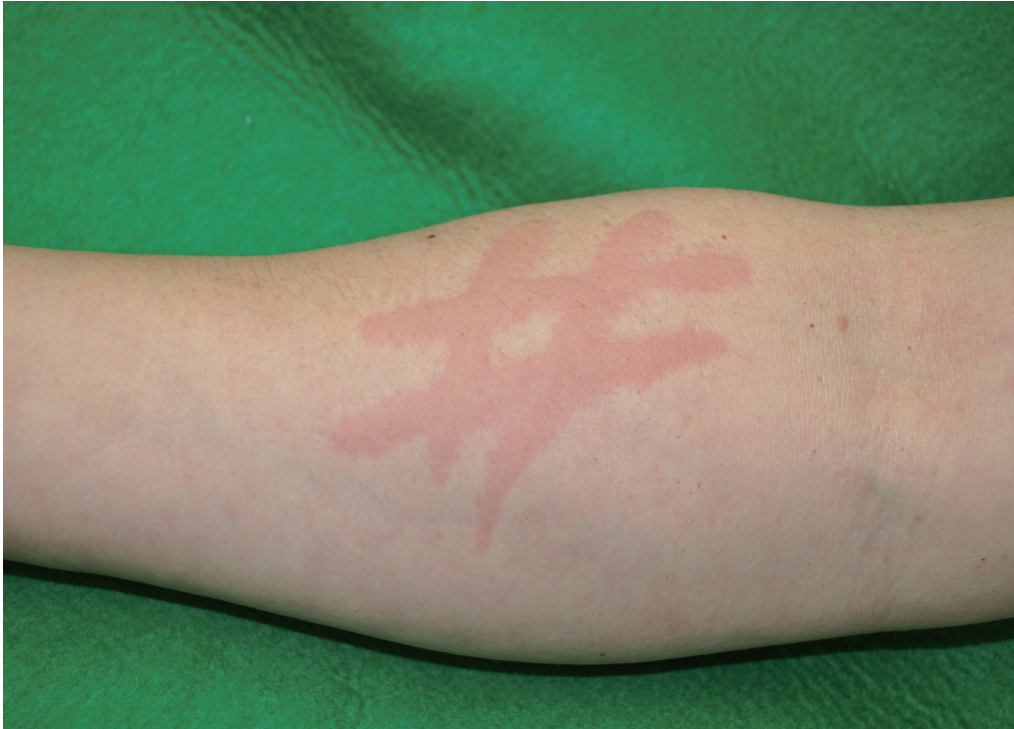





No. 1

(B 問題 23)



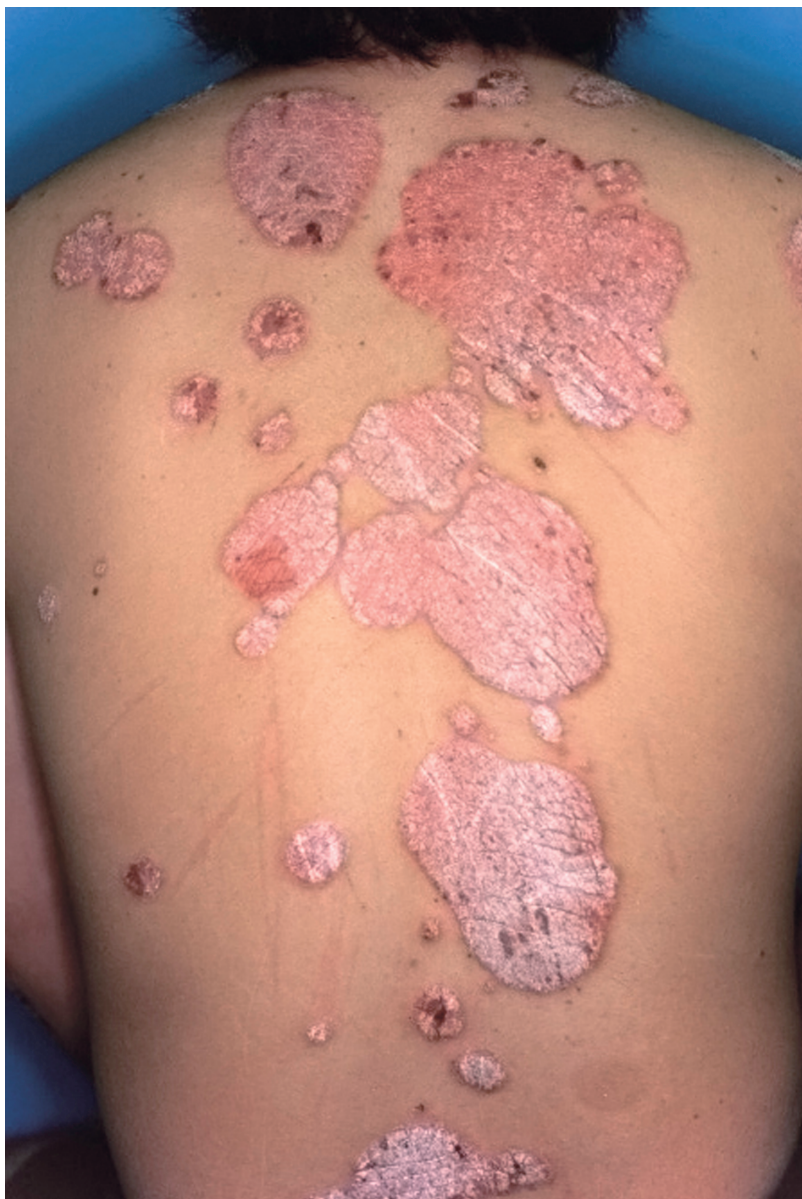
No. 2

(B 問題 24)



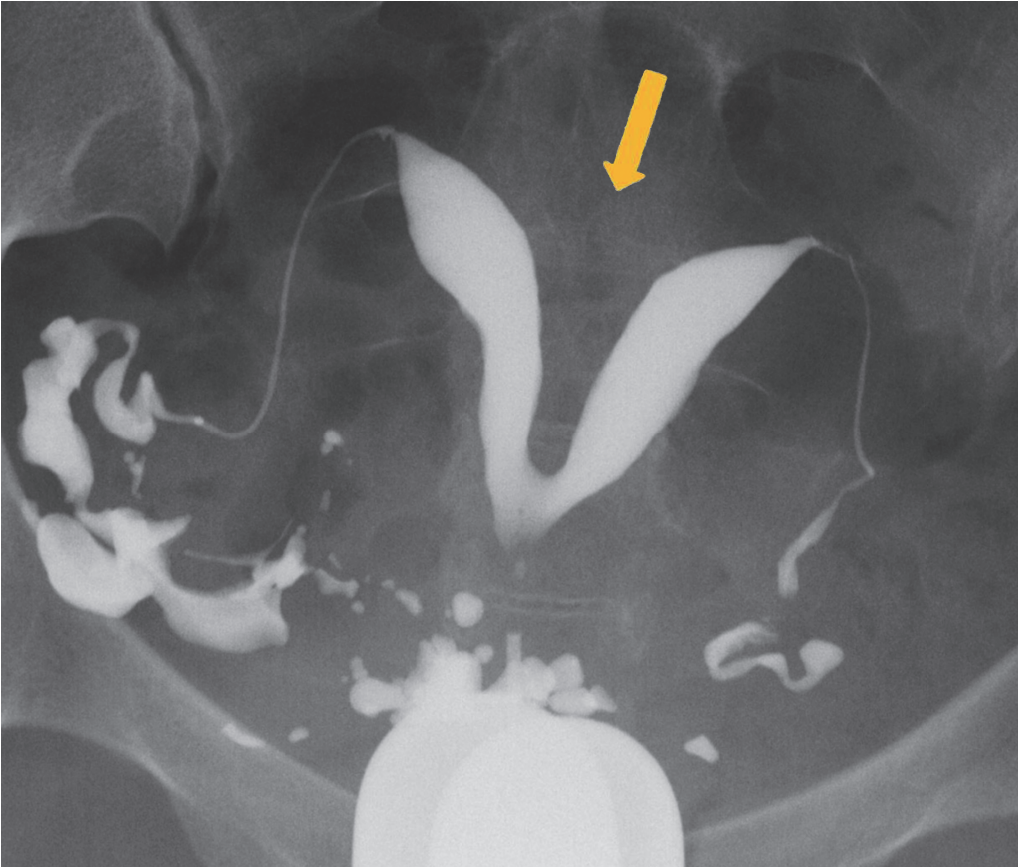
No. 3

(B 問題 45)



No. 4

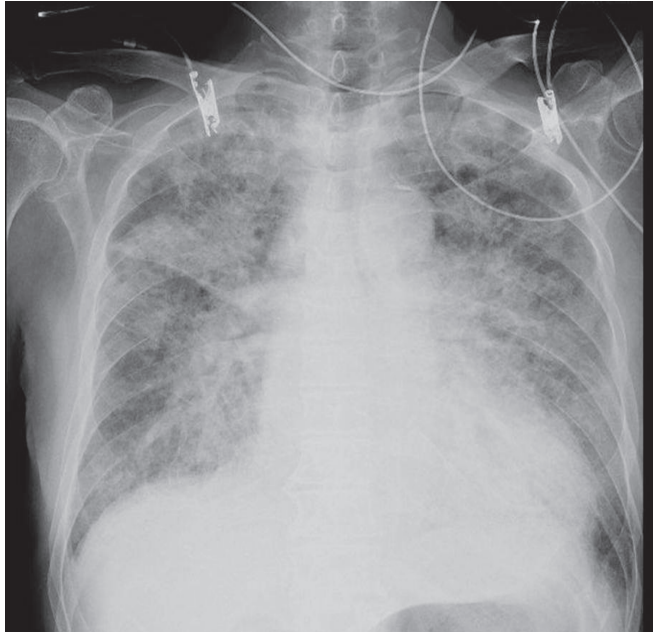
(B 問題 47)



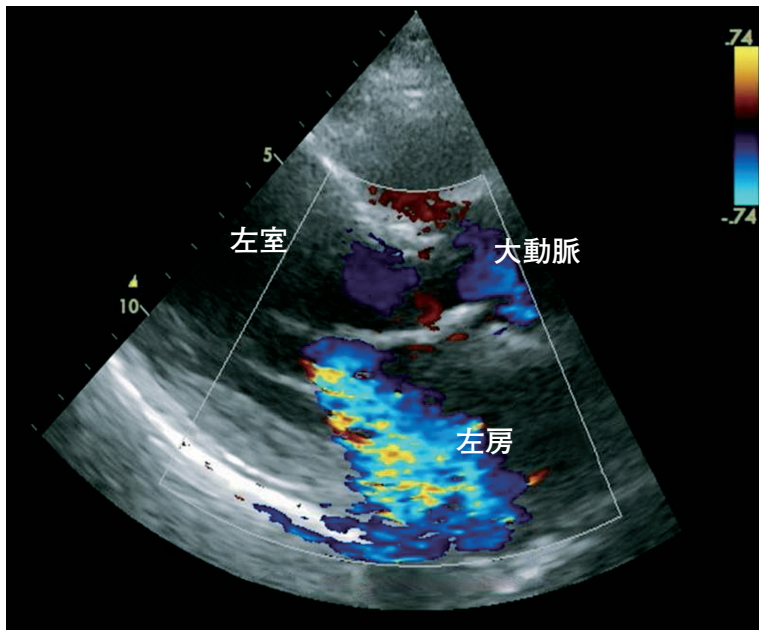
矢印は子宮の異常を示す。



No. 5 A (B 問題 48)

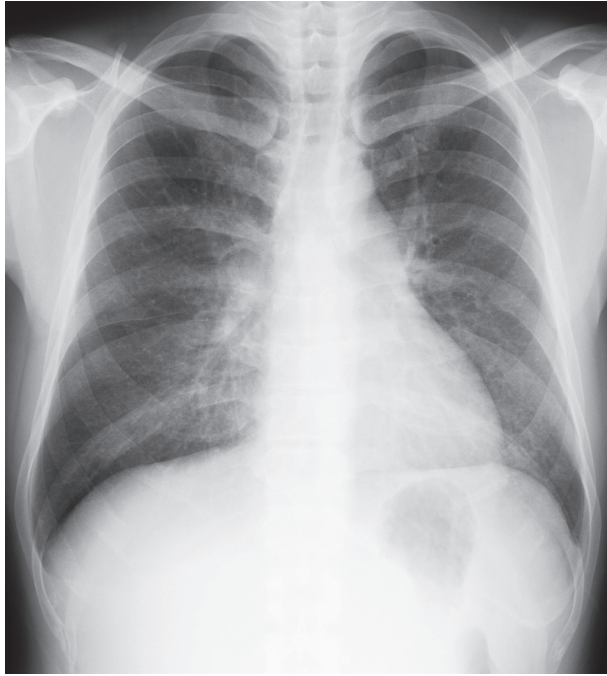


No. 5 B (B 問題 48)

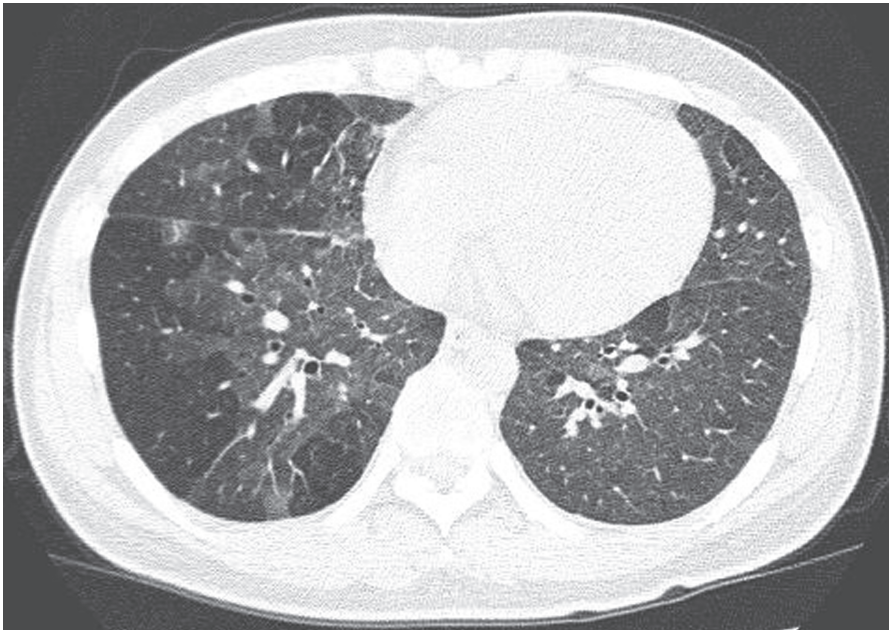


収縮期

No. 6 A (B 問題 50~52)

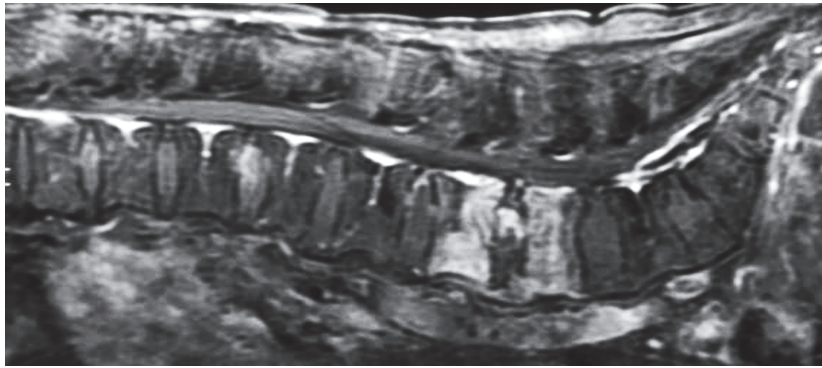


No. 6 B (B 問題 50~52)



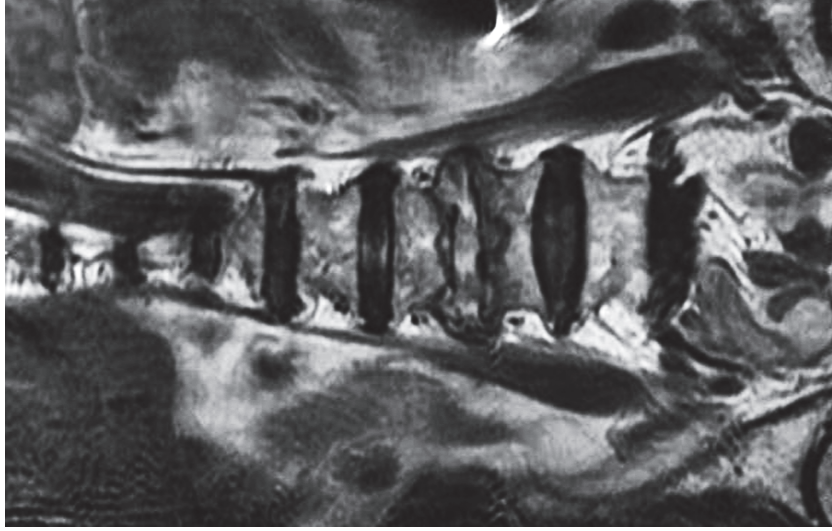


No. 7 A  
(B 問題 53~55)



脂肪抑制造影 T1 強調矢状断像

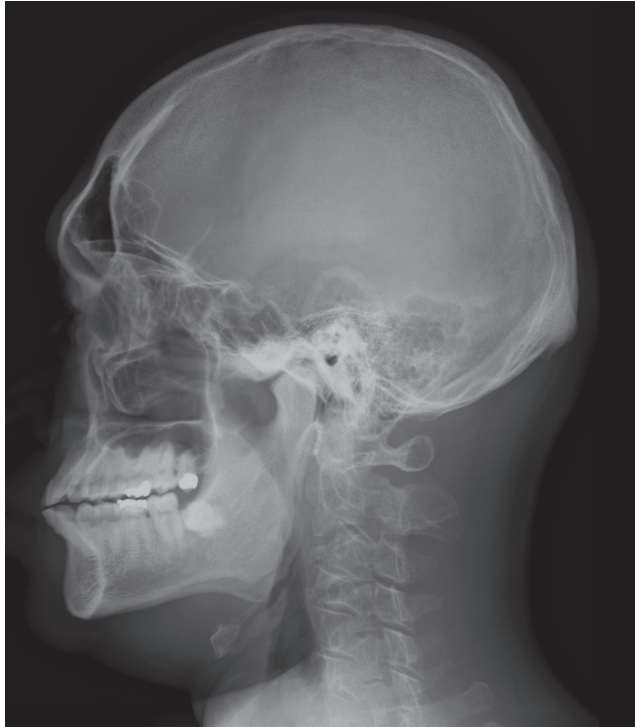No. 7 B  
(B 問題 53~55)



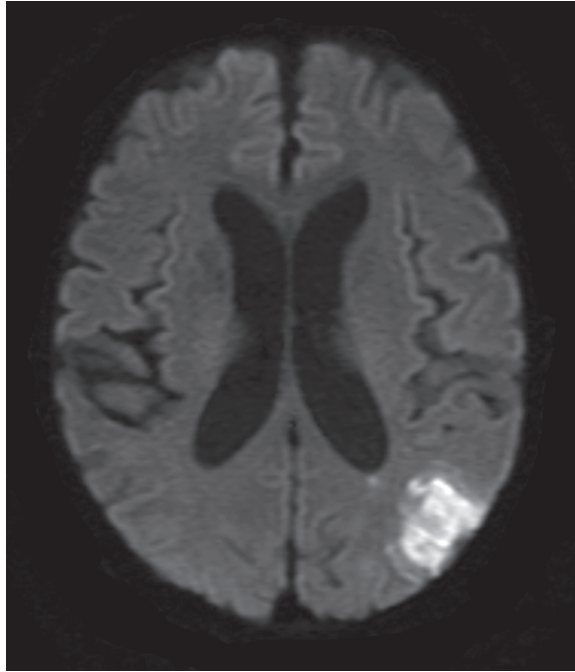
T2 強調冠状断像

No. 8

(B 問題 56~58)



No. 9 A (B 問題 59~61)



No. 9 B (B 問題 59~61)

