

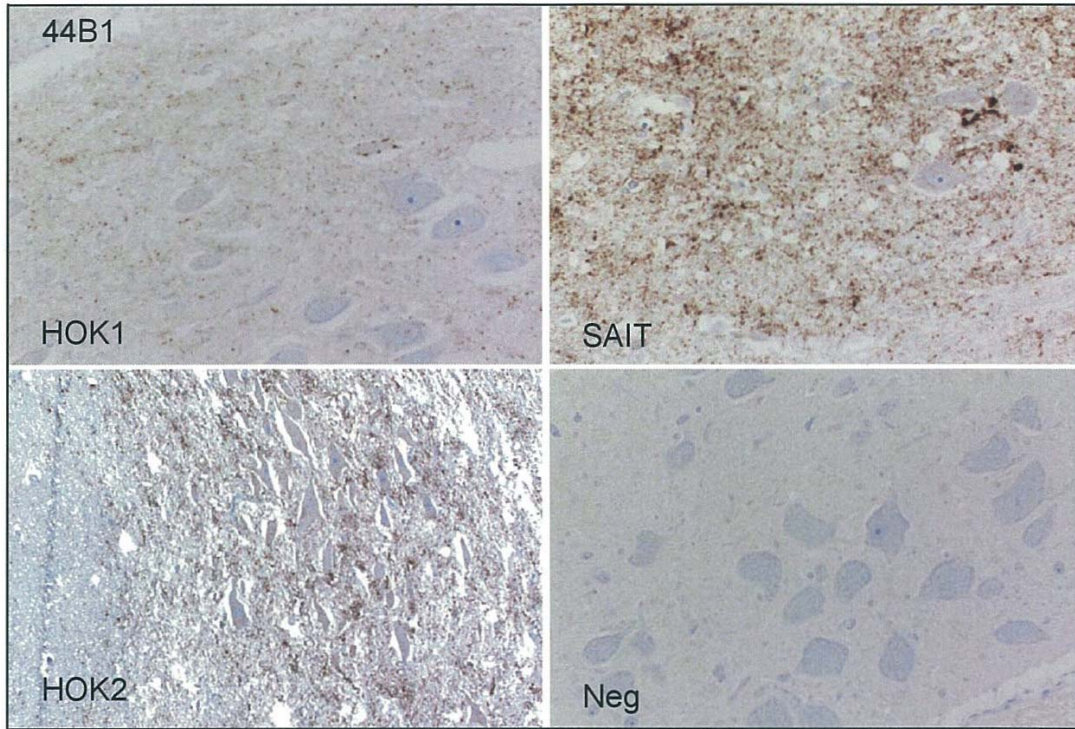Figure 7. IHC staining image using 44B1

HOK2 represents the positive image using rabbit anti-PrP polyclonal antibody (T4). SAIT includes spongiform change.

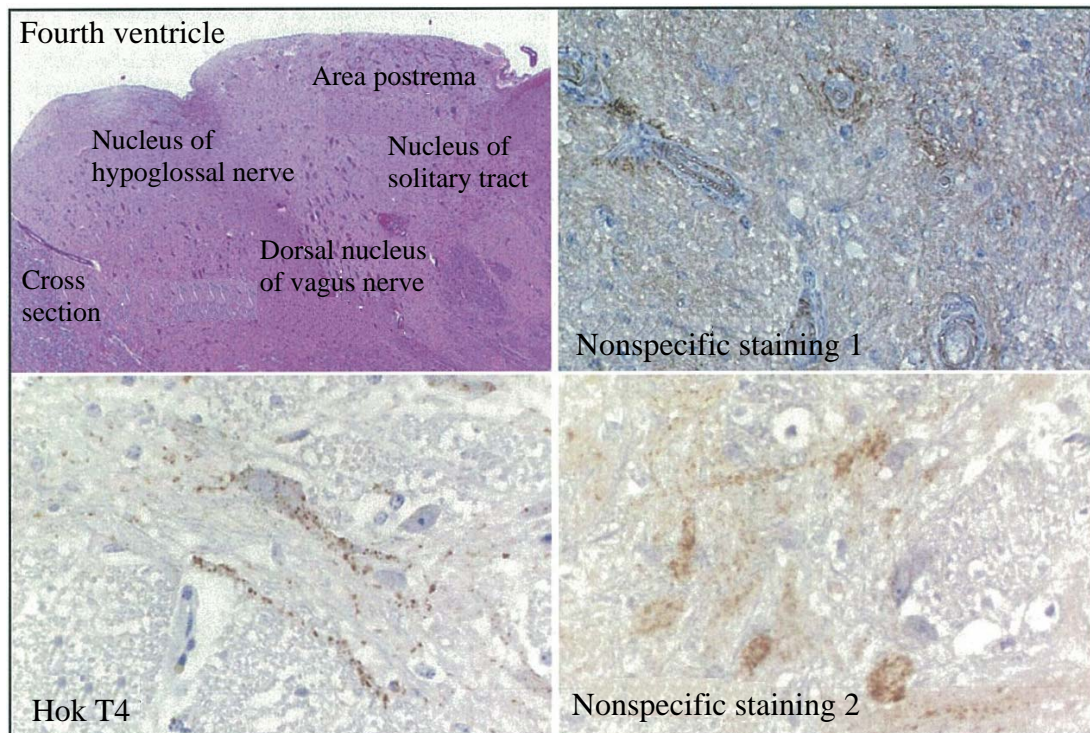


Figure 8.

The area postrema appears in the cross section of A. In this region, nonspecific staining is sometimes observed surrounding the small blood vessels when using a polyclonal antibody (T4 or B103). In addition, on occasion, findings such as the Nonspecific staining 2 are obtained. The stained findings of Nonspecific staining 2 are clearly dissimilar from the positive findings of Hok T4. There have been no incidences of such nonspecific staining up to present using the 44B1 monoclonal antibody.